

CASE REPORT/CASO CLINICO

Regenerative endodontic treatment options for immature permanent teeth: a case report with 21-month follow-up

Alternative terapeutiche per denti permanenti immaturi nel campo della rigenerazione endodontica: descrizione di un caso clinico con controlli fino a 21 mesi

KEYWORDS

Regenerative Endodontics, Incisor, Calcium Hydroxide

PAROLE CHIAVE

Endodonzia Rigenerativa, Incisivo, Idrossido di Calcio

Mariana Carvalho Furtado Leite³

Claudio Maniglia Fereira¹

Fabio de Almeida Gomes^{1,2*}

Fernanda Geraldo Pappen²

Tamara Kerber Tedesco³

Ana Flávia Bissoto Calvo³

José Carlos Pettrossi Imparato³

¹Department of Endodontics, University of Fortaleza, CE, Brazil

²Department of Endodontics, Federal University of Pelotas, RS, Brazil

³Department of Paediatric Dentistry, Faculty Sao Leopoldo Mandic, Brazil

Received 2020, January 30

Accepted 2020, March 16

Abstract

A treatment option for necrotic teeth with incompletely formed roots is apexification with calcium hydroxide, which induces the formation of a hard tissue barrier at the apex, however, in the long term, this medicament may increase the brittleness of dentin walls because of its hygroscopic and proteolytic properties, in addition to the disadvantage of requiring multiple appointments. An alternative to this is the mineral trioxide aggregate (MTA) artificial barrier technique, that unfortunately share with the previous one the disadvantage of preventing the complete root maturation. A new possible treatment for young permanent teeth with necrotic pulps is pulp regeneration, whose advantage lies in the stimulation of new tissue formation within the root canal. Pulp revascularization is based on the disinfection of the root canal system, often performed with irrigating solutions and intracanal medicaments, accompanied by induction of periapical bleeding and formation of a blood clot that will fill the root canal.

The aim of this study was to present a case of avulsion of teeth 11 and 21, both with open apices, treated with replantation associated with regenerative endodontic therapy, but varying the intracanal medicaments used: calcium hydroxide in tooth 11 and double antibiotic paste in tooth 21. Pulp revascularization proved to be effective with both intracanal medicaments used, promoting symptom resolution and complete root development, including apical closure, even in the absence of a well-defined clinical.

Una opzione per il trattamento dei denti necrotici con radici non formate completamente è la apacificazione con l'idrossido di calcio, la quale induce la formazione di una barriera di tessuto duro a livello apicale, tuttavia, nel lungo termine, questa medicazione può aumentare la fragilità delle pareti dentinali per via delle sue proprietà igroscopiche e proteolitiche, inoltre questa tecnica ha lo svantaggio di richiedere molteplici sedute. Un'alternativa è la tecnica della barriera artificiale con l'utilizzo del Mineral Trioxide Aggregate (MTA) che, sfortunatamente, condivide con la tecnica precedente lo svantaggio di impedire il completo sviluppo radicolare. Una nuova possibilità di cura per i denti permanenti immaturi con la polpa necrotica è la rigenerazione, il cui vantaggio giace nella stimolazione della formazione di nuovo tessuto dentro al canale radicolare. La rivascularizzazione della polpa si basa nella disinfezione del sistema canale radicolare, spesso eseguita con l'utilizzo di soluzioni irriganti e medicazioni intracanalari, accompagnata dall'induzione del sanguinamento peri-apicale e la formazione di un coagulo sanguigno che andrà a riempire il canale radicolare.

Lo scopo di questo studio è stato quello di presentare il caso di un paziente con i denti 1.1 e 2.1 immaturi con apici aperti, avulsi, trattati con il reimpianto e associato a terapie rigenerative endodontiche, variando le medicazioni intracanalari utilizzate: idrossido di calcio sul dente 1.1 e una pasta bi-antibiotica (DAP) sul dente 2.1. La rivascularizzazione della polpa si è provata efficiente utilizzando le due medicazioni, promovendo la risoluzione dei sintomi e il completamento dello sviluppo radicolare, includendo la chiusura apicale, anche in assenza di un protocollo clinico ben stabilito.

Corresponding author

Address requests for reprints to Fabio de Almeida Gomes | Rua Paula Ney 925,ap 501, Aldeota, zip code 60140-200, Fortaleza, CE | Brazil fabiogomes@unifor.br

Peer review under responsibility of Società Italiana di Endodonzia

10.32067/GIE.2020.34.01.05

Società Italiana di Endodonzia. Production and hosting by Ariesdue. This is an open access article under the CC BY-NC-ND license (<http://creativecommons.org/licenses/by-nc-nd/4.0/>).

Introduction

Endodontic therapy for immature permanent teeth with necrotic pulps is a major challenge in dentistry. With pulp necrosis, the dentin walls of the root canal remain thin and susceptible to fracture, thus limiting biomechanical preparation (1, 2).

The treatment of choice for necrotic teeth with incompletely formed roots is apexification with calcium hydroxide, which induces the formation of a hard tissue barrier at the apex (3). However, in the long term, this medicament may increase the brittleness of dentin walls because of its hygroscopic and proteolytic properties, in addition to the disadvantage of requiring multiple appointments (4). An endodontic treatment alternative for necrotic teeth with open apices is the creation of an artificial root-end barrier with mineral trioxide aggregate (MTA) (5). This technique has the advantage of reducing the number of treatment appointments. Nevertheless, both methods (apexification with calcium hydroxide and artificial apical barrier technique with MTA) have the disadvantage of not allowing the continuation of root development (6, 7).

A treatment option for young permanent teeth with necrotic pulps is pulp regeneration, whose major advantage lies in the stimulation of new tissue formation within the root canal (8). Pulp revascularization is based on the disinfection of the root canal system, often performed with irrigating solutions and intracanal medicaments, accompanied by induction of periapical bleeding and formation of a blood clot that will fill the root canal. Undifferentiated cells originating from the apical papillae, associated with growth factors, will then initiate the formation of new tissue within the root canal.

Controlling intracanal infection is crucial to the success of regenerative endodontic procedures (9, 10). In conventional endodontic therapy, the reduction of bacterial loads along with adequate root canal sealing with filling material are often sufficient to control infection. The absence of substrate

to maintain the viability and proliferation of these microorganisms ultimately determines their death. However, in regenerative endodontic procedures, the apex is not sealed, since communication of the root canal with periapical tissues is an essential source of nutrition for the newly formed tissue. Conversely, this condition may also provide an access for bacterial substrate, negatively interfering with the success of the therapy (11,12). Therefore, creating and maintaining an aseptic environment is essential to allow the establishment of the new tissue in the root canal space.

In view of the foregoing, it is necessary to determine a strict disinfection protocol before a pulp regeneration approach. In the protocol for regenerative endodontic procedures proposed by the American Association of Endodontists (13), the placement of antibiotic or calcium hydroxide pastes as intracanal medicaments for 1 to 4 weeks is recommended for disinfection of the canal space.

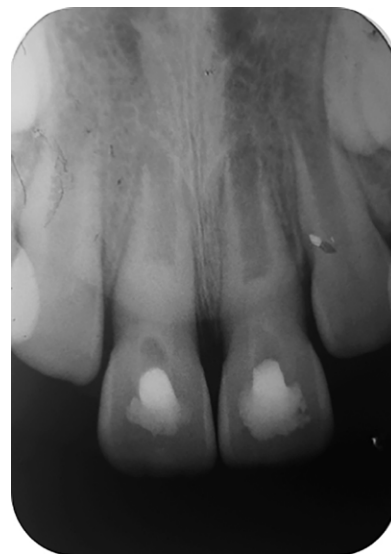
Calcium hydroxide paste is widely used in endodontics to disinfect the root canal system and to induce periapical tissue repair (14). As an alternative to this medicament, antibiotic pastes have also been used to control infection in endodontic therapy. The combination of antibiotics increases the spectrum of action of the medicament, potentially improving the level of canal disinfection. For this purpose, the triple antibiotic paste (TAP) (15), composed of ciprofloxacin, metronidazole, and minocycline, was proposed for use as an antimicrobial agent in endodontic therapy (16). However, depending on the concentration of the components, this medicament may have cytotoxic effects (17). In addition, several studies have reported color changes in the crown after the use of TAP, attributable to one of the components of the mixture, minocycline, a derivative of tetracycline (17, 18, 19) that is known to induce tooth staining. In this context, alternative medicaments to TAP have been studied, such as the double antibiotic paste (DAP) (20), which is composed of only ciprofloxacin and metronidazole.

The aim of this study was to present a case

Figure 1
Initial periapical radiographic exam.

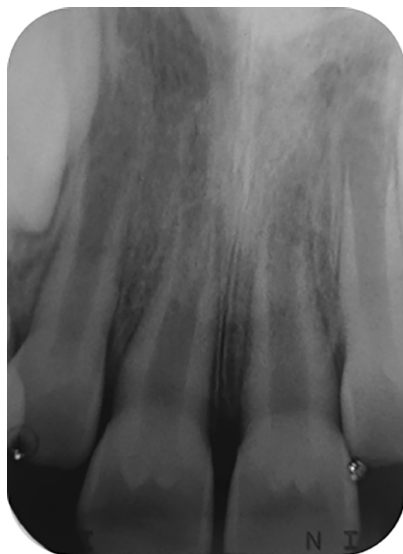

Figure 2
Radiographic exam with intracanal medicament.



of avulsion of teeth #11 and #21, both with open apices, treated with replantation associated with regenerative endodontic therapy, varying the intracanal medicaments used.

Case report

This study was approved by the Research Ethics Committee of São Leopoldo Mandic School of Dentistry, Brazil (approval number 3.404.274).

An 8-year-old girl was brought by her mother to the emergency department of Universidade de Fortaleza (UNIFOR) complaining that teeth #11 and #21 were sen-

sitive to palpation and percussion and of a dark discoloration in one of them; both were buccally inclined. The patient had experienced a traumatic injury as a result of falling from a bicycle 30 days prior, with avulsion of teeth #11 and #21, which were replanted about 10 minutes after the accident by a dental surgeon at the local primary care unit. The mother's patient related that a flexible splint was used in both teeth for 14 days. Initial radiographic examination revealed that the 2 affected maxillary incisors had incompletely formed roots, with apical opening greater than 3 mm, leading to the indication of regenerative endodontic procedures in an

Figure 3
Final periapical radiograph exam.

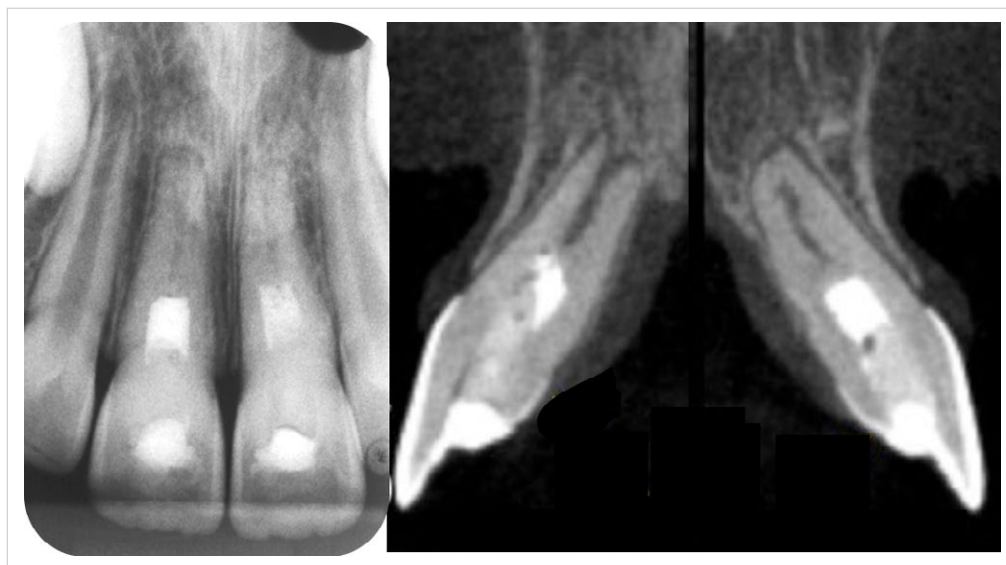
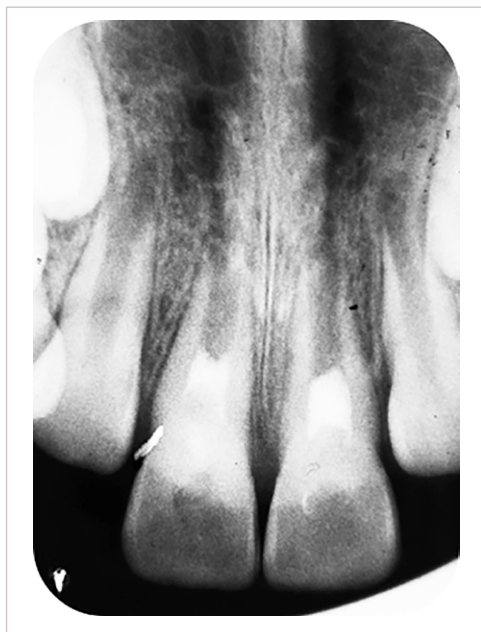


Figure 4
14-month follow-up showing that apical closure of tooth #21 and that the apex of tooth #11 was still open.



attempt to induce the continuation of root development (figure 1).

At the first appointment, the root canals of both teeth were emptied and cleaned. Access cavities were prepared, and the root canals were irrigated with saline solution and debrided with a #100 K-file (Dentsply, Rio de Janeiro, Brazil). A solution of 2.5% sodium hypochlorite (Biodinâmica, Ibiporã, Brazil) was carefully dripped to avoid leakage to the periapical region, since root apices were open. The canals were flushed with EDTA (Biodinâmica, Ibiporã, Brazil) for 3 minutes to remove the smear layer, followed by final irrigation with saline solution. As an intracanal medicament, a calcium hydroxide paste (Biodinâmica, Ibiporã, Brazil) associated with 2% chlorhexidine gel (Bi-

odinâmica, Ibiporã, Brazil) was used in tooth #11, and DAP consisting of metronidazole and ciprofloxacin was used in tooth #21 (figure 2).

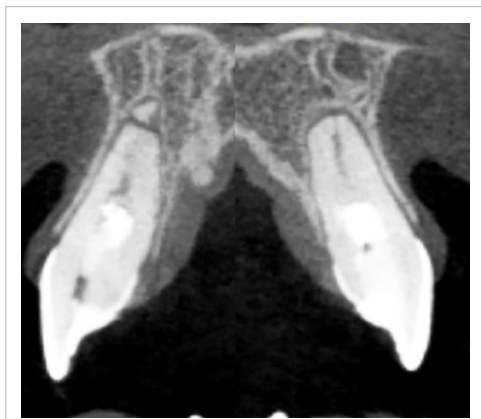The patient returned 20 days later. At this appointment, the paste was removed, and bleeding was induced into the canal space of both teeth by irritating the apical tissues with a #100 K-file until a blood clot was achieved. A sterile collagen sponge (Hemospon; Maquira, Maringá, Brazil) was used to promote hemostasis, also providing a basis for the placement and stabilization of MTA (Angelus, Londrina, Brazil) performed afterwards. The teeth were then restored with resin-modified glass ionomer cement (Vitremmer; 3M, São Paulo, Brazil), and a final periapical radiograph was taken (figure 3). A 14-month follow-up radiograph suggested root development in both teeth. Tomographic image showed that apical closure of tooth #21 began to take place and that the apex of tooth #11 was still open (figure 4). A second tomographic image, 21 months after the trauma, showed the 2 incisors with completely formed roots and complete apical closure (figure 5).

Discussion

Regenerative endodontic therapy aims to biologically direct the growth of injured structures or even repair damaged tissues of the dentin-pulp complex, forming viable structures that, preferably, originate from similar primary tissues (21). Despite the high success rates of this therapy described in the literature, no consensus has been reached on a clinical protocol, particularly regarding irrigating solutions and intracanal medicaments (22). Maniglia-Ferreira et al. (23) concluded that, despite the lack of an established treatment protocol, it is extremely important to combine effective disinfection with the use of a series of pastes to create an environment conducive to pulp revascularization and root formation.

Decontamination of the root canal system is a critical step for further pulp regeneration. However, in immature permanent teeth, the mechanical removal of microorganisms is limited due to the thin dentin wall; therefore, it seems more prudent to promote root canal

Figure 5
21-month follow-up showing completely formed roots and complete apical closure.





cleaning by using copious irrigation and intracanal medicament (8).

Sodium hypochlorite and chlorhexidine digluconate are the chemical substances most commonly used as irrigants in regenerative therapy. Both have good antimicrobial potential, but chlorhexidine, different from sodium hypochlorite, is ineffective in dissolving organic debris (24). In the case reported here, sodium hypochlorite was used with great caution by slowly dripping to prevent leakage of the solution into the periapex, since root apices were open. Subsequently, EDTA irrigation was used to remove the smear layer, followed by final irrigation with saline solution to neutralize the environment. According to Reynolds et al. (25) and Shin et al. (26), the use of saline solution as a final irrigant is of utmost importance to reduce cytotoxicity for stem cells. Galler et al. (27) stated that the success of regenerative therapy is dependent on the use of chelating agents, such as EDTA. Trevino et al. (28) confirmed that EDTA contributes to the survival of apical stem cells. Regarding intracanal medicament, a calcium hydroxide P.A. paste associated with 2% chlorhexidine gel was used in tooth #11(24,29), while DAP consisting of metronidazole and ciprofloxacin was used in tooth #21 following a similar protocol employed by Maniglia-Ferreira et al. (2017) (23) in a similar case of an avulsed immature permanent tooth with necrotic pulp.

Dhillon et al. (30) recommended that the patient should return 30 days after the first appointment for induction of apical bleeding so that blood would fill the root canal up to the cemento-enamel junction. After hemostasis, the blood clot formed in the region provided a basis for the placement of MTA. Ding et al. (31) added that MTA cervical barrier was necessary to prevent microorganisms from entering the canal. In the case reported here, the patient returned 20 days after the first appointment because she lived in another city. At this appointment, periapical bleeding was induced, followed by clot formation and MTA placement. Formation of a clot along with necrotic pulp tissue act as a scaffold for the ingrowth of new tissue, in which undifferentiated cells originating from the apical papillae and plate-

let-derived growth factors will direct cell differentiation (32). Souza Filho et al. (33) stated that, when in contact with the dentin wall, undifferentiated mesenchymal cells synthesize and secrete a cementoid tissue, promoting space closure and strengthening the root canal structure.

In cases of regenerative therapy, follow-up is essential to achieve successful clinical results. Chen et al. (34) suggested a minimum follow-up of 6 months. Chueh et al. (35) reported that, within a period of 10 to 13 months, complete root development was achieved in immature permanent teeth with necrotic pulps. In the case reported here, the patient was followed up at 14 months and at 21 months. In the last follow-up visit, completion of root development was observed, including apical closure of both teeth, in addition to resolution of symptoms and a positive response to pulp vitality test.

Conclusion

Based on what has been reported here, in cases of necrotic immature permanent teeth treated with regenerative endodontic procedures, pulp revascularization proved to be effective with both intracanal medicaments used, promoting symptom resolution and the completion of root development, including apical closure, even in the absence of a well-defined clinical protocol.

Clinical Relevance

This case report shows two regenerative endodontic therapy in the same patient with two different intracanal medicaments used.

Conflict of Interest

The authors deny any conflicts of interest related to this study.

Acknowledgements

Special thanks to the University of Fortaleza and the Federal University of Pelotas for their continued support.

References

1. Hachmeister DR, Schindler W, Walker WA, Thomas DD. The sealing ability and retention characteristics of mineral trioxide aggregate in a model of apexification. *Journal of Endodontics*. 2002. 28(5):386-390.
2. Pace R, Giuliani V, Pini Prato L, Bacetti T, Pagavino G. Apical plug technique using mineral trioxide aggregate: results from a case series. *Int Endod J*. 2007. 40(6):478-484.
3. Rafter M. Apexification: a review. 2005 *Dental Traumatol*. 21(1):1-8.
4. Andreasen J, Farik B, Munksgaards E. Long term calcium hydroxide as a root canal dressing may increase risk of root fracture. *Dental Traumatol*. 2002. 18(3):134-137.
5. Wintherspoon D, Small J, Regan J, Numn M. Retrospective analysis of open apex teeth obturated with mineral trioxide aggregate. *Journal of Endodontics*. 2008. 34(10):1171-1176.
6. Norsat A, Seifi A, Asgary, S. Regenerative endodontic treatment (revascularization) for necrotic immature permanent molars: a review and report of two cases with a new biomaterial. *Journal of Endodontics*. 2011. 37(4):562-567.
7. Prirokh M, Torabinejad M. Mineral trioxide aggregate: a comprehensive literature review - Part III: Clinical applications, drawbacks, and mechanism of action. *Journal of Endodontics*. 2010. 36(3):400-13.
8. Lovelace TW, Henry MA, Hargreaves KM, Diogenes A. Evaluation of the delivery of mesenchymal stem cells into the root canal space of necrotic immature teeth after clinical regenerative endodontic procedure. *J Endod*. 2011. 37(2):133-8.
9. Fouad AF. The microbial challenge to pulp regeneration. *Advances in Dental Research*, v. 23, n. 3, p. 285-289, July 2011.
10. Verma P et al. Effect of Residual Bacteria on the Outcome of Pulp Regeneration In Vivo. *Journal of Dental Research*. 2017, v. 96, n. 1, p. 100-106.
11. Jacobs, JC et al. Antibacterial Effects of Antimicrobials Used in Regenerative Endodontics against Biofilm Bacteria Obtained from Mature and Immature Teeth with Necrotic Pulp. *Journal of Endodontics*. 2017, v. 43, n. 4, p. 575-579.
12. Law AS. Consideration for Regenerative Procedures. *Journal of Endodontics*. 2016, v. 39, n. 3, p. 44-56.
13. Bystrom A, Claesson R, Sundqvist G. The antibacterial effect of camphorated paramonochlorophenol, camphorated phenol and calcium hydroxide in the treatment of infected root canals. *Endodontics & Dental Traumatology*. 1985, v. 1. n. 5, p. 170-175.
14. Kantaoutra PN. BCOR mutations and unstoppable root growth: a commentary on oculofaciocardiodental syndrome: novel BCOR mutations and expression in dental cells. *Journal of Human Genetics*. 2014, v. 59, n. 6, p. 297-299.
15. Hoshino E. et al. In-vitro antibacterial susceptibility of bacteria taken from infected root dentine to a mixture of ciprofloxacin, metronidazole and minocycline. *International Endodontic Journal*. 1996, 29, n. 2, p. 125-130.
16. Ruparel NB. et al. Direct effect of intracanal medicaments on survival of stem cells of the apical papilla. *Journal of Endodontics*. 2012, v. 38, n. 10, p. 1372-1375.
17. Kim JH et al. Tooth discoloration of immature permanent incisor associated with triple antibiotic therapy: a case report. *Journal of Endodontics*. 2010, v. 36, n. 6, p. 1086-1091.
18. Petrino JA et al. Challenges in regenerative endodontics: a case series. *Journal of Endodontics*. 2010, v. 36, n. 3, p. 536-541.
19. Dabbagh B. et al. Clinical complications in the revascularization of immature necrotic permanent teeth. *Pediatric Dentistry*. 2012, v. 34, n. 5, p. 414-417.
20. Grottkau BE, Purudappa PP, Lin YF. Multilineage differentiation of dental pulp stem cells from green fluorescent protein transgenic mice. *International Journal of Oral Science*. 2010, v. 2, n. 1, p. 21-27.
21. Jung LY, Lee SJ, Hargreaves KM. Biologically base treatment of immature teeth with pulpal necrosis: a case series. *Journal of Endodontics*. 2008. 34(7):876-887.
22. Alcade MP, Guimaraes BM, Fernandes SL, Silva PAA, Bramante CM, Vivian RR. et al. Revascularização pulpar: considerações técnicas e implicações clínicas. *Salusvita*. 2014. 33(3):415-432.
23. Maniglia-Ferreira C, Gomes FA, Vitoriano MM. Intentional Replantation of an Avulsed Immature Permanent Incisor: A Case Report. *Journal of Endodontics*. 2017. 43(8):1383-1386.
24. agata JY, Gomes BP, Rocha Lima TF, Murakami LS, De Farias DE, Campos GR. et al. Traumatized immature teeth treated with 2 protocols of pulp revascularization. *Journal of Endodontics*. 2014. 40(5):606-612.
25. Reynolds K, Johnson J, Cohenca N. Pulp revascularization of necrotic bilateral bicuspids using a modified novel technique to eliminate potential coronal discoloration: a case report. *International Endodontic Journal*. 2009. 42(1):84-92.
26. Shin SY, Albert JS, Mortan RE. One step pulp revascularization treatment of a immature permanent tooth with chronic apical abscess: a case report. *Int Endod J*. 2009. 42(12):1118-1126.
27. Galler KM, D'Souza RN, Federlin M, Cavander A., Hartgerink JD, Hecker S. Dentin conditioning codetermines cell fate in regenerative endodontics. *Journal of Endodontics*. 2011. 37(11):1536-1541.
28. Trevino EG, Patwarhand AN, Henry MA. Effect of irrigants on the survival of human stem cells of the apical papilla in a platelet-rich plasma scaffold in human roots tips. *Journal of Endodontics*. 2011. 37(8):1109-1115.
29. Soares AJ, Lins FF, Nagat JY, Gomes BPFA, Zaia AA, Ferraz CC, Almeida JFA, DE Souza-Filho FJ. Pulp revascularization after root canal decontamination with calcium hydroxide and 2% chlorhexidine gel. *J Endod* 2013;39:417-420.
30. Dhillon H, Kaushik M, Sharma R. Regenerative endodontics - Creating new horizons. *J Biomed Mater Res B Appl Biomater*. 2016. 104(4):676-685.
31. Ding R, Cheung J, Yin X, Wang Q, Zhang C. Pulp revascularization of immature teeth with apical periodontitis: a clinical study. *Journal of Endodontics*. 2009. 35(5):745-749.
32. Bansal R. Regenerative endodontics: a state of the art. *Indian J Dent Res*. 2011. 22(1):122-131.
33. Souza-Filho FJ. Tratamento dos dentes com rizogênese incompleta: revitalização ou apicificação. *Endodontia passo a passo: evidências clínicas*. São Paulo Artes Médicas; 2015, p.166-175.
34. Chen MY, Chen KL, Chen CA, Tayebaty F, Rosenberg PA, Lin LM. Responses of immature permanent teeth with infected necrotic pulp tissue and apical periodontitis/abscess to revascularization procedures. *Int Endod J*. 2012. 45(3):294-305.
35. Chueh LH, Ho YC, Kuo TC, Lai WH, Chen YH, Chiang CP. Regenerative endodontic treatment for necrotic immature permanent teeth. *Journal of Endodontics*. 2009. 35(2):160-16.