

## CASE REPORT

# Management of an unusual foreign body in periapical tissues of immature permanent maxillary central incisor

## ABSTRACT

**Aim:** The present report describes a clinical case of apical surgery with a 3-year clinical and radiographic follow-up in an immature permanent maxillary central incisor with persistent apical periodontitis caused by a foreign body in the periapical tissues.

**Summary:** The traumatic injuries of immature permanent teeth may have harmful influence on physiological pulp and root development. Root canal treatment of an immature tooth is a significant challenge because of the size of the canal, the thin and fragile dentin walls, and the large open apex. Even though endodontic failure is usually associated with the persistence of bacteria within the root canal system another less common cause of endodontic failure is the presence of a foreign body in the periapical tissues.

### Key Learning Points

- Foreign object in the periapical tissues act as a source of pain and infection, cause difficulty in elimination of infection.
- Surgical endodontic treatment should be seen as the best choice for treating persistent apical periodontitis.
- This treatment can manage the infection source and provide a direct hermetic seal of the apical area.

Fábio de Almeida Gomes<sup>1\*</sup>  
Samantha Rodrigues Xavier<sup>2</sup>  
Cláudio Maniglia Ferreira<sup>1</sup>  
Fernanda Geraldo Pappen<sup>2</sup>

<sup>1</sup>Department of Endodontics, University of Fortaleza, CE, Brazil

<sup>2</sup>Federal University of Pelotas, Pelotas, RS, Brazil

Received 2020, February 24

Accepted 2020, June 21

**KEYWORDS** apical surgery, endodontics, foreign body, immature permanent tooth, persistent apical periodontitis

### Corresponding author

Fábio de Almeida Gomes | Rua Paula Ney 925/501, Aldeota, Fortaleza, Ceara | Brazil  
Email: [fabiogomes@unifor.br](mailto:fabiogomes@unifor.br)

Peer review under responsibility of Società Italiana di Endodonzia

[10.32067/GIE.2020.34.02.02](https://doi.org/10.32067/GIE.2020.34.02.02)

Società Italiana di Endodonzia. Production and hosting by Ariesdue. This is an open access article under the CC BY-NC-ND license (<http://creativecommons.org/licenses/by-nc-nd/4.0/>).

## Introduction

The traumatic injuries of immature permanent teeth may have harmful influence on physiological pulp and root development. Such injuries may lead to the loss of pulp vitality, arrested or interrupted root development, and inflammatory or replacement root resorption (1). Root canal treatment, at this time, stands a significant challenge, due to the large diameter of the root canal, in combination with large open apex and thin dentin walls (2). Consequently, the instrumentation of root canal in order to achieve chemomechanical debridement cannot be performed in such conditions, due to fragile root canal structure.

Apexification had been the most indicated procedure to treat necrotic immature permanent teeth. Through this technique, a calcified apical barrier is formed, allowing subsequent conventional root canal filling<sup>1</sup>. Although  $\text{Ca}(\text{OH})_2$  high antimicrobial activity, and ability to induce hard-tissue deposition (3), the traditional  $\text{Ca}(\text{OH})_2$  apexification presents disadvantages, such as a long, up to 24 months treatment, in which the patient needs to attend multiple sessions. Besides, the alkalinity of  $\text{Ca}(\text{OH})_2$  affects the links between hydroxyapatite crystals and collagen, weakening the flexural strength of dentine (4) which increases the risk of root fracture (5).

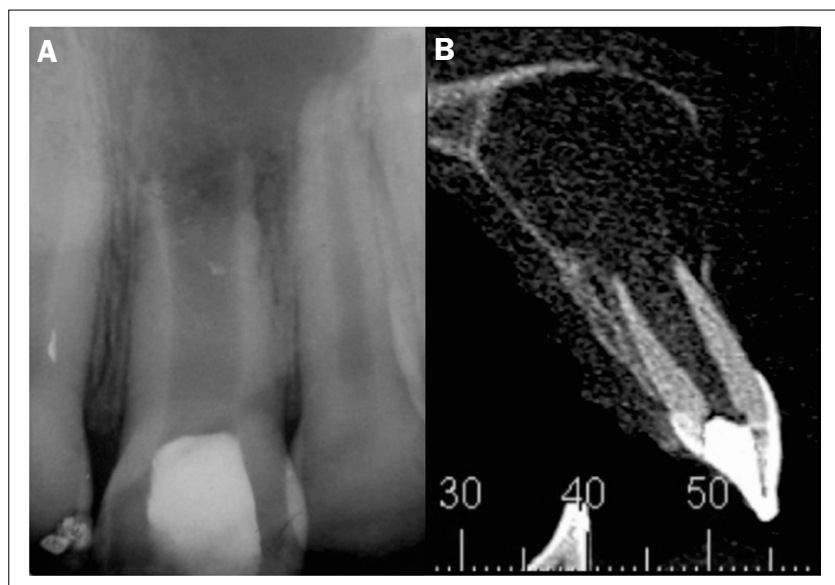
The mineral trioxide aggregate (MTA) apical plug offered an improvement in terms of timing (6) with similar apical barrier formation rates in comparison to calcium hydroxide apexification. The clinical procedures for the MTA apical plug technique comprise a first session in which  $\text{Ca}(\text{OH})_2$  paste is placed for at least one week into the root canal; and in the second appointment, MTA is condensed into the apical part of the canal until a 3-4 mm plug is formed. To promote the setting of the material, a moist cotton pellet is applied into the root canal, the tooth is temporarily sealed, and after 72 h, a gutta-percha and sealer obturation can be performed (7).

Since both, calcium hydroxide and MTA apexification and the presents the limitations of an interrupted root development, leaving the tooth with a fragile root structure and a poor crown-to-root ratio (8-12), the regenerative endodontic procedures (REP) have been advocated as an alternative treatment for immature permanent teeth with necrotic pulp (13). This method induces further root development and eventually strengthening of the tooth (14), however much is still not known about clinical and biological aspects of regenerative endodontics (15). However, case selection is of extreme importance as choosing a patient that does not correctly apply for this procedure may result in an unsuccessful outcome.

Even though endodontic failure is usually associated with the persistence of bacteria within the root canal system (16) another less common cause of endodontic failure is the presence of a foreign body in the periapical tissues. The apical periodontium can encapsulate a foreign object. And an intense inflammatory response characterized by abundance of macrophages and giant cells and a subsequent foreign body reaction can also be observed (17). In these cases, surgical endodontic treatment can be the treatment of choice for persistent apical periodontitis because it can manage the infection source and provide a hermetic seal of the apical area directly (18). The results for outcomes of apical root resection presented in the literature mostly rely on a time span of 1 or 2 years, and some even up to 5 years (19, 20). This case report describes surgical endodontic treatment in an immature permanent maxillary central incisor with persistent apical periodontitis caused by a foreign body in the periapical tissues.

## Case report

A 15-year-old boy with frequent pain, discomfort and swelling was referred to the dental clinic due to persistent apical periodontitis. The dental history reported that when the patient was 10 years old, he suffered a trauma of lateral luxation



**Figure 1.**

**A)** Radiographic image at initial diagnosis. Maxillary left central incisor with open apex associated with chronic apical periodontitis.

**B)** Computed tomography showing extensive bone resorption associated with the maxillary left central incisor.

of immature maxillary left central incisor, which led to tooth necrosis.

At that time, the treatment of choice was conventional apexification, with calcium hydroxide multiple-visit. This approach, however, was unsuccessful, since there was a constant drainage through the root canal, which did not allow the Endodontic treatment. It was also reported that during agudization events, an incision and drainage was necessary to decompress the periapical tissue with the installation of a drain. The radiographic examination revealed a wide root canal with open apex, associated with chronic apical periodontitis (Figure 1A).

Taking into consideration the persisting apical periodontitis, an apical surgery was suggested as the treatment of choice. The planned treatment was discussed with the patient and their parents and an informed consent was signed by them. A cone beam tomographic examination of the region was performed for the surgery planning (Figure 1B). Following local anesthesia with 2% lidocaine with 1:80000 epinephrine, a full mucoperiosteal flap was raised. The internal surface of the flap was found impregnated with small pieces of rubber, suggesting that a rubber dam was used as a drain during the period of acute apical abscess (Figure 2A). These rubber remnants were removed by the use of surgical curettes.

With the flap folded, the lesion was completely removed. With the defect bone cleaned and the flap folded, the root canal was submitted to antiseptics with 2% chlorhexidine and saline solution, dried with paper points and filled with white MTA (Ângelus, Londrina, Paraná, Brasil) (Figure 2B). The flap was readapted and the palatine suture was performed to maintain the flap position and minimize gingival retraction.

The patient was first recalled 7 days after the surgical procedure. Clinical assessments indicated no sensitivity to palpation and percussion, and the absence of clinical signs. The 3-year follow-up revealed no signs or symptoms, with radiographic evidence of periapical bone healing (Figure 3) and healthy periodontal tissue.

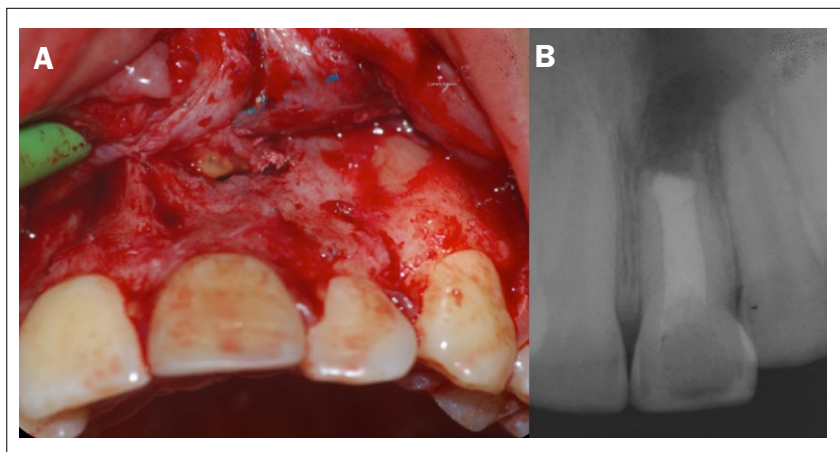
## Discussion

Although the primary etiological factor of periapical lesions is microbial, there are other independent factors that can adversely affect the outcome of endodontic treatment (21).

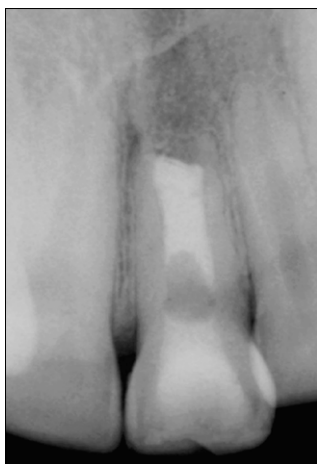In this case report, we present morphological evidence in support of the role of a foreign body reaction of periapical tissue to rubber dam used as a drain during drainage of an acute endodontic infection.

Various foreign objects have been reported to be lodged in the pulp chamber and root canal of teeth (22, 23). However, there are few case reports of foreign bodies in the periapical tissues, persisting the lack of direct scientific evidence for non-microbial causes of persistent apical periodontitis (24, 25). As well as reported in another clinical report, according to the dental history of the patient, the rubber dam fragment may have been left iatrogenically inside the periapical tissue. Running sutures should be placed to prevent impaction of rubber drains in the tissue (24).

Remaining foreign bodies in periapical tissue have been reported to act as a focus of infection (26) and have been associated with Endodontic failure. Consequent-



**Figure 2.**  
**A)** The internal surface of the flap was impregnated with small pieces of rubber.  
**B)** Final Radiographic image.



**Figure 3.**  
 Radiographic image at the 3-year follow-up, showing the complete healing of apical periodontitis.

ly, even it is not a common event, in persistent root canal infections, the existence of a foreign body should be suspected. The apical periodontal tissues can encapsulate a foreign object and an intense inflammatory response characterized by the abundance of macrophages and giant cells and a subsequent foreign body reaction can be developed (18). Furthermore, if a patient has a record of emergency assistance, with incision and drainage procedures, the risk of drain displacement in the periapical tissue due to improper suturing must be strongly considered. Being aware of this possibility aids in avoiding the erroneous diagnosis of periapical granulomas and repeated changes of intracanal medication (24). In this clinical report, after numerous dental appointments, in which conventional apexification was considerate, the apical surgery was assumed to be the treatment of choice, due to persistent infection and acute events. Apical surgery is a procedure aimed at diagnosing and treating endodontic lesions (apical periodontitis) that are not responsive of or do not improve with conventional endodontic procedures (27). Success rates for endodontic microsurgery have been reported to be between 88.9% and 100% (28), and these high levels of healing corroborated with the successful treatment reported in this article. Apical surgery has advanced to become a modern technique which has good results with regard to treatment of endodontic lesions with predictable healing patterns (29).

After the removal of the foreign object from the periapical tissues of the tooth presenting an open apex, the closure of the apex is of paramount consideration. In this report, MTA was used for retrograde filling material. In reason that Mineral trioxide aggregate (MTA), provides good clinical and histological results, which makes it the retrograde filling material of choice, largely due to its physical/chemical/biological properties (2, 30). Histologic analysis of periapical regions showed deposition of new cementum, not only onto the resection plane (cut dentinal surface) but also directly onto MTA (30). Furthermore, a 10-year follow-up study of teeth treated with apical surgery and MTA as root-end filling material showed an acceptable rate of healed cases (27).

This case presents a successful outcome of surgical endodontic treatment with immediate MTA barrier in an immature tooth with persistent apical periodontitis caused by a foreign body in the periapical tissues. This clinical report helps to avoid erroneous diagnosis and unsuccessful repeated changes in intracanal medication.

## Conclusions

Even with all the attempts of endodontic treatment, in this clinical case it was not possible to reduce the clinical signs of persistent infection. Thus, surgical endodontic treatment was the treatment of choice, which permitted the periapical healing of an immature tooth with persistent apical periodontitis caused by a foreign body in the periapical tissues.

## Clinical Relevance

This case report describes surgical endodontic treatment in an immature permanent maxillary central incisor with persistent apical periodontitis caused by a foreign body in the periapical tissues.

## Conflict of Interest

The authors have no conflict of interest to declare.



## Acknowledgements

The authors would like to thank the patient and their parentes to consent this article to be written.

## References

- Hecova H, Tzigkounakis V, Merglova V, Netolicky J. A retrospective study of 889 injured permanent teeth. *Dent Traumatol* 2010; 26: 466-75.
- Chala S, Abouqal R, Rida S. Apexification of immature teeth with calcium hydroxide or mineral trioxide aggregate: systematic review and meta-analysis. *Oral Surg Oral Med Oral Pathol Oral Radiol Endod* 2011; 112: e36-42.
- Mohammadi Z, Dummer PM. Properties and applications of calcium hydroxide in endodontics and dental traumatology. *Int Endod J* 2011; 44: 697-730.
- Andreasen JO, Farik B, Munksgaard EC. Long-term calcium hydroxide as a root canal dressing may increase risk of root fracture. *Dent Traumatol* 2002; 18: 134-7.
- Cvek M. Prognosis of luxated non-vital maxillary incisors treated with calcium hydroxide and filled with gutta-percha. A retrospective clinical study. *Endod Dent Traumatol* 1992; 8: 45-55.
- Witherspoon DE, Ham K. One-visit apexification: technique for inducing root-end barrier formation in apical closures. *Pract Proced Aesthet Dent* 2001; 13:455-60.
- Torabinejad M, Chivian N. Clinical applications of mineral trioxide aggregate. *J Endod* 1999; 25: 197-205.
- Katebzadeh N, Dalton BC, Trope M. Strengthening immature teeth during and after apexification. *J Endod* 1998; 24: 256-9.
- Jeeruphan T, Jantararat J, Yanpiset K, Suwannapan L, Khewsawai P, Hargreaves KM. Mahidol study 1: comparison of radiographic and survival outcomes of immature teeth treated with either regenerative endodontic or apexification methods: a retrospective study. *J Endod* 2012; 38: 1330-6.
- Wigler R, Kaufman AY, Lin S, Steinbock N, Hazan-Molina H, Torneck CD. Revascularization: a treatment for permanent teeth with necrotic pulp and incomplete root development. *J Endod* 2013; 39: 319-26.
- Kahler B, Rossi-Fedele G, Chugal N, Lin LM. An Evidence-based Review of the Efficacy of Treatment Approaches for Immature Permanent Teeth with Pulp Necrosis. *J Endod* 2017; 43: 1052-7.
- He L, Kim SG, Gong Q et al. Regenerative Endodontics for Adult Patients. *J Endod* 2017; 43: S57-S64.
- Silujjai J, Linsuwanont P. Treatment Outcomes of Apexification or Revascularization in Nonvital Immature Permanent Teeth: A Retrospective Study. *J Endod* 2017; 43: 238-45.
- Hargreaves KM, Diogenes A, Teixeira FB. Treatment options: biological basis of regenerative endodontic procedures. *J Endod* 2013; 39: S30-43.
- Kim SG, Malek M, Sigurdsson A, Lin LM, Kahler B. Regenerative endodontics: a comprehensive review. *Int Endod J* 2018; 51: 1367-88.
- Nair PN, Henry S, Cano V, Vera J. Microbial status of apical root canal system of human mandibular first molars with primary apical periodontitis after "one-visit" endodontic treatment. *Oral Surg Oral Med Oral Pathol Oral Radiol Endod* 2005; 99: 231-52.
- Nair PN. On the causes of persistent apical periodontitis: a review. *Int Endod J* 2006; 39: 249-81.
- Tsesis I, Shoshani Y, Givol N, Yahalom R, Fuss Z, Taicher S. Comparison of quality of life after surgical endodontic treatment using two techniques: a prospective study. *Oral Surg Oral Med Oral Pathol Oral Radiol Endod* 2005; 99: 367-71.
- Gagliani MM, Gorni FG, Strohmer L. Periapical resurgery versus periapical surgery: a 5-year longitudinal comparison. *Int Endod J* 2005; 38: 320-7.
- Wang H, Li D, Tian Y, Yu Q. [A retrospective study of 180 cases of apical microsurgery]. *Zhonghua Kou Qiang Yi Xue Za Zhi* 2014; 49: 421-7.
- Nair PN, Sjogren U, Krey G, Sundqvist G. Therapy-resistant foreign body giant cell granuloma at the periapex of a root-filled human tooth. *J Endod* 1990; 16: 589-95.
- Chand K, Joesph S, Varughese JM, Nair MG, Prasanth S. Endodontic management of an unusual foreign body in a maxillary central incisor. *J Conserv Dent* 2013; 16: 474-6.
- Ramugade MM, Sapkale KD, Metkari SS. Patient induced unusual metallic obturation of the root canal of permanent maxillary central incisor with an immature apex - A rare case report. *Singapore Dent J* 2014; 35: 77-82.
- Kim HJ, Min KS. Cystic lesion caused by latex material. *Quintessence Int* 2019; 50: 316-8.
- Plascencia H, Cruz A, Solis R, Diaz M, Vazquez J. Iatrogenic displacement of a foreign body into the periapical tissues. *Case Rep Dent* 2014; 2014: 698538.
- Costa F, Robiony M, Toro C, Sembronio S, Politi M. Endoscopically assisted procedure for removal of a foreign body from the maxillary sinus and contemporary endodontic surgical treatment of the tooth. *Head Face Med* 2006; 2: 37.
- von Arx T, Jensen SS, Hanni S, Friedman S. Five-year longitudinal assessment of the prognosis of apical microsurgery. *J Endod* 2012; 38: 570-9.
- Setzer FC, Shah SB, Kohli MR, Karabucak B, Kim S. Outcome of endodontic surgery: a meta-analysis of the literature—part 1: Comparison of traditional root-end surgery and endodontic microsurgery. *J Endod* 2010; 36: 1757-65.
- Serrano-Gimenez M, Sanchez-Torres A, Gay-Escoda C. Prognostic factors on periapical surgery: A systematic review. *Med Oral Patol Oral Cir Bucal* 2015; 20: e715-22.
- Katsamakis S, Slot DE, Van der Sluis LW, Van der Weijden F. Histological responses of the periodontium to MTA: a systematic review. *J Clin Periodontol* 2013; 40: 334-44.