

ORIGINAL ARTICLE

# Micro-computed tomography evaluation of filling material removal by three reciprocating systems with different thermal treatments

## ABSTRACT

**Aim:** This study compared the efficacy of three reciprocating systems with different heat treatments in removing obturator material from lower molar mesial canals.

**Methodology:** The mesial canals of 18 lower molars were instrumented with ProTaper Next 25/0.06 and filled with gutta-percha and AHPlus. The teeth were randomly divided into three groups ( $n=6$ ) according to the system used to remove the filling material: Reciproc (REC R25), Reciproc Blue (RECB R25) and Wave One Primary (WO). The desobturation was considered complete when the working length was reached, and remnants of obturator material were no longer found in the instrument and also in the canal walls, observed through the dental operating microscope.

**Results:** The results were analyzed using Biostat 4.0 software. Shapiro-Wilk and ANOVA (Tukey) tests with a significance level of 5% were applied. The volume of obturator material decreased in the cervical and middle thirds after the use of REC, RECB and WO systems ( $P<.01$ ), but there was no significant difference between the three systems ( $P>.05$ ). In the apical third, there was no significant reduction in the remaining obturator material independent of the operating system ( $P>.05$ ).

**Conclusions:** REC, RECB and WO systems showed similarity in the removal of obturator material and were inefficient specifically in the apical third, showing the limitation of these systems in removing obturation material from curved canals.

Ana Grasiela Limoeiro<sup>1\*</sup>  
Antônio Henrique Braitt<sup>1</sup>  
Alessandra Silveira Machado<sup>2</sup>  
Carlos Eduardo Bueno<sup>3</sup>  
Carlos Eduardo Fontana<sup>4</sup>  
Laila Gonzales Freire<sup>5</sup>  
Ricardo Tadeu Lopes<sup>2</sup>  
Alexandre Sigrist De Martin<sup>3</sup>

<sup>1</sup>Department of Endodontics, Ilhéus School of Dentistry, BA, Brazil

<sup>2</sup>Nuclear Engineering Program, Federal University of Rio de Janeiro, Rio de Janeiro, RJ, Brazil

<sup>3</sup>Department of Endodontics, Faculty São Leopoldo Mandic, Instituto de Pesquisas São Leopoldo Mandic, Campinas, SP, Brazil

<sup>4</sup>Department of Endodontics, Pontifícia Católica University, Campinas, SP, Brazil

<sup>5</sup>Department of Restorative Dentistry, São Paulo University, SP, Brazil

Received, 2020 July 12

Accepted 2020, December 25

**KEYWORDS** endodontic retreatment, heat treatment, micro-CT

### Corresponding author

Ana Grasiela Limoeiro | Department of Endodontics, Ilhéus School of Dentistry, BA | Brazil  
Tel: +55 7398874195 | Email: [grasielalimoeiro@gmail.com](mailto:grasielalimoeiro@gmail.com)

Peer review under responsibility of Società Italiana di Endodonzia

[10.32067/GIE.2021.35.01.07](https://doi.org/10.32067/GIE.2021.35.01.07)

Società Italiana di Endodonzia. Production and hosting by Ariesdue. This is an open access article under the CC BY-NC-ND license (<http://creativecommons.org/licenses/by-nc-nd/4.0/>).

## Introduction

Although endodontic treatment has high success rates (1, 2), failures can occur, requiring reintervention. The percentage of success and survival of root canal treatment over 2-10 years ranged between 86% and 93% (3). Conventional retreatment is the first option for the removal of the filling material (4).

Some rotary Ni-Ti systems, such as Mtwo Retreatment (VDW, Munich, Germany) and ProTaper Retreatment (Dentsply Maillefer, Ballaigues, Switzerland) have been developed for the retreatment of root canals. Although Reciproc (WDW, Munich, Germany), Reciproc Blue (Munich, Germany) and WaveOne (Dentsply Maillefer, Ballaigues, Switzerland) reciprocating instruments have not been designed for root canal retreatment, studies have demonstrated their efficacy for the removal of the filling material (5-7).

The REC and RECB reciprocating systems are S-shaped cross-sections, the first with M-Wire alloy and the second with blue-Wire alloy. The WO system has a triangular cross-section and an M-Wire alloy. Researches performed on rotary and/or reciprocating instruments for retreatment has shown that these are not effective for the removal of gutta-percha from the canal system, especially in the apical region (8-10). Therefore, it is important to study whether blue heat-treated systems can effectively remove all the obturator materials from the root canals.

This study aimed to evaluate the volume of filling material remaining in mesial root canals of human lower molars after the use of Reciproc (REC), Reciproc Blue (RECB), and WaveOne (WO) reciprocating systems. The null hypothesis was that the type of instruments, with different thermal treatments of the alloy, would not interfere with the remaining volume of the obturator material in the mesial canals of lower molars.

## Materials and Methods

The study protocol was approved by the Institutional Research Ethics Committee

(register No. 2.332.674) because it is a study involving biological material/humans. Eighteen first and second molars were selected and maintained in 0.1% thymol solution. The sample calculation was performed using the ANOVA test that indicated a total of 6 samples per group as the ideal size required to notice significant differences among the groups. The sample had the alpha type error of 0.05 and a test power of 80%.

Teeth with mesial roots with two canals and independent foramina, complete rhizogenesis, and angle of curvature between 20° and 40° were included in the study and measured with Image J program (National Institutes of Health, Maryland, USA) according to the method of Schneider (11).

Teeth were excluded with a previous endodontic treatment, pulp calcifications, resorptions, root fractures, and canals whose patency was not obtained after the access surgery. The teeth were washed in running water, and the root surface was cleaned by ultrasound and kept hydrated in saline until the beginning of the experiment. The size of the teeth was standardized at 18 mm by cutting the occlusal surfaces using a diamond disk (FKG Dentaire, La Chaux-de-Fonds, Switzerland).

The working length (WL) was defined by placing a size 15 K-file (Dentsply Maillefer, Ballaigues, Switzerland) inside the canal until its tip was visible at the apical foramen, subtracting 1 mm. The patency was maintained with the use of a size 10 K-file (Dentsply Maillefer), passing 1 mm beyond the WL. All treatments were performed using the dental operative microscope (Alliance, São Carlos, São Paulo) with the magnification of 8x. Each instrument was used in four canals (12) and then discarded. Irrigation was performed with 20 mL of 2.5% sodium hypochlorite (NaOCl). The smear layer was removed at the end of instrumentation with 5mL of 17% ethylenediaminetetraacetic acid (EDTA) for 3 minutes.

The canals were instrumented by a single qualified specialist in endodontics with ProTaper Next (Dentsply Maillefer) X3 files (30/.07) in the cervical and middle thirds

and X2 files (25/.06) in the apical third, with the aid of an electric motor with torque control, 300 RPM and 2 N (X-Smart, Dentsply/Maillefer).

The teeth were dried with absorbent paper and sealed by the single cone technique (X2, Dentsply Maillefer) and AHPlus sealer (Dentsply Maillefer). The sealer was placed in the cone and inserted into the canal with a single movement. The excess cone was cut with Touch'n Heat thermo-compactor (SybronEndo, Orange, CA), and then vertical cold condensation was performed. Crowns were sealed with temporary Coltosol cement (Coltene, Whaledent, Cuyahoga Falls, OH) and stored at 100% humidity at 37° C for 30 days (13). The teeth were radiographed mesiodistally and buccolingually to evaluate the quality of the obturation, which was confirmed by the micro-CT examinations. All of the root canal fillings were adequate without presence of underfilling or overfilling. The teeth were divided into 3 groups (n=6): REC R25, RECB R25, and WO Primary.

#### Removal of obturator material

The removal of the filling material was accomplished using an endodontic motor (VDW Silver; VDW GmbH, Munich, Germany). Reciproc and Reciproc Blue instruments with the Reciproc ALL program and the WaveOne instruments with the Wave One ALL program. Each instrument

was used only once and discarded. The instruments were used with in-and-out movements against the walls of the canals until the WL was reached. The foraminal patency of the canals was maintained with a size 15 K-file to remove the complete obturator material. The filling removal procedure was considered complete when the WL was reached, and the remnants of the obturator material were no longer found on the instrument and the canal walls were seen through the dental operative microscope (16x). Irrigation was performed with 5 mL of 2.5% NaOCl between each file, after three in-and-out movements with a total volume of 20 mL. The final irrigation protocol was performed with 5 mL of 2.5% NaOCl, followed by 5 mL of EDTA, using a 31 G NaviTip (Ultradent, South Jordan, UT, USA).

#### Micro-CT Scans

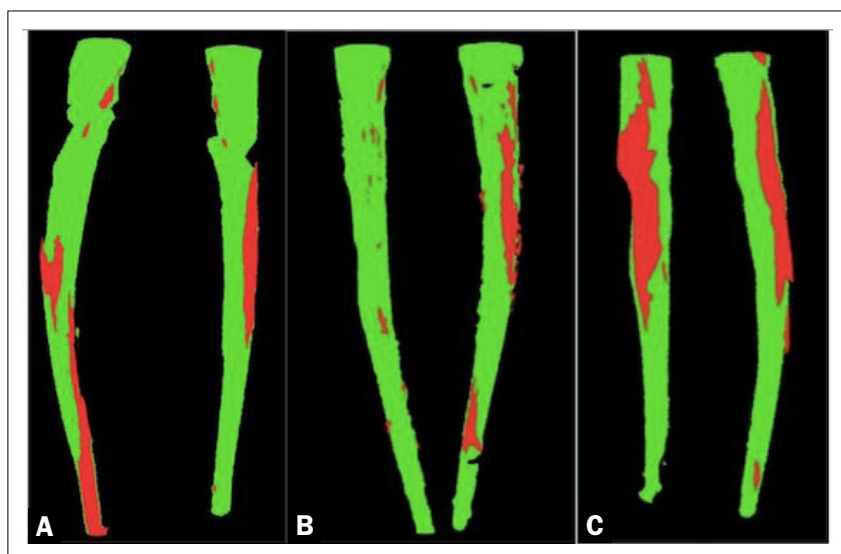
Preoperative and postoperative microtomographic examinations were performed for the non-destructive evaluation of the volume of obturator material remaining in the entire canals and also in the apical, middle, and cervical thirds. For this step, a SkyScan 1173 X-ray Microtomography (Bruker microCT; Bruker, Aartselaar, Belgium) was used.

The specimens were scanned with a power of 90 KV and 278  $\mu$ A, rotated 360° with 0.5° of rotation step, producing an image with voxel size to be defined (from 6 to 20 $\mu$ m). The filter used was 0.1 mm copper. The images were analyzed with the program CTAn v.1.15 (Bruker microCT), and the volumes of obturator material (mm<sup>3</sup>) after the obturation and the filling removal procedures were calculated. Then, the 3D models were created and visualized through the program CTVol v.2.3 software (Bruker microCT).

#### Statistical analysis

The results were analyzed using the Biostat 4.0 Program. The Shapiro-Wilk normality test was applied. The sample presented normal behavior. The ANOVA (Tukey) test was applied with a significance level of 5%.

**Figure 1**  
Superimposed pre- and post retreatment micro-CT images of a representative sample of each group. Green corresponds to the initial root canal filling and red to the filling remaining after using the reciprocating instruments. REC (**1A**) three-dimensional model of a tooth after filling and retreatment procedure with Reciproc; RECB (**1B**) three-dimensional model of a tooth after filling and retreatment procedure with Reciproc Blue; and WO (**1C**) three-dimensional model of a tooth after filling and retreatment procedure with Wave One.



## Results

None of the complications had occurred during instrumentation nor than retreatment procedure. The volume of obturator material decreased in the cervical and middle thirds after the use of WO, REC and RECB systems ( $P < .01$ ), but there was no significant difference (Figure 1) between the three systems ( $P > .05$ ). In the apical third (Table 1) there was no significant reduction in the remaining obturator material independent of the operating system ( $P > .05$ ).

## Discussion

Removal of all the obturator material from the root canal system in cases of retreatment is essential for effective action of irrigation solutions and instruments, as the remaining gutta-percha and sealer can shelter micro-organisms, which will lead to failure (14-17). This study aimed to evaluate, by micro-CT, the amount of filling material remaining in curved canals after the use of three reciprocating instruments. The null hypothesis was accepted as there were no differences between the groups in the volume of obturator material removed. It is a consensus in the literature that no technique can completely remove the obturator material from the root canal system (18-20).

The reciprocating instruments REC, RECB, and WO were developed to perform the instrumentation of the root canals, presenting similar shaping ability (21). Although the reciprocating instruments used in this study were not designed for retreatment, these have already been tested for this purpose in other studies (7, 22) with controversial results. Notably, procedural errors may occur in curved root canals (20); however, no instrument presented deformation or fracture in this study. The reciprocating systems are as efficient as the rotary in retreatment, regardless of the morphology of the canals (14).

Several methodologies, such as cleavage (5, 24), radiographs (25), and diaphanization (26), were already used to evaluate the amount of remaining obturator material; however, in this study, micro-CT was used as a 3D method, non-destructive and accurate (27).

In this study, there were no significant differences between the systems in the quantity of initial and final remaining obturator material in the apical third of the studied groups. This can be justified by the fact that the instruments used in the removal of root canal obturator material have the same tip (0.25) as the last instrument used during the preparation of the root canals. Also, moderately curved root canals

**Table 1**

Arithmetic means, standard deviations, and statistical analysis of ANOVA (Tukey) of the total volume of filling material and the remaining amount in the apical, middle, and cervical thirds after using Reciproc (REC), Reciproc Blue (RECB) and WaveOne (WO).

	Filling Material Total	Filling Material Apical	Filling Material Middle	Filling Material Cervical
WO-I	7.43 (3.09) <sup>A</sup>	1.14 (0.79) <sup>A</sup>	4.00 (1.24) <sup>A</sup>	2.29 (1.06) <sup>A</sup>
WO-F	2.15 (2.15) <sup>B</sup>	0.70 (0.68) <sup>A</sup>	0.58 (0.63) <sup>B</sup>	0.87 (0.84) <sup>B</sup>
REC-I	7.47 (1.47) <sup>A</sup>	1.03 (0.39) <sup>A</sup>	4.31 (0.82) <sup>A</sup>	2.13 (0.26) <sup>A</sup>
REC-F	1.48 (1.22) <sup>B</sup>	0.41 (0.26) <sup>A</sup>	0.61 (0.61) <sup>B</sup>	0.46 (0.35) <sup>B</sup>
RECB-I	5.95 (0.85) <sup>A</sup>	0.80 (0.25) <sup>A</sup>	3.35 (0.37) <sup>A</sup>	1.80 (0.23) <sup>A</sup>
RECB-F	0.87 (0.81) <sup>B</sup>	0.24 (0.21) <sup>A</sup>	0.37 (0.37) <sup>B</sup>	0.26 (0.23) <sup>B</sup>
(P-value)	<.01	>.05	<.01	<.01

I: initial, F: final, different uppercase letters in the vertical direction: statistically significant differences.



were used in this study. The use of more tapered instruments than the last instrument used in the preparation of the canals would be ideal for promoting more significant apical enlargement and consequently higher removal of the gutta-percha (28, 29). Furthermore, Rodig et al. (20) used the R25 file followed by R40 file (40/.06) in WL, and this may have contributed to the higher percentage of gutta-percha removal. Although Bernardes et al. (30) have shown that reciprocating systems with larger tapers are more efficient than rotary ones, the Twist File Adaptive (TFA) and PUR provided the most significant removal of filling material then REC (31). Ozyurek et al. (32) have shown that ProTaper Next and PUR rotational systems were superior to REC and TFA. Other studies (9, 14, 19, 20), found that rotary and reciprocating instruments are effective in removing the filling material, regardless of canal morphology. Comparing REC and RECB, De Deus et al. 2019 (7) found no differences; however, Bago et al. (22) have shown that REC was superior than RECB in the removal of the gutta-percha from the root canal system. RECB and K-manual files were able to remove great part of Thermafil and AH Plus fillings (33).

The single cone technique was used in this study as one of the most commonly used techniques. Higher volume of remaining sealing material was found in the canals filled by the Continuous Condensation Wave Technique than in those in which the Lateral Condensation Technique (29).

Although Cavenago et al. (34) reported that the use of xylene improved the removal of gutta-percha remnants, the solvent was not used in this study because of cytotoxicity (35) and the increase in retreatment time, without much efficacy. It can also increase the adhesion of the gutta-percha to the walls of the canals (29). Another study (6) reported the agitation of xylene with ultrasonic tips after the use of reciprocating instruments, which slightly increased the removal of the remaining obturator material, but it was not statistically significant. Complementary techniques to improve the removal of the remaining filling material,

such as XP-Endo Finisher (36), have been studied with satisfactory results. Although the Passive Ultrasonic Irrigation has not been sufficient for the removal of gutta-percha in maxillary molars (19), it was useful when used in mandibular oval incisors after the use of REC 50 (30).

## Conclusions

No protocol could effectively remove all the gutta-percha and sealer from the root canal system. There was no significant reduction of the remaining obturator material in the apical third in the three systems studied, which shows that these systems were equivalent but not efficient for the removal of the gutta-percha in curved canals in mandibular molars. More studies are needed to evaluate the best instrument for gutta-percha removal during root canal retreatment, as well as the need for additional techniques to increase root canal cleansing (36, 37).

## Clinical Relevance

The present study aims to help clinicians understand the ability of different reciprocating instruments in the removing of sealer material from curved canals.

## Conflict of Interest

Nothing to declare.

## Acknowledgements

None.

## References

1. Pirani C, Zamparini F, Peters OA, et al. The fate of root canals obturated with Thermafil: 10-year data for patients treated in a master's program. *Clin Oral Investig* 2019;23:3367-77.
2. Fransson H, Dawson VS, Frisk F, et al. Survival of root-filled teeth in the Swedish adult population. *J Endod* 2016;42:216-20.
3. Ng YL, Mann V, Gulabivala K. Tooth survival following non-surgical root canal treatment: a systematic review of the literature. *Int Endod J* 2010;43:171-89.
4. Kvist T, Reit C. The perceived benefit of endodontic retreatment. *Int. Endod J* 2002;35:359-65.
5. Rios MA, Villela AM, Cunha RS, et al. Efficacy of 2 reciprocating systems compared with a rotary retreat-



- ment system for gutta-percha removal. *J Endod* 2014;40:543-6.
6. Fruchi LC, Ordinola-Zapata R, Cavenago BC, et al. Efficacy of reciprocating instruments for removing filling material in curved canals obturated with a single-cone technique: A micro-computed tomographic analysis. *J Endod* 2014; 40:1000-4.
  7. De Deus G, Belladonna FG, Zuolo AS et al. 3-dimensional ability assessment in removing root filling material from pair-matched oval-shaped canals using thermal-treated instruments. *J Endod* 2019;45:1135-41.
  8. Martins MP, Duarte MA, Cavenago BC, et al. Effectiveness of the ProTaper Next and Reciproc Systems in Removing Root Canal Filling Material with Sonic or Ultrasonic Irrigation: A Micro-computed Tomographic Study. *J Endod* 2017;43:467-71.
  9. Zuolo AS, Zuolo ML, Bueno CES, et al. Evaluation of the efficacy of TruShape and Reciproc File systems in the removal of root filling material: an ex-vivo micro-computed tomographic study. *J Endod* 2016;42:315-9.
  10. Alves FR, Marceliano-Alves MF, Sousa JC, et al. Removal of Root Canal Fillings in Curved Canals Using Either Reciprocating Single- or Rotary Multi-instrument Systems and a Supplementary Step with the XP-Endo Finisher. *J Endod* 2016;42:1114-9.
  11. Schneider SW. A comparison of canal preparations in straight and curved root canals. *Oral Surg Oral Med Oral Pathol* 1971;32:271-5.
  12. Saber SE, Nagy MM, Schäfer E. Comparative evaluation of the shaping ability of ProTaper Next, iRace and Hyflex CM rotary NiTi files in severely curved root canals. *Int Endod J* 2015;48:131-6.
  13. Nevaes G, de Albuquerque DS, Freire LG, et al. Efficacy of ProTaper NEXT compared with Reciproc in removing obturation material from severely curved root canals: a micro-computed tomography study. *J Endod*. 2016;42:803-8.
  14. Rossi-Fedele G, Ahmed HM. Assessment of Root Canal Filling Removal Effectiveness Using Micro-computed Tomography: A Systematic Review. *J Endod*.2017;43:520-6.
  15. Nair PNR. On the causes of persistent apical periodontitis: a review. *Int Endod J* 2006;39:249-81.
  16. Ricucci D, Siqueira JF Jr. Recurrent apical periodontitis and late endodontic treatment failure related to coronal leakage: a case report. *J Endo* 2011;37:1171-5.
  17. Ricucci D, Rocas IN, Alves FRF, et al. Apically extruded sealers: fate and influence on treatment outcome. *J Endod* 2016;42:243-9.
  18. Yilmaz F, Koc C, Kamburoglu K, et al. Evaluation of 3 Different Retreatment Techniques in Maxillary Molar Teeth by Using Micro-computed Tomography. *J Endod* 2018;44:480-4.
  19. Da Rosa RA, Santini MF, Cavenago BC, et al. Micro-CT evaluation of root filling removal after three stages of retreatment procedure. *Braz Dent J* 2015;26:612-8.
  20. Rodig T, Reicherts P, Konietzschke F, et al. Efficacy of reciprocating and rotary NiTi instruments for retreatment of curved root canals assessed by micro-CT. *Int Endod J* 2014;47:942-8.
  21. Bürklein S, Flüch S, Schäfer E. Shaping ability of reciprocating single- systems in severely curved canals: WaveOne and Reciproc versus WaveOne Gold and Reciproc blue. *Odontology* 2019;107:96-102.
  22. Bago I, Suk M, Katic M et al. Comparison of the effectiveness of various rotary and reciprocating systems with different surface treatments to remove gutta-percha and an epoxy resin-based sealer from straight root canals. *Int Endod J* 2019;52:105-13.
  23. Jørgensen B, Williamson A, Chu R, Qian F. The efficacy of the WaveOne reciprocating file system versus ProTaper Retreatment System in endodontic retreatment of two different obturating techniques. *J Endod* 2017;43:1011-3.
  24. Mukai AY, Limoeiro AG, De Martin AS, et al. The effectiveness of different rotary systems in the removal of gutta-percha and sealer obturation in ovoid canals. *Endod Pract* 2019;12:30-7.
  25. Bueno CE, Delboni MG, Araújo RA, et al. Effectiveness of Rotary and Hand Files in Gutta-percha and Sealer Removal Using Chloroform or Chlorhexidine Gel. *Braz Dent J* 2006;17:139-43
  26. Taşdemir T, Er K, Yildirim T, Çelik D. Efficacy of three rotary NiTi instruments in removing gutta-percha from root canals. *Int Endod J* 2008;41:191-6.
  27. Rubino AG, Candeiro GT, Gonzales LF, et al. Micro-CT Evaluation of Gutta-Percha Removal by Two Retreatment Systems. *Iran Endod J* 2018;13:221-7.
  28. Khedmat S, Azari A, Shamshiri AR, et al. Efficacy of ProTaper and Mtwo Retreatment Files in Removal of Gutta-percha and GuttaFlow from Root Canals. *Iran Endod J* 2016;11:184-7.
  29. Ma J, Al-Ashaw AJ, Shen Y, et al. Efficacy of ProTaper Universal Rotary Retreatment system for gutta-percha removal from oval root canals: a micro-computed tomography study. *J Endod* 2012;38:1516-20.
  30. Bernardes RA, Duarte MAH, Vivan RR, et al. Comparison of three retreatment techniques with ultrasonic activation in flattened canals using micro-computed tomography and scanning electron microscopy. *Int Endod J* 2016;49:890-7.
  31. Crozeta BM, Silva-Sousa YT, Leoni GB, et al. Micro-Computed Tomography Study of Filling Material Removal from Oval-shaped Canals by Using Rotary, Reciprocating, and Adaptive Motion Systems. *J Endod* 2016;42:793-7.
  32. Ozyurek T, Demiryurek EO. Efficacy of Different Nickel-Titanium Instruments in Removing Gutta-percha during Root Canal Retreatment. *J Endod* 2016;42:646-9.
  33. Prati C, Zamparini F, Spinelli A, et al. Secondary Root Canal Treatment with Reciproc Blue and K-File: Radiographic and ESEM-EDX Analysis of Dentin and Root Canal Filling Remnants. *J Clin Med* 2020 Jun 18;9:1902.
  34. Cavenago BC, Ordinola-Zapata R, Duarte MA, et al. Efficacy of xylene and passive ultrasonic irrigation on remaining root filling material during retreatment of anatomically complex teeth. *Int Endod J* 2014;47:1078-83.
  35. Vajrabhaya LO, Suwannawong SK, Kamolroongwarakul R, et al. Cytotoxicity evaluation of gutta-percha solvents: Chloroform and GP-Solvent (limonene). *Oral Surg Oral Med Oral Pathol Oral Radiol Endod* 2004;98:756-9.
  36. De-Deus G, Belladonna FG, Zuolo AS, et al. XP-endo Finisher R instrument optimizes the removal of root filling remnants in oval-shaped canals. *Int Endod J* 2019;52: 899-907.
  37. Aksel H, Eren SK, Ors SA, et al. Micro-CT evaluation of the removal of root fillings using the ProTaper Universal Retreatment system supplemented by the XP-Endo Finisher File. *Int Endod J* 2019;52:1070-7.