

ORIGINAL ARTICLE

# Comparative efficacy of depotphoresis and diode laser for reduction of microbial load and postoperative pain, and healing of periapical lesions: a randomized clinical trial

## ABSTRACT

**Aim:** To compare the efficacy of depotphoresis and diode laser (DL) for reduction of microbial load and postoperative pain, and healing of periapical lesions in teeth with necrotic pulp.

**Methods:** Ninety patients (98 roots) with pulp necrosis and chronic periapical lesions were randomized into three groups (n=30) of depotphoresis, diode laser, and control. Bacterial samples were collected from all roots at each treatment phase (S1: immediately after access cavity preparation, S2: immediately after cleaning and shaping, S3: one week after intracanal medicament). Analysis of bacterial reduction was performed using "Colony Forming Unit Counting" method. Level of pain was measured before and at 6, 12, 24, 48 and 72 hours after treatment using a visual analog scale (VAS). Cone-beam computed tomography (CBCT) images were obtained before and 6 months after treatment to assess the healing of periapical lesions based on their apicocoronal, mesiodistal and buccolingual diameter. Kruskal-Wallis and The Mann-Whitney test was used to determine the colony forming units and Compare the level of pain at different times between the groups of study, whilst the Univariate analyses using the chi-square or Fisher exact test were used to show the correlation of the outcomes with variables to identify the potential predisposing factors ( $P < 0.05$ ).

**Results:** At S1, no significant difference was noted among the three groups in microbial load. At S2 and S3, there was a statistically significant lower bacterial count in DL ( $P = 0.041$ ) and depotphoresis group ( $P = 0.001$ ) respectively, compared to other groups. All patients had mild pain at all time points post-treatment. Also the size of the preoperative periapical lesions had no significant effect on the outcome of endodontic treatment ( $p > 0.05$ ).

**Conclusions:** Root canal disinfection by depotphoresis and diode laser significantly decreased the microbial load as well as the post-endodontic pain and resulted in complete healing of some lesions in a short time.

Maryam Dalaei Moghadam<sup>1</sup>Eshagh Ali Saberi<sup>2\*</sup>Narges Farhad Molashahi<sup>2</sup>Heshmatollah Shahraki Ebrahimi<sup>2</sup>

<sup>1</sup>Department of Endodontic, Faculty of Dentistry, Zahedan University of Medical Science, Zahedan, Iran

<sup>2</sup>Oral and Dental Diseases Research Center, Department of Endodontics, Faculty of Dentistry, Zahedan University of Medical Sciences, Zahedan, Iran

Received 2021, June 24

Accepted 2021, September 30

**KEYWORDS** Apical Periodontitis, cone-beam computed tomography, depotphoresis, diode laser, disinfection, root canal

### Corresponding Author

Eshagh Ali Saberi | Oral and Dental Diseases Research Center, Department of Endodontics, Faculty of Dentistry, Zahedan University of Medical Sciences, Zahedan | Iran  
Tel. +98 9151416924 | Email: [saberi.endo@yahoo.com](mailto:saberi.endo@yahoo.com)

Peer review under responsibility of Società Italiana di Endodonzia

[10.32067/GIE.2021.35.02.38](https://doi.org/10.32067/GIE.2021.35.02.38)

Società Italiana di Endodonzia. Production and hosting by Ariesdue. This is an open access article under the CC BY-NC-ND license (<http://creativecommons.org/licenses/by-nc-nd/4.0/>).

## Introduction

**T**he main goal of endodontic treatment in teeth with necrotic pulp and chronic periapical lesions is to create a germ-free environment in the root canal system, and the adjacent periodontal tissue.

Endodontists generally have two main goals in root canal treatment. The short-term goal is to prevent/control pain, and the long-term goal is to achieve clinical and radiographic healing. To achieve this goal, the microbial load in the root canal system should be minimized (1). There are two main obstacles against achieving this goal namely the complex root canal anatomy and the unique properties of the bacterial flora in the root canal system. The microorganisms in the root canal system are inaccessible in some cases despite the use of advanced endodontic instruments (2). The residual bacteria in the root canal system can proliferate between the treatment sessions and reach their baseline preoperative count (3).

The treatment success has several criteria such as resolution of symptoms, periapical healing on radiographs, or histological evidence of healing. A number of factors affect the success of endodontic treatment such as the severity of condition, the instrumentation technique, and the technology used for treatment (4).

In the recent years, use of laser in endodontics has gained increasing popularity, yielding acceptable results as an adjunct for disinfection of the root canal system and reduction of bacterial load (5, 6). Several studies have confirmed the optimal efficacy of laser therapy for reduction of post-endodontic pain as well (7, 8).

Depotphoresis is another method of root canal treatment in which, the root canal is filled with Cupral (a copper-calcium-hydroxide based compound) and the electric current is guided into the root canal system with a fine probe. This technique dissolves the contents of the root canal by alkaline proteolysis, eliminates the oligopeptides formed in the root canal system, causes proteolysis, and eliminates the acidic bio-

logical remnants in the periapical region. Cupral penetrates into the dentinal tubules and disinfects them, and induces osteogenesis in the periapical region (9). Addition of copper ions to calcium hydroxide plays an important role in the process of tissue regeneration, and also exerts anti-inflammatory and disinfecting effects (10). Moreover, the electrically activated copper ions used in combination with calcium hydroxide exert significantly faster antibacterial effects in dentinal tubules compared with pure calcium hydroxide without electrical activation (11). However, it should be noted that studies on this topic are limited (9).

Cone-beam computed tomographic (CBCT) imaging is often used for diagnosis and treatment planning in endodontics. Also, CBCT enables the measurement of periapical lesions in three orthogonal planes (12). Moreover, evidence shows the superiority of CBCT for monitoring of the healing course of periapical lesions compared with periapical radiography (13). The novel root canal disinfection techniques, such as DL and depotphoresis, have improved the outcome of endodontic treatment.

Yalgi et al. (9) found that depotphoresis is effective in reducing postoperative pain and in the treatment of chronic apical periodontitis.

Some authors (14, 15) proposed that DL may be a successful adjunct to endodontic treatment of necrotic cases with chronic periapical lesions in terms of postoperative pain and root canal disinfection.

This study aimed to compare the effects of depotphoresis and DL on microbial count, postoperative pain, and healing of periapical lesions after 6 months by using CBCT.

## Materials and Methods

The study population comprise of 90 patients presenting to the Endodontics Department of School of Dentistry, Zahedan University of Medical Sciences who required endodontic treatment of teeth with pulp necrosis associated with chronic apical periodontitis. The patients were



between 18 to 60 years, and the diagnosis of pulp necrosis with chronic apical periodontitis was confirmed by radiographic examination and negative response to cold test and electric pulp test, and no bleeding when exposing the pulp.

The protocol of this prospective, three-arm, parallel-group, single-blind, single-center, randomized clinical trial and the informed consent form were approved by the Research Ethics Committee of Zاهدان University of Medical Science (IR.ZAUMS.REC.1397.278).

The study protocol was registered at <https://en.irct.ir/trial/3284> (Iranian Registry of Clinical Trials identification number IRCT20180718040517N1).

This study was conducted and reported in accordance with the consolidated standards of reporting trials (CONSORT) (19). All enrolled patients signed informed consent forms after the nature of the study, its objectives, procedures, benefits and potential risks were explained to them.

#### *Sample size calculation*

A pilot study was designed to determine the size of the study population. Data obtained from the pilot study indicated that the sample size for each group should be a minimum of 25. Considering the possibility of dropouts, 30 patients were allocated to each group (a total of 90) assuming the effect size of 0.82, power of 80%, and 0.05 level of significance. The patients were enrolled from the outpatient clinic of the Department of Endodontics, Faculty of Dentistry between December 2018 and June 2020. One postgraduate student of endodontics performed the procedures.

#### *Inclusion and exclusion criteria*

The patients were between 18 to 60 years, and the diagnosis of pulp necrosis was confirmed by negative response to cold test and electric pulp test, and no bleeding when exposing the pulp. Diabetic patients, immunocompromised patients, pregnant women, and those with a history of analgesic intake in the past 3 days or antibiotic intake in the past month were excluded. Teeth with periodontal disease, or previ-

ous access cavity and those that could not be isolated by rubber dam were excluded as well.

#### *Randomization, allocation concealment and masking of examiners*

The patients were allocated to the three study arms with simple randomization. Randomization was performed online ([endo.dent.zaums.ac.ir](http://endo.dent.zaums.ac.ir)) right before the treatment onset. After recording the patients' demographics, eligible patients were automatically randomized into the three study groups of depotphoresis, diode laser, and control by using a computergenerated system. All the allocated patients received a unique patient identification code before starting the treatment. In the event of withdrawal from the study, the randomization code was not reused. Patient blinding was implemented. In Control group, in 15 patients, the fiber optic was placed inside the root canals without activation and in 15 other patients, red clip of depotphoresis was placed on the patient's cheek and blue clip was placed above the tooth's root canal without any current.

In the DL group, without any current, Red and blue clips, were placed inside the patient's mouth, as mentioned earlier. All patients and the operator wore protective glasses during all stages of the operation in all groups.

In the depotphoresis group, a mock application of laser was made with the power off.

#### *Interventions*

In the first session, the level of pain of patients was recorded before treatment using a visual analog scale (VAS). After dental flossing and dental plaque removal by pumice paste, rubber dam isolation was performed, and the tooth and the treatment area were disinfected with 30% H<sub>2</sub>O<sub>2</sub> (v/v) for 30 s followed by 2.5% NaOCl. The access cavity was prepared with sterile high-speed bur (Tizcavan, Tehran, Iran) without water spray. After completion of access cavity preparation and caries removal (prior to exposure of the pulp chamber), the tooth, the clamp,



and the rubber dam were disinfected again with 2.5% NaOCl; 5% sodium thiosulfate was then used to neutralize sodium hypochlorite. Dental pulp was then exposed. Next, three sterile paper points were placed in the canal for 1 min to collect the first microbial sample (prior to root canal preparation). The collected sample (S1) was transferred into a tube containing HBI buffer and frozen at -20 °C.

A sterile #15H-file (Dentsply/Maillefer, Ballaigues, Switzerland) was then introduced into the canal, and the working length was determined by an apex locator (ROOT ZX; J. Morita, Tokyo, Japan) and confirmed radiographically. The narrow root canals were prepared with 25/8% Reciproc file (VDW, Munich, Germany) while the wide canals were prepared with 40/6% Reciproc file along with Reciproc Silver electric motor. Also, 2.5% NaOCl and 17% EDTA (Aria Dent, Tehran, Iran) were used for root canal irrigation. After chemomechanical preparation of the root canals, sterile saline was injected into the canals by a 27-gauge needle to a level below the orifice. Next, #30 Hedstrom file (Dentsply, Maillefer, Ballaigues, Switzerland) was used for filing and agitation of the canal content. This was done to enhance the release of dentin chips into the saline. Subsequently, three sterile paper points were introduced into the canal one by one and remained there for 60 s to collect the second sample (S2). Under aseptic conditions, the collected sample was transferred into a tube containing HBI buffer by a sterile hemostat and frozen at -20 °C. It was transferred to the lab on the same day.

Depotphoresis (Humamchemic GmbH, Alfeld, Germany) group: Cupral paste was prepared according to the manufacturer's instructions (to prepare Cupral solution, 1 unit of Cupral was mixed with 9 units of calcium hydroxide) and delivered into the coronal third of the canal by a Lentulo spiral. The positive electrode was connected to the patient's buccal mucosa by a clamp. The negative electrode was placed in the pulp chamber and the electric current was initiated and gradually increased (the current suggested by the manufacturer is 0.8-1.5 mA/5 min). The tooth was

temporarily restored with Cavit (Golchay, Tehran, Iran) while calcium hydroxide Cupral remained in the canal as medication.

#### *Laser group*

After root canal preparation, it was rinsed with saline and cleaned with paper points. Next, 940 nm diode laser (EPIC X, BIO-LASE, Irvine, CA, USA) hand-piece with 200 µm tip diameter (EZTIP400&300) was introduced into the canal to 1 mm from the apex and was then pulled back with a circular motion at a speed of 2 mm/s towards the orifice. After 20 s of laser irradiation in pulse-mode, dental substrate was allowed to rest for 10 s. Laser irradiation was repeated 3 times. The laser parameters included  $\lambda=940$  nm and 2 W power. The second samples were then collected (S2). The root canals were filled with a mixture of calcium hydroxide and saline, delivered into the canal by a Lentulo spiral (Dentsply Maillefer) as medication, and temporarily restored with Cavit (Golchay, Tehran, Iran) between the treatment sessions.

#### *Control group*

After root canal disinfection and instrumentation, a mixture of calcium hydroxide and saline was delivered into the canal by a Lentulo spinal as medication and temporarily restored with Cavit (Golchay, Tehran, Iran) between the treatment sessions.

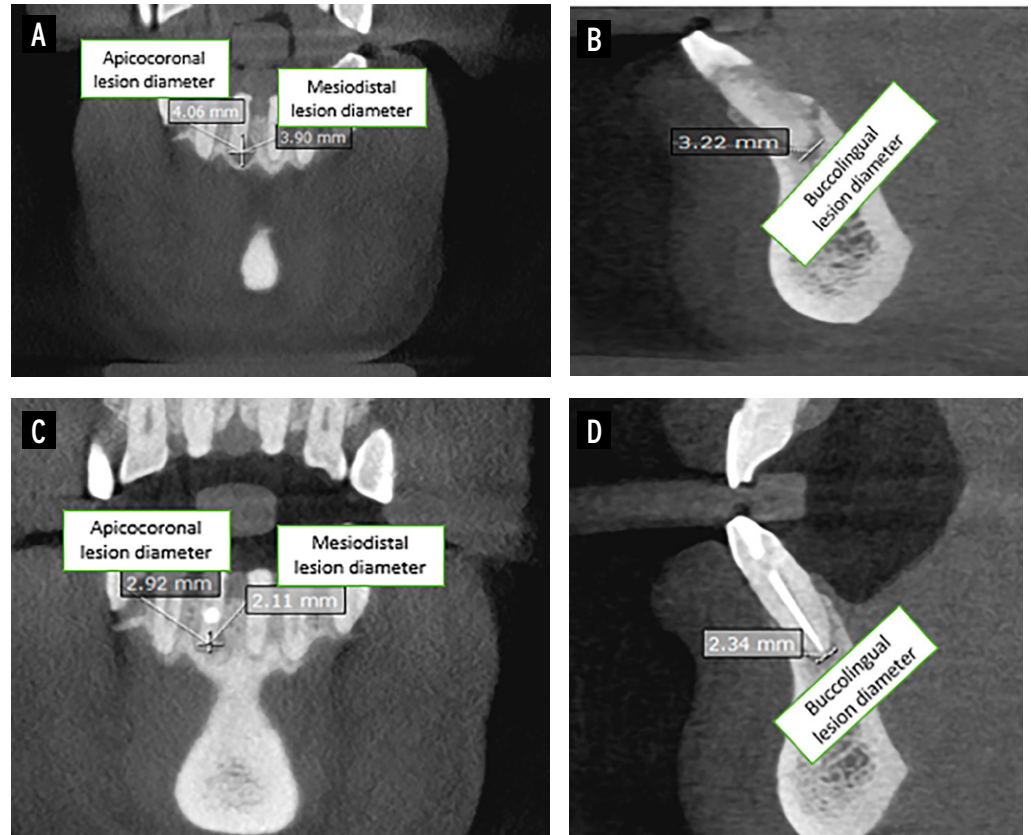
#### *Post-endodontic pain assessment*

After completion of the first treatment session, the patients received a VAS form (graded from 0 to 10). They were instructed on how to fill out the VAS form and were requested to express their level of pain by selecting the score that best described their pain severity at 6, 12, 24, 48 and 72 h, post-treatment. A recall visit was also scheduled for them 7 days after treatment. Independent examiners who were blinded to the group allocation of patients evaluated the VAS forms.

#### *Second treatment session*

After removing the intracanal medica-

**Figure 1**  
**A, B** Measurement of the preoperative diameter of the lesion and **C, D** diameter of the lesion after 6 months.



ments (calcium Cupral in depotphoresis group and calcium hydroxide in laser and control groups), the third sampling (S3) was performed as explained earlier. The teeth were then obturated and filled with composite resin. All endodontic treatments were performed by a post-graduate student of endodontics within 8 months.

#### *Microbial analysis*

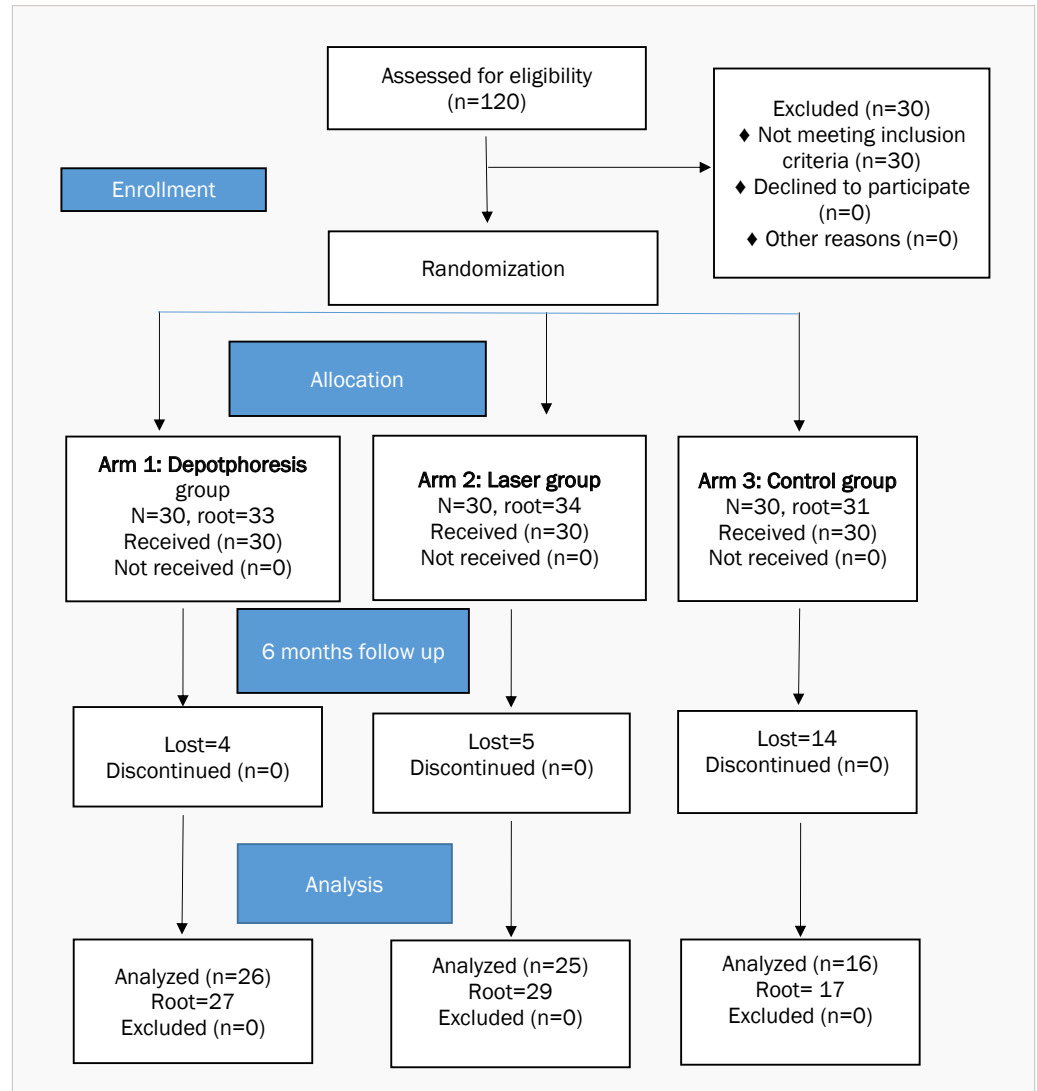
The microbiological assessment was conducted by the “Colony Forming Unit Counting” method. Samples were transported to the laboratory within two hours after collection for microbiologic assessment. Samples in RTF vials were mixed well with a vortex for 30 seconds to facilitate bacterial dispersion. 10-fold serial dilutions were made in Phosphate Buffer Saline (PBS) solution. 10 ml of the sample was transferred to a sterile tube. 10 tubes containing 9 ml sterile saline were placed in a tube holder. An aliquot of 1 ml from the original sample was then transferred into the first tube containing 9ml of sterile saline. This process was repeated for each

of the remaining 9 tubes. At the end of the 10-fold dilutions, 10 tubes covering the dilution range of  $1:10^{-1}$  through to  $1:10^{-10}$  had been made. For each tube, 1ml of the diluted sample was transferred to BHI agar plates and cultured under aseptic conditions. The plates were incubated at  $37^{\circ}\text{C}$  for 24 hours for the bacteria to grow. The number of bacterial colonies in each plate was visually quantified and reported as colony forming units per milliliter (CFU/ml). The number of bacteria (CFU) per milliliter of sample was calculated by dividing the number of colonies by the dilution factor. At last the outer numbers were thrown out and mean of the rest of numbers were calculated.

#### *Radiographic technique*

The healing of periapical lesions was evaluated on CBCT scans. Prior to the treatment onset, the respective tooth underwent CBCT. All primary and follow-up CBCT scans were performed by Acteon CBCT scanner (Acteon Group, Norwich, United Kingdom). All CBCT scans were obtained

**Figure 2**  
Consort flowchart  
of the study.



with 40 mm<sup>3</sup> field of view and 0.2 µm voxel size with the exposure settings of 8 mA, 85 kVp and 10 s exposure time. All CBCT images were analyzed using OnDemand 3D software (CyberMed, Seoul, Republic of Korea).

#### *Radiographic assessment*

The following parameters were evaluated. Diameter of lesions: the maximum diameter of periapical lesions was measured in three directions of apicocoronal (Ly), mesiodistal (Lx) and buccolingual (Lz) parallel to the standard axis according to Kim et al (16) (Figure 1) If the lesion did not have a bony margin (for example, if the cortical plate or sinus wall had been per-

forated), the examiner would be asked to estimate the size of the lesion based on the visible bone margin at each side of the bone defect. The radiographic findings were analyzed according to Patel et al. (17) with some differences. Since the present study focused on root canal treatment of the teeth with chronic apical periodontitis, the codes 1 and 6 from the study by Patel et al. (17) were not applicable to our study. The CBCT images were evaluated by two endodontists, and in case of disagreement, a third endodontist was asked to cast the final judgment.

#### *Statistical analysis*

Data were analyzed with SPSS 23.0 (SPSS

**Table 1**

**Bacterial count in 98 root canals with chronic apical periodontitis immediately after access cavity preparation (S1), after chemo-mechanical preparation (S2) and at one week after intracanal medicament (S3)**

Group	immediately after access cavity preparation (S1)		immediately after cleaning and shaping (S2)		one week after intra canal medicament (S3)		P value
	Mean	Std. deviation	Mean	Std. deviation	Mean	Std. deviation	
Laser group	6080000±14150000		4323±2569		3075±2870		.000
Depotphoresis group	3070000±6602844		9370±33450		801±1089		.000
Control group	5770000±13610000		18400±22895		9998.6±15414		.000
P value*	.565		.041		.001		

Inc., Chicago, IL, USA). Bacterial colony forming unit and the comparison of pain scores between the three groups at each time interval were analyzed using the Kruskal-Wallis and Mann-Whitney U tests. Univariate analyses using the chi-square or Fisher exact test were performed to show the correlation of outcomes with variables to identify the potential predisposing factors. Multivariate analysis using a logistic regression model was performed with associated variables.  $P < 0.05$  was considered statistically significant.

## Results

Of 90 patients, 71 (78%) were females and 19 (21%) were males. The mean age of patients was 34 years (range 18 to 60 years). A total of 90 teeth (98 roots) including anterior and posterior maxillary and mandibular teeth were evaluated; 67 patients (74 roots) showed up for the follow-up. Consort flowchart Shown in Figure 2.

## Colony count

Table 1 reveals bacterial colony count before (S1) and after root canal preparation (S2) and One week after intra canal medicament (S3) observed in all groups. All groups presented effective bacterial reduction.

The results of the bacterial count of the DL group and Depotphoresis group showed statistically significant reduction in the bacterial count at S2 ( $p = .041$ ) and S3 ( $p = .001$ ) compared to other groups respectively.

## Severity of pain

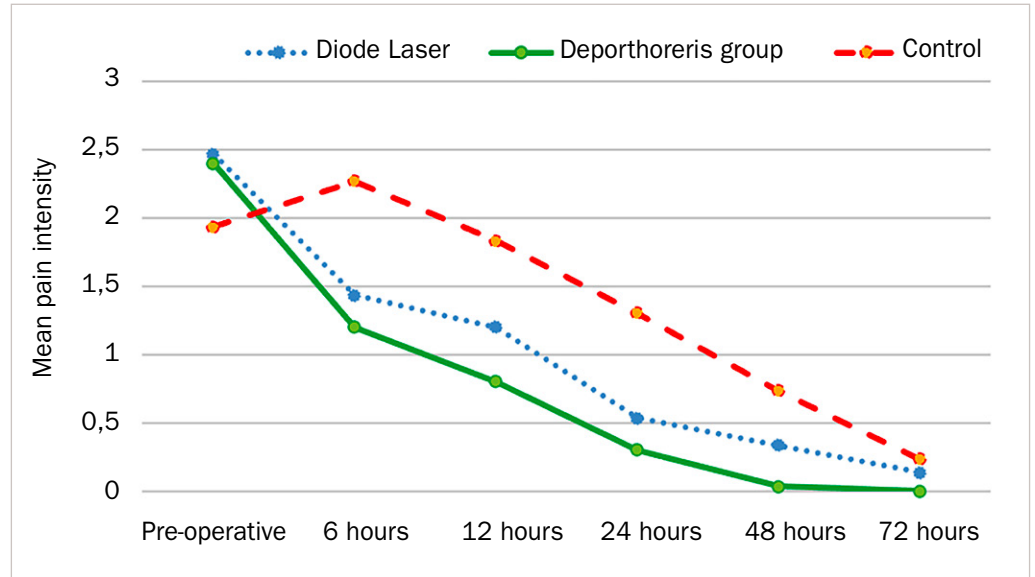
Figure 3 shows the severity of pain in the three groups. The mean pain score revealed statistically significant lower pain levels in the Depotphoresis group compared with the control group at 6, 12, 24 and at 48 hours ( $P = 0.02$ ,  $P = 0.007$ ,  $P = 0.001$  and  $P = 0.004$  respectively), but had no significant difference with the values in the laser group ( $P > 0.05$ ). Also preopera-

**Table 2**

**Frequency distribution of patients who showed up for the follow-up**

		Depotphoresis		Laser		Control	
		Count	%	Count	%	Count	%
Gender	Male	10	38.46	6	24.00	1	6.25
	Female	16	61.54	19	76.00	15	93.75
Number of lesions		27		29		17	
Involved Jaw	Maxilla	9	34.62	11	44.00	5	31.25
	Mandible	17	65.38	14	56.00	11	68.75
Age		25.62±11.36		32.44±13.44		26.29±12.45	

**Figure 3**  
Mean pain score in the three groups at different time points.



tively there was no statistical significance difference between the evaluated groups ( $P=0.564$ ).

#### *Clinical and radiographic assessments at 6 months after treatment*

Sixty-seven patients (74 roots) showed up for the follow-up session (recall rate=74%, Table 2). All endodontically treated teeth were asymptomatic and functional at the follow-up session. Coronal restorations were intact. The follow-up CBCT scans showed that all apical lesions experienced a reduction in size (were in the course of healing) or had completely healed. Thus, only codes 4 and 5 were used in this study. Table 3 shows the frequency of completely healed or healing lesions with  $\leq 5$  mm diameter and  $> 5$  mm diameter in apico-coronal, mesiodistal, and buccolingual directions in the three groups.

The current results revealed no significant difference in healing status of the lesions with mesiodistal and buccolingual diameter  $\leq 5$  mm and  $> 5$  mm in depotphoresis group ( $P>0.05$ ). However, this difference was significant between lesions with apico-coronal diameter  $\leq 5$  mm and  $> 5$  mm ( $P=0.037$ ) such that 33.33% of such lesions had completely healed. No significant difference was noted in healing status of the lesions with diameter  $\leq 5$  mm and  $> 5$  mm in the laser group ( $P>0.05$ ). Also, none of the lesions in the control group showed

complete healing. Table 4 compares the abovementioned parameters among the three groups. Except in depotphoresis group that the success rate was higher in the cases with lesions  $\leq 5$  mm in apico-coronal diameter ( $P=0.042$ ), there was no positive correlation between the outcome of the therapy and the size of the periapical lesions diameters in all groups ( $p>0.05$ ).

## Discussion

In this study, the antibacterial results showed statistically significant lower bacterial count in the S2 samples of DL group and in the S3 samples of depotphoresis group than the other groups respectively.

The results of this study showed that the Depotphoresis group had statistically significant lower pain levels than the control group at all tested time intervals (6, 12, 24, 48 and 72 hours). There were no significant differences between DL group and Depotphoresis group.

The success rate was higher in the cases with lesions  $\leq 5$  mm in diameter in Depotphoresis group at Apico-coronal directions; however, there was no statistically significant difference between the three groups in the Buccolingual and mesiodistal directions.

As mentioned earlier, statistically significant reduction in the bacterial count was





**Table 3**  
Frequency distribution of patients based on preoperative and outcome variables

Categories	Variables		Healing		Healed		P value
			Count	%	Count	%	
Depotphoresis	Mesiodistal lesion diameter (Lx)	size>5 mm	13	76.47	4	23.53	.136
		size≤5 mm	10	100			
	Buccolingual lesion diameter (Ly)	size≤5 mm	13	86.67	2	13.33	.299
		size>5 mm	12	100			
	Apicocoronal diameter (Lz)	size≤5 mm	10	66.67	5	33.33	.037
		size>5 mm	12	100			
Laser	Mesiodistal lesion diameter (Lx)	size≤5 mm	12	100			.335
		size>5 mm	15	88.24	2	11.76	
	Apicocoronal lesion diameter (Ly)	size≤5 mm	7	100			.331
		size>5 mm	20	90.91	2	9.09	
	Buccolingual lesion diameter (Lz)	size≤5 mm	12	100			.569
		size>5 mm	15	88.24	2	11.76	
Control	Mesiodistal lesion diameter (Lx)	size≤5 mm	6	100			
		size>5 mm	11	100			
	Apicocoronal lesion diameter (Ly)	size≤5 mm	2	100			
		size>5 mm	15	100			
	Buccolingual lesion diameter (Lz)	size≤5 mm	4	100			
		size>5 mm	13	100			

P value=comparison of frequency of healed and healing lesions within each treatment group.

P value\*=comparison of the frequency of healing status.

noted in all three groups after root canal preparation and disinfection (S2), which can be related to the effect of chemomechanical preparation of the root canal system and the disinfecting property of the interventions.

Microbiologists believe that diode laser irradiation results in permanent degradation of the cell membrane and changes the cell wall due to the direct effect of heat on the bacteria (14). Clinical use of different types of diode laser with near-infrared wavelength for disinfection of the root canal system has been well documented (18). These lasers penetrate deep (by up to 1000 µm) into dentin (19). Despite the attenuation of laser light when passing through the enamel prisms and dentinal tubules, it preserves its bactericidal effects (20).

In the present study, the reduction in bacterial count in the laser and depotphoresis groups was significantly greater than that in the control group at 1 week after treatment (S3). In the Depotphoresis group,

Calcium hydroxide Cupral and in the DL group, Calcium hydroxide were used as intracanal medicament. The results of previous studies regarding the efficacy of calcium hydroxide as intracanal medicament are controversial (21, 22).

Some studies have confirmed its efficacy while some others have questioned it (23, 24). Due to the low solubility of calcium hydroxide and its low penetration depth into dentinal tubules, its long-term application is required for disinfection of dentinal tubules and reduction of inflammatory root resorption; which can decrease the fracture resistance of dentin and increase the risk of root fracture (11). Considering the drawbacks of calcium hydroxide, attempts are ongoing to improve its antibacterial properties. Evidence shows that use of silver or copper in combination with calcium hydroxide improves its antibacterial properties (25). Calcium hydroxide Cupral is used in depotphoresis (11). A previous study revealed

**Table 4**  
**Comparison of the frequency of healing and completely healed lesions with  $\leq 5$  and  $> 5$  mm initial diameter in the study groups**

			$\leq 5$ mm			$> 5$ mm		
			Depotphoresis	Laser	Control	Depotphoresis	Laser	Control
<b>Mesiodistal lesion diameter (Lx)</b>	<b>Healing</b>	Count	13	12	6	10	15	11
		%	76.47	100	100	100	88.24	100
	<b>Healed</b>	Count	4				2	
		%	23.53				11.76	
	<b>P value</b>		-	-	-	-	.001	-
	<b>P value*</b>		<b>0.271</b>			<b>0.277</b>		
<b>Buccolingual lesion diameter (Lz)</b>	<b>Healing</b>	Count	13	7	2	12	20	15
		%	86.67	100	100	100	90.91	100
	<b>Healed</b>	Count	2				2	
		%	13.33				9.09	
	<b>P value</b>			-	-	-	.001	-
	<b>P value*</b>		<b>0.52</b>			<b>0.278</b>		
<b>Apicocoronal lesion diameter (Ly)</b>	<b>Healing</b>	Count	10	12	4	12	15	13
		%	66.67	100	100	100	88.24	100
	<b>Healed</b>	Count	5				2	
		%	33.33				11.76	
	<b>P value</b>			-	-	-	.001	-
	<b>P value*</b>		<b>0.042</b>			<b>0.214</b>		

*P value=comparison of frequency of healed and healing lesions within each study group.*

*P value\*=comparison of the frequency of healing status.*

that electrical stimulation of copper applied in combination with calcium hydroxide resulted in significantly higher antibacterial activity than the use of pure calcium hydroxide without electric stimulation (26). Knappvost et al. (26) reported similar results by addition of copper to calcium hydroxide and its electrical stimulation. They showed that calcium hydroxide/copper was 100 times more bactericidal than calcium hydroxide alone, and its efficacy did not decrease over time. These results are in accordance with our findings.

Another objective of the present study was to assess the level of pain in the three groups. The results showed a reduction in pain severity in all three groups after treatment. The most common factors re-

lated to post-endodontic pain include presence of microorganisms in the root canal system, and procedural errors such as over-instrumentation or inadequate cleaning, shaping or disinfection of the root canal. Nonetheless, a high number of patients experience post-endodontic pain without the aforementioned errors (27). Evidence shows that diode laser can effectively decrease post-endodontic pain (8, 27, 28). Diode laser exerts its anti-inflammatory effect by reduction of prostaglandin E2, bradykinin, histamine, acetyl choline, serotonin, and substance P, and decreases the chronic pain as such (29).

Chow et al. (29) in a systematic review suggested that laser light (energy density  $>300$  mW/cm<sup>2</sup>) absorbed by nociceptors can inhibit the pain signal transmission



through the A-delta and C fibers. Thus, it can decrease the speed of conduction and the action potential threshold of neurons and suppress neurogenic inflammation as such (29). In the present study, root canal irradiation was performed with laser in pulse mode to minimize the risk of thermal damage to the external root surface, which was effective for reduction of post-endodontic pain.

Yalgi et al. (9) used depotphoresis for endodontic treatment of necrotic teeth with chronic apical periodontitis in 30 patients. Twenty patients who had symptomatic pain at baseline had no pain after 3 days. However, studies on depotphoresis are limited. Another objective of the present study was to compare the healing rate of periapical lesions among the study groups. A total of 67 patients (74.4%) showed up for the follow-up session. Although higher recall rate is ideal, 75% is also acceptable. There was no case of treatment failure in the follow-up session; however, the frequency of healing lesions was significantly higher than that of healed lesions, which may be due to the short duration of follow-up (6 months).

In this study, each root was considered as one unit although Friedman (30) et al. stated that this method would result in over-estimation of the success rate, some others were against this statement (16, 31). Some studies found no positive correlation between the size of periapical lesions and the treatment outcome. (32, 33). Nonetheless, size of lesion had a significant effect on treatment success in some other studies. (31, 34, 35).

The negative effect of larger lesions on treatment success is due to the higher diversity of microorganisms and their association with longstanding infections because the bacteria in such lesions have greater penetration into the dentinal tubules. Moreover, these lesions may be associated with cystic transformation. (36) On the other hand, larger lesions in some patients have a slower response to ecological changes caused by the treatment protocol (37).

Evidence shows many cases of complete healing in presence of viable bacteria in

the root canal at the time of obturation because the residual bacteria may be eliminated due to the toxicity of root filling materials, inaccessibility/unavailability of nutrients, or impairment of bacterial ecology. Alternatively, the residual bacteria may not have adequate quantity or virulence to continue the periradicular inflammation or may not have access to the periradicular tissues (38).

## Conclusions

Both depotphoresis and DL groups, showed satisfactory bactericidal effects in cases of necrotic teeth with periapical lesions. Depotphoresis and intracanal diode laser irradiation have the ability to decrease the postoperative pain experienced after root canal treatment. Also the size of the preoperative periapical lesions had no significant effect on the outcome of endodontic treatment.

## Clinical Relevance

DL and depotphoresis are effective in reducing intracanal bacteria count and postoperative pain after endodontic treatment in necrotic teeth with chronic apical lesions.

## Conflict of Interest

None.

## Acknowledgements

This study was a specialized thesis in endodontics accepted by the Deputy of Research of Dental School, Zahedan University of Medical Sciences.

The authors would like to thank the Research Deputy of Zahedan University of Medical Sciences for financially supporting this project.

## References

- 1 Verma N, Sangwan P, Tewari S, Duhan J. Effect of different concentrations of sodium hypochlorite on outcome of primary root canal treatment: a randomized controlled trial. *Journal of endodontics*. 2019;45(4):357-63.

- 2 Bonsor S, Nichol R, Reid T, Pearson G. Microbiological evaluation of photo-activated disinfection in endodontics (an in vivo study). *British dental journal*. 2006;200(6):337-41.
- 3 Afkhami F, Akbari S, Chiniforush N. Enterococcus faecalis elimination in root canals using silver nanoparticles, photodynamic therapy, diode laser, or laser-activated nanoparticles: an in vitro study. *Journal of endodontics*. 2017;43(2):279-82.
- 4 Baker BW. Systematic review of the published literature on success and failure rates of nonsurgical endodontic treatment. 2013.
- 5 Gutknecht N, Al-Karadaghi TS, Al-Maliky MA, Conrads G, Franzen R. The bactericidal effect of 2780 and 940 nm laser irradiation on *Enterococcus faecalis* in bovine root dentin slices of different thicknesses. *Photomedicine and laser surgery*. 2016;34(1):11-6.
- 6 de Souza EB, Cai S, Simionato MRL, Lage-Marques JL. High-power diode laser in the disinfection in depth of the root canal dentin. *Oral Surgery, Oral Medicine, Oral Pathology, Oral Radiology, and Endodontology*. 2008;106(1):e68-e72.
- 7 Kreisler M, Al Haj H, Noroozi N, Willershausen B, d'Hoedt B. Efficacy of low level laser therapy in reducing postoperative pain after endodontic surgery-a randomized double blind clinical study. *International journal of oral and maxillofacial surgery*. 2004;33(1):38-41.
- 8 Kuzekanani M, Plotino G, Gutmann JL. Current applications of lasers in endodontics. *Giornale Italiano di Endodonzia*. 2019;33.
- 9 Yalgi VS. Treatment of Chronic Apical Periodontitis Using Depotphoresis: A Clinical Trial. *Indian Journal of Stomatology*. 2013;4(4):130.
- 10 Gergova RT, Gueorgieva T, Dencheva-Garova MS, Krasteva-Panova AZ, Kalchinov V, Mitov I, et al. Antimicrobial activity of different disinfection methods against biofilms in root canals. *Journal of investigative and clinical dentistry*. 2016;7(3):254-62.
- 11 Fuss Z, Mizrahi A, Lin S, Cherniak O, Weiss E. A laboratory study of the effect of calcium hydroxide mixed with iodine or electrophoretically activated copper on bacterial viability in dentinal tubules. *International endodontic journal*. 2002;35(6):522-6.
- 12 Polinsky AS. Evaluation and Comparison of Periapical Healing Using Periapical Films and Cone Beam Computed Tomography: Post-Treatment Follow Up. 2019.
- 13 Diwan A, Sreedevi C, Nagaraj T, Raghava V, Sinha P, Moushmi C. Determination of internal anatomy of a permanent dentition: A review. *Int J Contemp Dent Med Rev*. 2015;2015:110115.
- 14 Morsy DA, Negm M, Diab A, Ahmed G. Postoperative pain and antibacterial effect of 980 nm diode laser versus conventional endodontic treatment in necrotic teeth with chronic periapical lesions: A randomized control trial. *F1000Research*. 2018;7.
- 15 Kaplan T, Sezgin GP, Kaplan SS. Effect of a 980-nm diode laser on post-operative pain after endodontic treatment in teeth with apical periodontitis: a randomized clinical trial. *BMC oral health*. 2021;21(1):1-9.
- 16 Kim D, Ku H, Nam T, Yoon T-C, Lee C-Y, Kim E. Influence of size and volume of periapical lesions on the outcome of endodontic microsurgery: 3-dimensional analysis using cone-beam computed tomography. *Journal of endodontics*. 2016;42(8):1196-201.
- 17 Patel S, Wilson R, Dawood A, Foschi F, Mannocci F. The detection of periapical pathosis using digital periapical radiography and cone beam computed tomography-Part 2: a 1-year post-treatment follow-up. *International endodontic journal*. 2012;45(8):711-23.
- 18 Rôças IN, Siqueira Jr JF. Detection of antibiotic resistance genes in samples from acute and chronic endodontic infections and after treatment. *Archives of Oral Biology*. 2013;58(9):1123-8.
- 19 Montagner F, Jacinto RC, Signoretti FGC, de Mattos VS, Grecca FS, de Almeida Gomes BPF. Beta-lactamase resistance profiles in *Porphyromonas*, *Prevotella*, and *Parvimonas* species isolated from acute endodontic infections. *Journal of endodontics*. 2014;40(3):339-4.
- 20 Suliman Al-Badah A, SS Ibrahim A, Al-Salamah AA, Ibrahim SSS. Clonal diversity and antimicrobial resistance of *Enterococcus faecalis* isolated from endodontic infections. *Electronic journal of Biotechnology*. 2015;18(3):175-80.
- 21 Mohammadi Z, Shalavi S, Yazdizadeh M. Antimicrobial activity of calcium hydroxide in endodontics: a review. *Chonnam medical journal*. 2012;48(3):133-40.
- 22 Nascimento GG, Rabello DG, Corazza BJ, Gomes AP, Silva EG, Martinho FC. Comparison of the effectiveness of single and multiple-sessions disinfection protocols against endotoxins in root canal infections: systematic review and meta-analysis. *Scientific reports*. 2021;11(1):1-10.
- 23 Balto KA. Calcium hydroxide has limited effectiveness in eliminating bacteria from human root canal. *Evidence-based dentistry*. 2007;8(1):15-6.
- 24 Peters L, Van Winkelhoff AJ, Buijs J, Wesselink P. Effects of instrumentation, irrigation and dressing with calcium hydroxide on infection in pulpless teeth with periapical bone lesions. *International endodontic journal*. 2002;35(1):13-21.
- 25 Yousefshahi H, Aminsobhani M, Shokri M, Shahbazi R. Anti-bacterial properties of calcium hydroxide in combination with silver, copper, zinc oxide or magnesium oxide. *European journal of translational myology*. 2018;28(3).
- 26 Tsesis I, Lin S, Weiss EI, Fuss Z. Dentinal pH changes following electrophoretically activated calcium hydroxide ions in the root canal space of bovine teeth. *Dental Traumatology*. 2005;21(3):146-9.
- 27 Genc Sen O, Kaya M. Effect of root canal disinfection with a diode laser on postoperative pain after endodontic retreatment. *Photobiomodulation, photomedicine, and laser surgery*. 2019;37(2):85-90.
- 28 Pawar SS, Pujar MA, Makandar SD, Khaizer MI. Postendodontic treatment pain management with low-level laser therapy. *Journal of Dental Lasers*. 2014;8(2):60.
- 29 Chow R, Armati P, Laakso E-L, Bjordal JM, Baxter GD. Inhibitory effects of laser irradiation on peripheral mammalian nerves and relevance to analgesic effects: a systematic review. *Photomedicine and laser surgery*. 2011;29(6):365-81.
- 30 Friedman S, Mor C. The success of endodontic therapy healing and functionality. *CDA J*. 2004;32(6):493-503.
- 31 Ng YL, Mann V, Gulabivala K. A prospective study



- of the factors affecting outcomes of nonsurgical root canal treatment: part 1: periapical health. *International endodontic journal*. 2011;44(7):583-609.
- 32 Moazami F, Sahebi S, Sobhnamayan F, Alipour A. Success rate of nonsurgical endodontic treatment of nonvital teeth with variable periradicular lesions. *Iranian endodontic journal*. 2011;6(3):119.
- 33 Aksoy F. Outcomes of nonsurgical endodontic treatment in teeth with large periapical lesion. 2019.
- 34 Hoskinson SE, Ng Y-L, Hoskinson AE, Moles DR, Gulabivala K. A retrospective comparison of outcome of root canal treatment using two different protocols. *Oral Surgery, Oral Medicine, Oral Pathology, Oral Radiology, and Endodontology*. 2002;93(6):705-15.
- 35 Chugal NM, Clive JM, Spångberg LS. A prognostic model for assessment of the outcome of endodontic treatment: effect of biologic and diagnostic variables. *Oral Surgery, Oral Medicine, Oral Pathology, Oral Radiology, and Endodontology*. 2001;91(3):342-52.
- 36 Karamifar K, Tondari A, Saghiri MA. Endodontic periapical lesion: An overview on the etiology, diagnosis and current treatment Modalities. *European Endodontic Journal*. 2020;5(2):54.
- 37 Sabala CL, Benenati FW, Neas BR. Bilateral root or root canal aberrations in a dental school patient population. *Journal of endodontics*. 1994;20(1):38-42.
- 38 Paiva SS, Siqueira Jr JF, Rôças IN, Carmo FL, Leite DC, Ferreira DC, et al. Molecular microbiological evaluation of passive ultrasonic activation as a supplementary disinfecting step: a clinical study. *Journal of endodontics*. 2013;39(2):190-4.