

## CASE REPORT

# Controlled drug delivery system endodontic paste as intracanal medication: a bench-to-chair-side case report

## ABSTRACT

**Aim:** To report a new endodontic paste as intracanal medication in an immature tooth with acute periradicular abscess.

**Summary:** A 9-year-old male child presented to the School of Dentistry with spontaneous moderate pain and swelling in the left permanent mandibular first molar region. Radiographic and intraoral clinical exams revealed previous endodontic treatment with an extensive radiolucent area and incomplete rhizogenesis. The clinical diagnosis was acute periradicular abscess, leading to retreatment. After desobturation and chemical-mechanical preparation, the paste composed of tricalcium phosphate, calcium tungstate, amoxicillin microspheres, and indomethacin nanocapsules was inserted into the root canal system. After 5 months, there were no patient-related symptoms, and an apical barrier has formed with decreased periradicular radiolucent area was observed. The root canal filling and tooth restoration were conducted. At the 1st follow-up - 6 months later - the patient remained symptoms free, and the bone density was still increasing. At the one-year follow-up, there were no clinical symptoms, and a regression of the radiographic lesion with a zone of a hard tissue-like spicules aspect at the external tooth surface could be observed. The case's positive outcome reported a proof-of-concept of the new endodontic paste at the apexification clinical situation.

### Key Learning Points:

- The present case report showed promising healing results of an experimental material at a molar apexification.
- The first clinical study that evaluated an endodontic paste with controlled drug delivery systems as an intracanal medicament.
- The controlled drug delivery of amoxicillin microspheres and indomethacin nanocapsules associated with  $\alpha$ -TCP favored the healing process and the apical barrier formation.

Felipe Barros Matoso<sup>1</sup>

Fabiana Soares Grecca<sup>1</sup>

Lucas Siqueira Pinheiro<sup>1</sup>

Vicente Castelo Branco Leitune<sup>1</sup>

Silvia Guterres<sup>2</sup>

Fabício Mezzomo Collares<sup>1\*</sup>

Patrícia Maria Poli Kopper<sup>1</sup>

<sup>1</sup>Department of conservative Dentistry, Dental School, Federal University of Rio Grande do Sul, Porto Alegre, Brazil.

<sup>2</sup>Cosmetology Laboratory, School of Pharmaceutical Sciences, Federal University of Rio Grande do Sul, Porto Alegre, RS, Brazil.

Received 2021, April 3

Accepted 2021, June 22

**KEYWORDS** apexification, drug delivery systems, knowledge translation, microspheres, nanocapsules

### Corresponding Author

Fabício Mezzomo Collares | Federal University do Rio Grande do Sul, Rua Ramiro Barcelos, 2492 – Bairro Santana, CEP 90035-003, Porto Alegre, RS | Brazil  
Phone: +55 (51) 3308-5010 | Email: [fabricao.collares@ufrgs.br](mailto:fabricao.collares@ufrgs.br)

Peer review under responsibility of Società Italiana di Endodonzia

[10.32067/GIE.2021.35.02.59](https://doi.org/10.32067/GIE.2021.35.02.59)

Società Italiana di Endodonzia. Production and hosting by Ariesdue. This is an open access article under the CC BY-NC-ND license (<http://creativecommons.org/licenses/by-nc-nd/4.0/>).



## Introduction

**I**mmature permanent teeth diagnosed with pulp necrosis present interrupted root development and incomplete apical closure. In these cases, endodontic treatment becomes a challenge due to the thin and fragile root canal walls and the root apex width (1). Using bioactive materials could promote an apical barrier leading to proliferation and differentiation of cells to achieve the root apexification (2).

Over the years, calcium hydroxide paste has been used as an intracanal medication for mature and immature teeth due to its antimicrobial effects, bioactivity, easy resorption, and absence of foreign body

reaction (3). However, it presents some shortcomings like limited anti-inflammatory effect (3), low efficiency in reducing postoperative pain (4), and not user-friendly handling. Moreover, calcium hydroxide paste needs to be changed from time to time until the apical mineralized barrier formation (5). Several new materials have been studied to improve the outcomes of immature permanent teeth treatments. Changes in hydraulic cement's composition, adding different inorganic compounds, antimicrobial agents, and anti-inflammatory drugs are the most studied modifications (6-8).

Materials presenting long-lasting antimicrobial, anti-inflammatory, and bioactive effects with drug delivery systems have

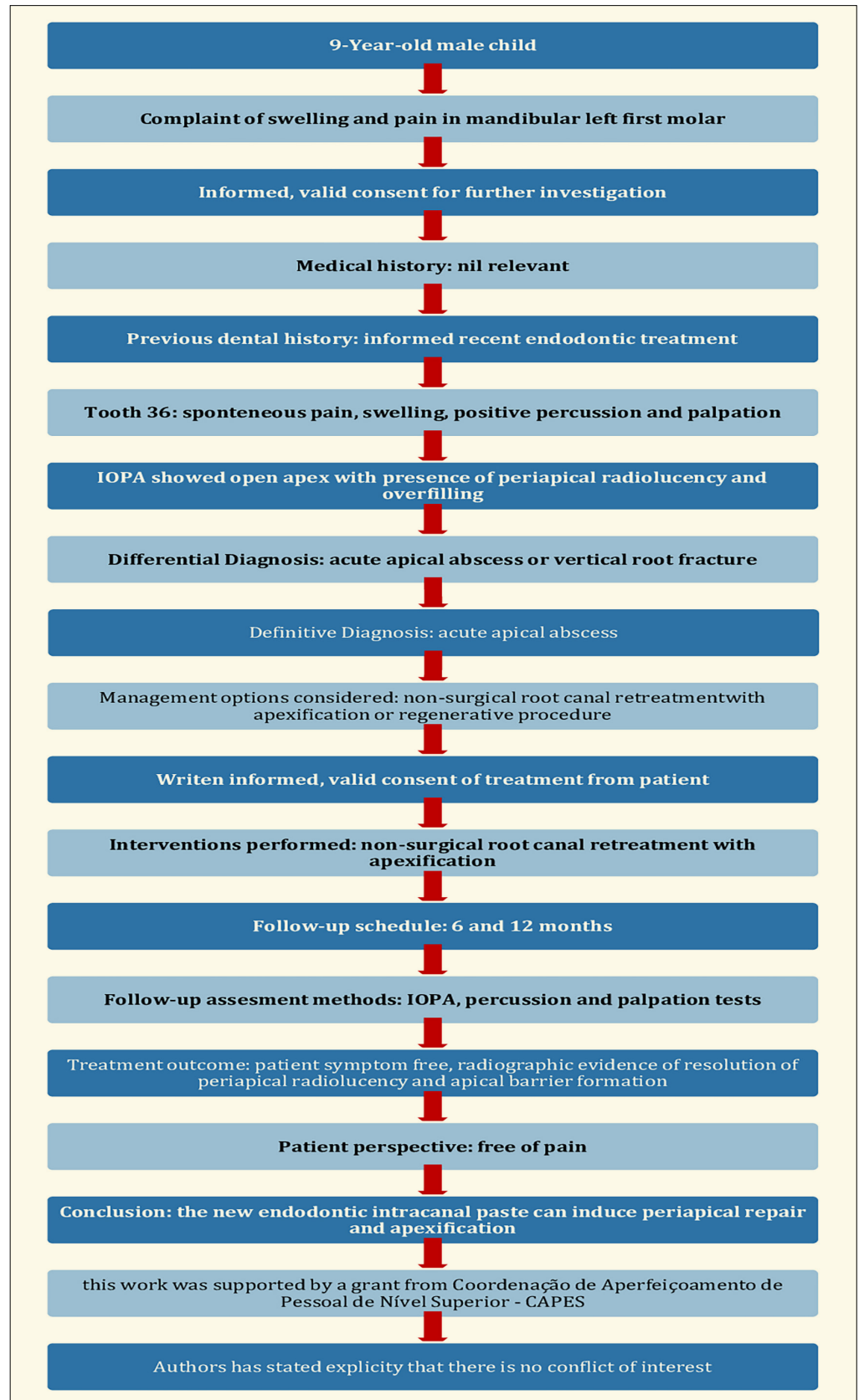
**Table 1**  
**Timeline associated with case management**

Month/Year	Appts.	Events	Clinical and radiographic characteristics
April/2019	1st	Patient visited School of Dentistry of UFRGS; Dental and medical history; Clinical and radiographic evaluation of tooth #36 (Fig. 2A); Desobturation procedure; Chemical-mechanical preparation; Intracanal endodontic paste insertion (Fig. 2B).	Clinical: spontaneous moderate pain, swelling, positive vertical/horizontal percussion and palpation.  Radiographic: unsatisfactory previous endodontic treatment with voids and overfilling, incomplete rhizogenesis and extensive radiolucent area.
September/2019	2nd	Clinical and radiographic evaluation (Fig. 2C); Root canal filling (Fig. 2D); Tooth restoration.	Clinical: symptoms free, apical barrier formation.  Radiographic: increase of bone density.
April/2020	1st follow-up	Clinical and radiographic evaluation (Fig. 2E).	Clinical: symptoms free.  Radiographic: increase of bone density.
October/2020	2nd follow-up	Clinical and radiographic evaluation (Fig. 2F).	Clinical: symptoms free.  Radiographic: increase of bone density and zone of hard tissue-like spicules aspect.

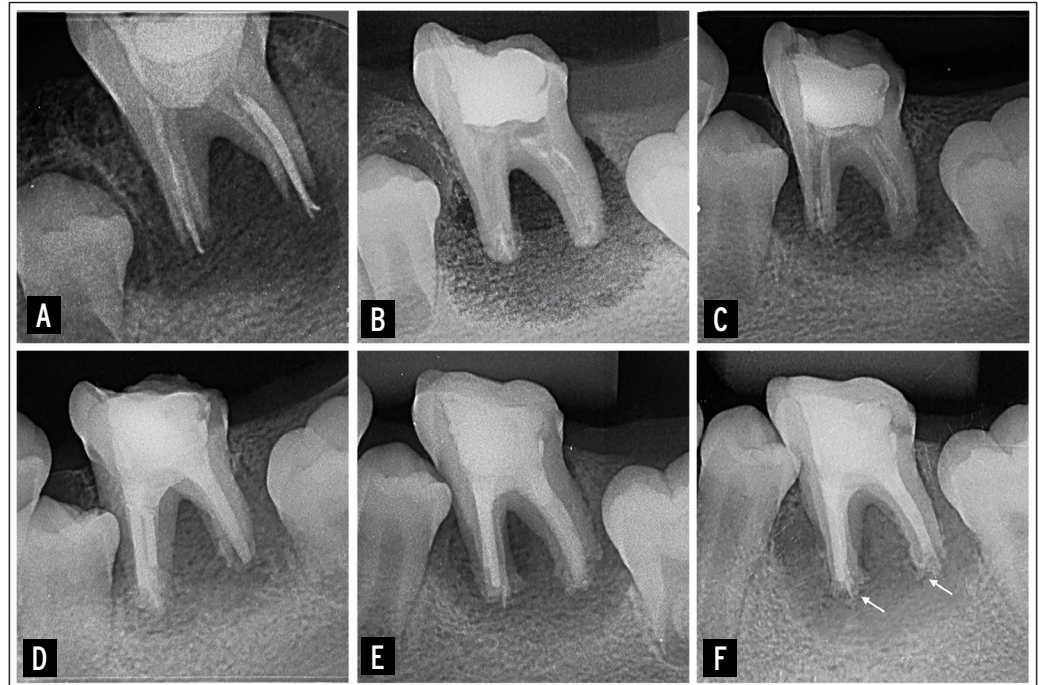
Appts.=Appointments; UFRGS, Federal University of Rio Grande do Sul.

**Figure 1**

PRICE 2020 flowchart (Nagendrababu et al. 2019, Nagendrababu et al. 2020) showing the steps involved in the case report. IOPA, intraoral periapical radiograph.



**Figure 2**  
Intra oral periapical radiographs of the case report.  
**A)** Pre-treatment, diagnosis image; **B)** Intra-treatment, endodontic paste insertion evaluation;  
**C)** Intra-treatment, demonstrating the resorption of endodontic paste at second appointment;  
**D)** Intra-treatment, final radiograph after the root canal filling; **E)** first follow-up; **F)** secondo follow-up. Hard tissue-like spicules aspect (Arrows).



been proposed (9). Recently, an endodontic paste with  $\alpha$ -tricalcium phosphate ( $\alpha$ -TCP), calcium tungstate, amoxicillin microspheres (AMX-MS), and indomethacin nanocapsules (IndOH-NC) was formulated to propose a new method of delivering active agents to regions with difficult access due to anatomical complexities present in teeth that need endodontic treatment (10). Also, this in vitro study showed reliable physicochemical properties with no cytotoxicity when tested in fibroblastic (3T3-L1) cell line, and antimicrobial activity against planktonic bacteria and *Enterococcus faecalis* (10). Further, the experimental paste induced a faster wound healing of fibroblasts than a commercially available calcium hydroxide paste (10). Although several studies showed promising results for drug carriers and bioactive materials for endodontic use, materials with combined antimicrobial, anti-inflammatory, and bioactive properties are not commercially available. After reliable laboratory results of new materials, case reports are the next step at bench-to-chair translation to clinical use. This case report presented the use of a new endodontic paste to retreat an open apex tooth diagnosed with acute periradicular abscess.

## Case report

This clinical case is reported according to Preferred Reporting Items for Case reports in Endodontics (PRICE) 2020 guidelines (11, 12). The case management timeline is summarized in table 1 and figure 1. A 9-year-old male child was referred to the School of Dentistry of the Federal University of Rio Grande do Sul in April 2019 for assessing inclusion in a randomized clinical trial (RCT) (CAAE n° 09824919.0.00005347).

The patient reported moderate spontaneous pain aggravated by mastication and swelling in the region of the left lower permanent first molar (tooth #36). There was no significant medical history. Dental history revealed previous endodontic treatment with adequate composite resin restoration in #36 performed six months before the first appointment. Extraoral examination revealed edema without floating-point on the mandibular left side with tenderness to palpation and vertical/horizontal percussion in the #36. An intraoral periapical radiograph (VistaScan Mini Easy, Dürr Dental, Germany) revealed unsatisfactory previous endodontic treatment with voids and overfilling, incom-



plete rhizogenesis, and extensive radiolucent area (Figure 2a). According to clinical and radiographic signs and symptoms, tooth #36 was diagnosed with acute periradicular abscess. After, the agreement by the child guardian and the informed consent was obtained to perform an endodontic retreatment procedure using the new endodontic paste with drug delivery systems as intracanal medication on tooth #36.

In the same appointment, under papillary anesthesia with 2% lidocaine containing 1:100,000 epinephrine (Alphacaine, DFL, Rio de Janeiro, RJ, Brazil), cavity access was performed under rubber dam isolation using a round diamond bur (No.1015; KG Sorensen, São Paulo, SP, Brazil) under water cooling until gutta-percha was visualized. Irrigation with 2.5% NaOCl (Asfer, São Caetano do Sul, SP, Brazil) was performed, and a #4 Gates Glidden Drill (Dentsply Maillefer, Ballaigues, Switzerland) was introduced into the cervical third of the root canals (distal (D), mesio-buccal (MV) and mesio-lingual (ML)).

The gutta-percha and endodontic sealer of previous treatment were removed with a Clearsonic R1 ultrasonic insert (Helse Ultrasonic, Ribeirão Preto, SP, Brazil) and 2.5% NaOCl irrigation. After that, the #60 file (Dentsply Maillefer, Ballaigues, Switzerland) was introduced into the root canals at the provisional working length (14mm) based on the diagnosis radiograph (Figure 2a), and gentle brush movements were performed on the walls. At the end of this procedure, a supplementary cleaning protocol was realized with 2.5% NaOCl solution and EasyClean instrument (Easy Dental Equipment, Belo Horizonte, Minas Gerais, Brazil) in three 20s cycles under 800rpm rotation and 200g.cm<sup>2</sup> of torque, with the renewal of the solution between each cycle. Afterward, the same procedure was performed with 17% EDTA (Fórmula & Ação, São Paulo, SP, Brazil). The root canals were then aspirated with an aspiration tip (Endo Tips, Angelus, Londrina, Paraná, Brazil) and dried with #80 absorbent paper tips (Dentsply, Petrópolis, RJ, Brazil).

The endodontic paste was prepared with

1 g of amoxicillin microspheres, 0.2 g of  $\alpha$ -TCP, 0.4 g of CaWO<sub>4</sub> (Sigma-Aldrich Chemical, Inc., St. Louis, MO, USA), and 0.4 mL of IndOH-NC suspension (10). The paste was inserted into a medium flow precision tip (Maquira, Maringá, Paraná, Brazil) adapted to a precision applicator (Maquira, Maringá, Paraná, Brazil). The set was placed in the cervical third of each root canal, and the paste was inserted. A base of temporary restorative material (Villevie, Joinville, Santa Catarina, Brazil) was performed, and for the restoration procedure, the etchant (Dentsply Sirona, Pirassununga, SP, Brazil) was applied at enamel for 15s, rinse for 15s, air-dry to remove excess water. Then, the adhesive Scotchbond Universal Adhesive (3M ESPE, St Paul, USA) brushed for 20s in enamel and dentin with vigorous agitation, gently air thin for 5s and light-cure for 10s (Radiical, SDI, Victoria, Australia). Resin composite (Filtek Z25, 3M ESPE, St Paul, MN, USA) was placed in increments to restore the cavity. Each increment was photo-activated for 20st (Figure 2B).

The patient was scheduled for a new appointment after 30 days and did not return in the combined period. Numerous attempts to contact his guardians were made, and only in September 2019, the patient returned for the second appointment. Clinically, the patient was asymptomatic, and radiographically it was observed radiolucent area regression compatible with the repair process and mineralized barrier formation in the apical portion (Figure 2C). Under rubber dam isolation, a new access activity was performed, and the paste was removed with 2.5% NaOCl solution while stirring with the EasyClean instrument in 3 cycles of 20s and 17% EDTA under the same agitation protocol. Final saline irrigation was performed, and the root canals were aspirated and dried with #80 absorbent paper tips (Dentsply Maillefer, Ballaigues, Switzerland).

Apical barrier formation was verified clinically by a #80 absorbent paper tip. With this paper point, inside the root canal, touching the barrier, the working length was determined (Distal=16 mm, Mesio-buccal=16 mm, Mesio-lingual=16 mm).



The filling was performed with MTA Fill-apex sealer (Angelus, Londrina, PR, Brazil) and gutta-percha (Dentsply, Petrópolis, RJ, Brazil) by the lateral condensation technique. Root canal orifices were sealed with Glass Ionomer Cement (Riva self-cure/SDI, Bayswater, Victoria, Australia) and coronary sealing was performed with Z250XT composite resin under the same previous protocol described (Figure 2D).

In April 2020 (after 12 months of the first appointment), the patient returned for the first follow-up. He reported no pain or swelling. Radiographically, it was observed progressive regression of lesion size with increased density of regenerated trabecular bone tissue (Figure 2E). No adverse events were reported.

The patient was recalled in October 2020 for the second follow-up visit. He remained asymptomatic without intraoral and extraoral signs of abnormality. The patient reported that he was free of pain since the end of the first appointment. Although a complete bone repair has not yet occurred, radiographically was observed a continued increase in density of the regenerated trabecular bone surrounding tooth #36. At the external surface of the apical third was observed a radiopaque zone of hard tissue-like spicules aspect (Figure 2F).

All procedures were conducted under magnification with a surgical microscope (DFVasconcelos, Valença, RJ, Brazil). Radiograph images were viewed and interpreted by two independent endodontists. The images were assessed on a 21" LED screen where image brightness and contrast could be changed using the software VistaScan (Dürr Dental, Germany).

## Discussion

This is the first clinical report assessing the use of a new endodontic paste with controlled drug delivery systems as intracanal medication describing the formation of an apical barrier of mineralized tissue after endodontic retreatment of an open apex tooth diagnosed with acute periapical abscess. This encouraging result could be related to the polymeric nanocapsules contained in the experimental paste that are

able to carry indomethacin into the inflammation sites. Moreover, the implantation of antibiotic loaded polymeric systems directly to the site of infection and consequently, lowering the amount of amoxicillin needed to achieve the desired antibacterial effect probably contributed to the infection control, favoring the apical repair.

The constant movement of the adjacent structures to the #36 tooth, which occurs due to the permanent teeth eruption process, could have impaired the #36 tooth stability, which may justify the incomplete periapical bone repair observed until the present moment. Nevertheless, the periapical lesion regression in the present case could be explained by the chemical-mechanical action of irrigant solutions, endodontic instruments, and the antimicrobial and anti-inflammatory effects of intracanal endodontic paste. Calcium hydroxide paste, routinely used in the referred clinical situation, demonstrated low effectiveness in postoperative pain control (4). Furthermore, it has been shown that dentin's buffering action can counteract the antimicrobial activity of calcium hydroxide (13). Acute endodontic infections present multispecies microbial communities, being strict anaerobes (*Porphyromonas*, *Prevotella*, and *Parvimonas*), the most frequent species isolated/detected inside the root canal (14). Moreover, *E. faecalis* bacteria, one of the most prevalent species in cases of refractory infections to endodontic treatment (15, 16), has shown resistance to medium alkalization caused by calcium hydroxide (13, 17). The experimental endodontic paste has demonstrated efficacy against *E. faecalis* and planktonic bacteria (10), probably attributed to amoxicillin delivery at the infection site (18).

Further, no pain was reported after the first intervention. Indomethacin is a non-steroidal anti-inflammatory agent inhibiting prostaglandin synthesis by reversibly blocking cyclooxygenases 1 and 2 (COX-1 and COX-2) action (19). The systemic use of oral indomethacin shows adverse intestinal and gastric effects due to the non-selective action of COX-1 and COX-2 enzymes (20). Controlled drug release could over-



come the issues related to systemic antimicrobial and anti-inflammatory administration (21).

In the present case, the new endodontic paste was able to induce mineralized tissue barrier formation, observed clinically and radiographically at the follow-up periods. Bezgin *et al.* (2012) each with at least one necrotic permanent central incisor requiring apexification treatment, were selected for this study. Twenty-two selected teeth were divided into two test groups (10 CHP and 12 CHPP (22) observed an average of 11 months for mineralized tissue barrier formation in teeth diagnosed with acute periradicular abscess treated with calcium hydroxide-based medication. In this case report, at the second appointment (5 months after filling the root canal with the paste), a mineralized barrier formation at the apex was observed. The formed apical barrier could be explained by the antimicrobial and anti-inflammatory action associated with a bioactive calcium phosphate filler (10). Further, alfa-TCP influences fibroblast cell migration, differentiation, and proliferation of mineralized tissue producing cells, favoring the healing process and repair of periradicular tissues (9, 23).

These parameters may suggest an apexification process induced by the new intracanal endodontic paste. An apical barrier is required to avoid bacteria and its toxins from the root canal into the periradicular tissue and act as a base preventing root canal filling extrusion (24). Besides the mineralized barrier induction, at the last follow-up appointment, was observed a radiopaque zone in spicules aspect at the external apical third surface (figure 2F) which differs radiographically from the image observed when MTA or calcium hydroxide paste are used for the apexification process (2, 25). However, to be sure regarding the type of tissue formed, a histological evaluation should be performed.

A possible limitation of this case report was the lack of standardization of the diagnosis radiography as the patient had pain while chewing, precluding the use of a positioner device. However, without

pain, the subsequent radiographs were standardized enabling follow-up. Besides the absence of standardization of the first image, a mineralized barrier and the lesion regression could be observed.

Several new materials are developed in recent years to increase the clinical outcomes of endodontic treatments. However, the translation of bench results to the chair-side does not follow the same speed. The literature shows that a breakthrough discovery could take about 17 years to be incorporated into the clinical routine (26, 27). To overcome this issue, new materials screen in vitro and translation to clinical condition is of paramount importance. In this way, the knowledge translation of the state-of-the-art research to the standard of care could enhance clinical outcomes. Although case reports are the first line of evidence in oral health and randomized clinical studies are necessary, the use of a new endodontic paste with reliable in vitro results was translated to clinical application with promising outcomes, shedding light on immature permanent teeth treatment.

## Conclusions

The case outcome showed that the paste might be an efficient alternative to conventional apexification materials.

## Clinical Relevance

The use of a new endodontic paste with controlled drug delivery system could be used for apexification in immature teeth.

## Conflict of Interest

The authors declares that there is no conflict of interest.

## Acknowledgements

Supported by grants from Coordenação de Aperfeiçoamento de Pessoal de Nível Superior – CAPES – Finance code 001.

## References

- 1 Chala S, Abouqal R, Rida S. Apexification of imma-



- ture teeth with calcium hydroxide or mineral trioxide aggregate: systematic review and meta-analysis. *Oral Surg, Oral Med, Oral Pathol, Oral Radiol, and Endod.* 2011;112:36-42.
- 2 Kandemir DG, Kaval ME, Güneri P, et al. Treatment of immature teeth with nonvital pulps in adults: a prospective comparative clinical study comparing MTA with Ca(OH)<sub>2</sub>. *Int Endod J.* 2020;53:5-18.
  - 3 Srinivasan V, Patchett CL, Waterhouse PJ. Is There life after buckley's formocresol? Part I - A narrative review of alternative interventions and materials. *Int J of Paed Dent.* 2006;16:117-27.
  - 4 Anjaneyulu K, Nivedhitha MS. Influence of calcium hydroxide on the post-treatment pain in endodontics: a systematic review. *J of Conserv Dent.* 2014;17:200-7.
  - 5 Staffoli S, Plotino G, Torrijos BGN, et al. Regenerative endodontic procedures using contemporary endodontic materials. *Materials* 2019;12:1-28.
  - 6 Kogan P, Jianing H, Glickman GN et al. The effects of various additives on setting properties of MTA. *J Endod.* 2006;32:569-72.
  - 7 Duarte MAH, Alves de Aguiar K, Zeferino MA et al. Evaluation of the propylene glycol association on some physical and chemical properties of mineral trioxide aggregate. *Int Endod J.* 2012;45:565-70.
  - 8 Koutroulis A, Batchelor H, Kuehne SA et al. Investigation of the effect of the water to powder ratio on hydraulic cement properties. *Dent Mat.* 2019;35:1146-54.
  - 9 Dornelles NB, Collares FM, Genari B et al. influence of the addition of microsphere load amoxicillin in the physical, chemical and biological properties of an experimental endodontic sealer. *J Dent.* 2018;68:28-33.
  - 10 Cuppini M, Zatta KC, Mestieri LB et al. Antimicrobial and anti-inflammatory drug-delivery systems at endodontic reparative material: synthesis and characterization. *Dent Mat.* 2019;35:457-67.
  - 11 Nagendrababu V, Chong BS, McCabe P et al. Guidelines for reporting the quality of clinical case reports in Endodontics: a development protocol. *Int Endod J.* 2019;52:775-78.
  - 12 Nagendrababu V, Chong BS, McCabe P et al. PRICE 2020 guidelines for reporting case reports in Endodontics: explanation and elaboration. *Int Endod J.* 2020;53:922-47.
  - 13 Kayaoglu G, Erten H, Bodrumlu E et al. The resistance of collagen-associated, planktonic cells of enterococcus faecalis to calcium hydroxide. *J Endod.* 2009;35:46-9.
  - 14 Montagner F, Jacinto RC, Signoretti FGC et al. Clustering behavior in microbial communities from acute endodontic infections. *J Endod.* 2012;38:158-62.
  - 15 Siqueira JF, Rôças IN. Polymerase chain reaction-based analysis of microorganisms associated with failed endodontic treatment. *Oral Surg, Oral Med, Oral Pathol, Oral Radiol, and Endod.* 2004;97:85-94.
  - 16 Gomes BPPA, Pinheiro ET, Jacinto RC et al. Microbial analysis of canals of root-filled teeth with periapical lesions using polymerase chain reaction. *J Endod.* 2008;34:537-40.
  - 17 Ma J, Tong Z, Ling J et al. The effects of sodium hypochlorite and chlorhexidine irrigants on the antibacterial activities of alkaline media against enterococcus faecalis. *Arch Oral Biol.* 2015;60:1075-81.
  - 18 Bernardi A, Zilberstein AACCV, Jäger E et al. Effects of indomethacin-loaded nanocapsules in experimental models of inflammation in rats. *Brit J Pharmacol.* 2009;158:1104-11.
  - 19 Summ O, Evers S. Mechanism of action of indomethacin in indomethacin-responsive headaches. *Cur Pain and Head Rep.* 2013;17:1-8.
  - 20 Chen MR, Dragoo JL. The effect of nonsteroidal anti-inflammatory drugs on tissue healing. *Knee Surg, Sports Traumatol, Arthroscopy.* 2013;21:540-49.
  - 21 Mahmoudian M, Ganji F. Vancomycin-loaded HPMC microparticles embedded within injectable thermosensitive chitosan hydrogels. *Progr Biomat.* 2017;6:49-56
  - 22 Bezgin T, Sönmez H, Orhan K et al. Comparative evaluation of Ca(OH)<sub>2</sub> plus points and Ca(OH)<sub>2</sub> paste in apexification. *Dent Traumatol.* 2012;28:488-95.
  - 23 Tanomaru-Filho M, Andrade AS, Rodrigues EM et al. Biocompatibility and mineralized nodule formation of Neo MTA Plus and an experimental tricalcium silicate cement containing tantalum oxide. *Int Endod J.* 2017;50:31-9.
  - 24 Simon S, Rilliard F, Berald A et al. The use of mineral trioxide aggregate in one-visit apexification treatment: a prospective study. *Int Endod J.* 2007;40:186-97.
  - 25 Songtrakul K, Azarpajouh T, Malek M et al. Modified apexification procedure for immature permanent teeth with a necrotic pulp/apical periodontitis: a case series. *J Endod.* 2020;46:116-23.
  - 26 Contopoulos-Ioannidis DG, Alexiou GA, Gouvias TC et al. Life cycle of translational research. *Science* 2008;321:1298-99.
  - 27 Heft MW, Fox CH, Duncan RP. Assessing the translation of research and innovation into dental practice. *JDR Clin Transl Res.* 2020;5:262-70.