

CASE REPORT

Endodontic management on a C-shaped mandibular molar fused with a supernumerary tooth: a report of a rare case

ABSTRACT

Aim: Fusions involving mandibular molars and supernumerary teeth are rarely reported. The complex internal anatomy makes the endodontic treatment of these teeth a challenge for the clinician. This report describes the endodontic management of a rare case of a C-shaped mandibular molar fused with a supernumerary tooth.

Summary: A 29-year-old male was referred for endodontic treatment of the right mandibular second molar. The initial clinical examination indicated atypical anatomy of this tooth, with the presence of a “supernumerary cusp”. Cone-beam computed tomography (CBCT) images showed that the cusp was a supernumerary tooth, with its canal separated in the cervical third, but fused in the apical third to the second molar canals, forming a single C-shaped canal. After clinical and radiographic examination, the diagnosis was irreversible pulpitis. The endodontic treatment was performed with the aid of a dental operating microscope. The root canals were instrumented using the crown-down technique and irrigation using 2.5% sodium hypochlorite (NaOCl). Passive ultrasonic irrigation was performed (2.5% NaOCl and 17% EDTA solutions) followed by obturation using the thermoplasticization technique. No clinical or radiographic changes were noted at the 12- and 24-month follow-up visits.

Key-learning points:

- The analysis of CBCT images and the use of magnifying tools are essential for the diagnosis and treatment of teeth with complex root canal anatomy.
- For teeth with complex anatomies, in addition to the traditional methods of root canal shaping and filling, it is necessary to associate methods that enhance the cleaning and disinfection of the root canal system.

Filipe Colombo Vitali¹Braulio Pasternak-Junior²Ihan Vitor Cardoso¹Cleonice da Silveira Teixeira^{1*}

¹Department of Dentistry, Endodontics Division, Federal University of Santa Catarina, Florianopolis, Brazil.

²Private Practice, Florianopolis, Brazil.

Received 2022, June 27

Accepted 2022, September 28

KEYWORDS Case report, C-shaped root canal, dental morphologic anomaly, dental morphology, mandibular molar.

Corresponding Author

Professor Cleonice da Silveira Teixeira | Department of Dentistry, Endodontics Division, Federal University of Santa Catarina, Florianopolis | Brazil.
Email: cleotex@uol.com.br, Phone +55 (048) 3721-5840; +55 (048) 3721-9520

Peer review under responsibility of Società Italiana di Endodonzia

[10.32067/GIE.2022.36.02.11](https://doi.org/10.32067/GIE.2022.36.02.11)

Società Italiana di Endodonzia. Production and hosting by Ariesdue. This is an open access article under the CC BY-NC-ND license (<http://creativecommons.org/licenses/by-nc-nd/4.0/>).



Introduction

The success of endodontic therapy depends on adequate debridement and filling of the root canal system (1). Clinicians need to have adequate knowledge about the morphology of the root canal and its possible variations to achieve satisfactory outcomes in endodontic treatments (1, 2). The presence of unusual and complex variations in root canal morphology may contribute to unsuccessful treatment since it can make it difficult to locate and negotiate the canals, as well as their subsequent management (1).

The C-shaped root canal system is an anatomical anomaly with a cross-sectional shape similar to the letter 'C' (2). Its configuration has a higher prevalence in mandibular second molars and is rarely related to other teeth, such as premolars, mandibular first or third molars, and maxillary molars (2, 3). The prevalence ranges from 2.7 to 55% in different ethnicity, with higher values in oriental populations (3). C-shaped root canal anatomy may vary along the root length, with individual canals that have a kind of fin or net connecting them (4). In addition, the canal walls may be of different thicknesses, in which the lingual wall is generally thinner (4). Due to the peculiarities of its clinical characteristics, this anatomical configuration may present challenges in cleaning, shaping, and filling of the root canal (1, 4). The etiology of supernumerary teeth is still not entirely clear (5). Hyperactivity of the dental lamina, heredity, and association with syndromes are factors that have been extensively investigated (5). These teeth can differ in number or morphology and occur anywhere in the dental arch, as well as can be fused to permanent teeth, most commonly in the anterior region of the maxilla (5). However, fusions involving supernumerary teeth with mandibular molars are rarely reported in the literature (6). These fusions can be partial or total, depending on the stage of development of the teeth at the time of union (7). Fused teeth usually have independent root canals with combined dentinal walls (8). If these

teeth have endodontic involvement, their treatment becomes a challenge for the clinician (6, 7).

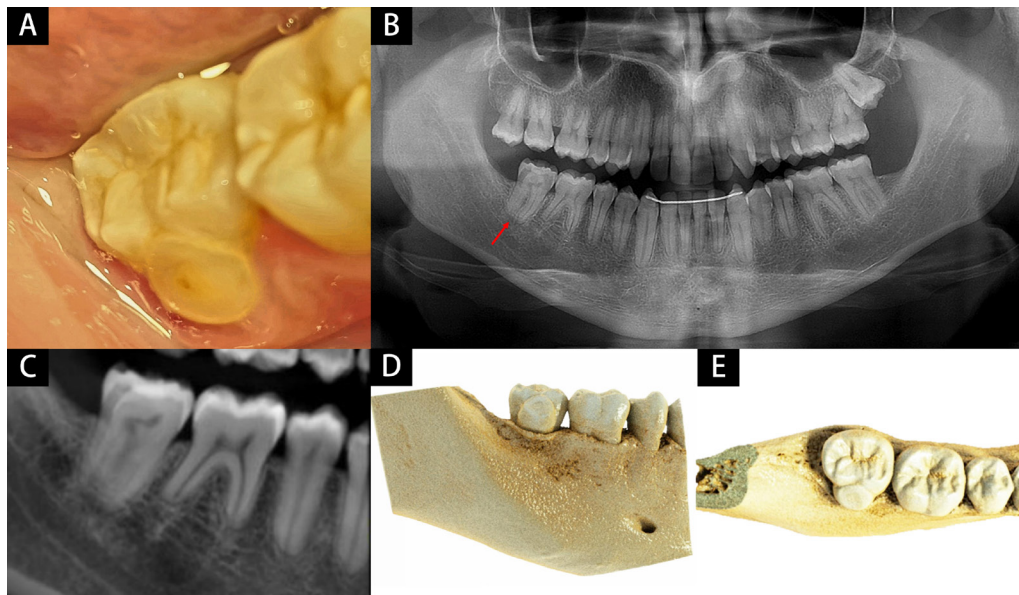
According to the American Association of Endodontists, cone beam computed tomography (CBCT) should be considered the imaging modality of choice for endodontic treatment of teeth with potential suspicion of complex morphology (3, 9). In cases of C-shaped root canals or fused teeth, CBCT facilitates and improves the understanding of the root canal morphology, as it provides a three-dimensional image of the same (3, 9). In addition, the use of magnifying tools for endodontic therapy, such as the dental operating microscope, can increase the effectiveness and precision of treatment, especially in teeth that have some particular anatomical complexity (10). Therefore, the present case report describes the endodontic management of a C-shaped root canal in the mandibular second molar fused with a supernumerary tooth, with the guidance of a CBCT image and the use of a dental operating microscope.

Report

A 29-year-old Caucasian man, in generally good health (ASA I), was referred by another clinician for endodontic treatment. The patient was complaining about spontaneous, intense, and localized pain in the lower right second molar, which started two days earlier. In an intraoral examination, the tooth presented an atypical supernumerary cusp fused by a buccal surface (Figure 1A), was free of cavities or restorations, probing depth was within normal limits (less than 3 mm) and no pathologic tooth mobility was observed. It showed a mild response to percussion/palpation and pain was exacerbated when the cold test (Roeko Endo-Frost; Coltene, Langenau, Germany) was performed. It was observed an abrasion lesion in the supernumerary cusp (Figure 1A). Also, the patient came in possession of panoramic radiography (Figure 1B) and a CBCT of the mandible, with section thickness (voxel) of 0.099 mm and 0% distortion in axial and transversal (parasagittal) sections, and 3D, sagittal, coronal, axial and transversal

Figure 1

A) Clinical image before endodontic treatment: atypical supernumerary cusp fused with the mandibular second molar by buccal surface. **B)** Panoramic radiograph: red arrow indicating the tooth to be treated. **C)** CBCT periapical reconstruction. **D, E)** CBCT 3D reconstructions: **D)** buccal and **E)** occlusal views.



reconstructions. At tomography and 3D reconstructions evaluation, it was noticed that the 'atypical supernumerary cusp' was a supernumerary tooth characterized by increased height and reduced mesiodistal width. It was also realized that the supernumerary canal was separated in the cervical third (Figure 2AB), but fused in the middle (Figure 2CD), and apical thirds (Figure 2EF) to the second molar canals, forming a single C-shaped canal in the buccal direction. According to a previous study,(11) isthmuses in root cross-sections were classified as type III (incomplete isthmus existing above and/or below a complete isthmus). Considering clinical and radiographic findings, the diagnosis was irreversible pulpitis and endodontic treatment of the tooth was proposed. An informed consent form was obtained from the patient, to perform the endodontic intervention.

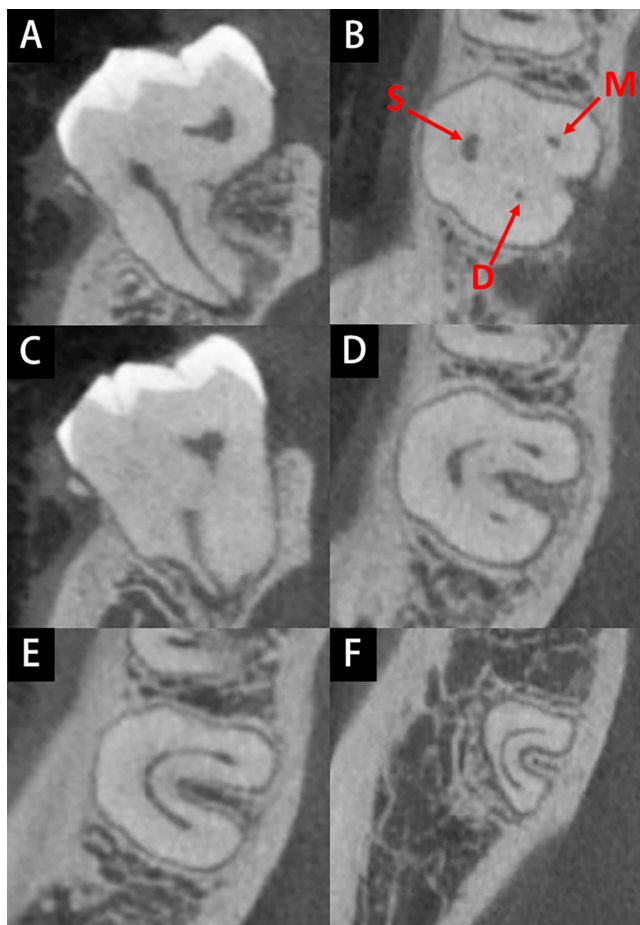
After the right lower alveolar and buccal nerve block (2% mepivacaine with 1:100.000 epinephrine [DFL, Taquara, Brazil]), isolation with a rubber dam was performed and secured with liquid dam material (Top Dam; FGM, Joinville, Brazil). Then, all treatment was conducted under operative microscopy (MC-M3101; DF Vasconcellos, Valença, Brazil). Initially, coronary access was performed in the center of the occlusal surface of the second

molar with a high-speed diamond bur (#1014; KG Sorensen, Cotia, Brazil), primarily to access the mesial and distal canals. As it was not possible to locate the supernumerary canal, another access was made in the center of the occlusal surface of the supernumerary cusp (Figure 3A). A size 10 K-file (Dentsply Maillefer, Tulsa, USA) was introduced into the root canals, under copious irrigation with 2.5% sodium hypochlorite (NaOCl) solution to ensure patency. Next, the canals were measured with an electronic apex locator (Root ZX II; J Morita, Kyoto, Japan) and the working length (WL) was established in the apical foramen.

Then, the root canals were prepared with the Reciproc Blue R25 instrument (#25/0.08; VDW GmbH, Munich, Germany), according to the manufacturer's instructions. At each removal of the instrument for cleaning, the root canals were irrigated with 2 mL of 2.5% NaOCl with the aid of a NaviTip 30-G tip (Ultradent Products Inc, South Jordan, USA) coupled to a 5-mL syringe. After preparation, passive ultrasonic irrigation (PUI) was performed in all root canal system with the aid of an ultrasonic tip (E1 Irrisonic; Helse Ultrasonic, São Paulo, Brazil), alternating 2.5% NaOCl and 17% ethylenediaminetetraacetic acid (EDTA) solution. At this time, the patient complained of intense pain in the tempo-



Figure 2
 CBCT images. **A)** Transversal section: supernumerary canal separated from the second molar canals in the cervical third. **B)** Axial cervical section: individual mesial (M), distal (D) and supernumerary (S) canals. **C)** Transversal section: supernumerary and second molar canals fused in the middle third. **D)** Axial middle section: supernumerary, mesial and distal canals fused forming a single C-shaped canal. **E, F)** Axial apical sections showing a single C-shaped canal.



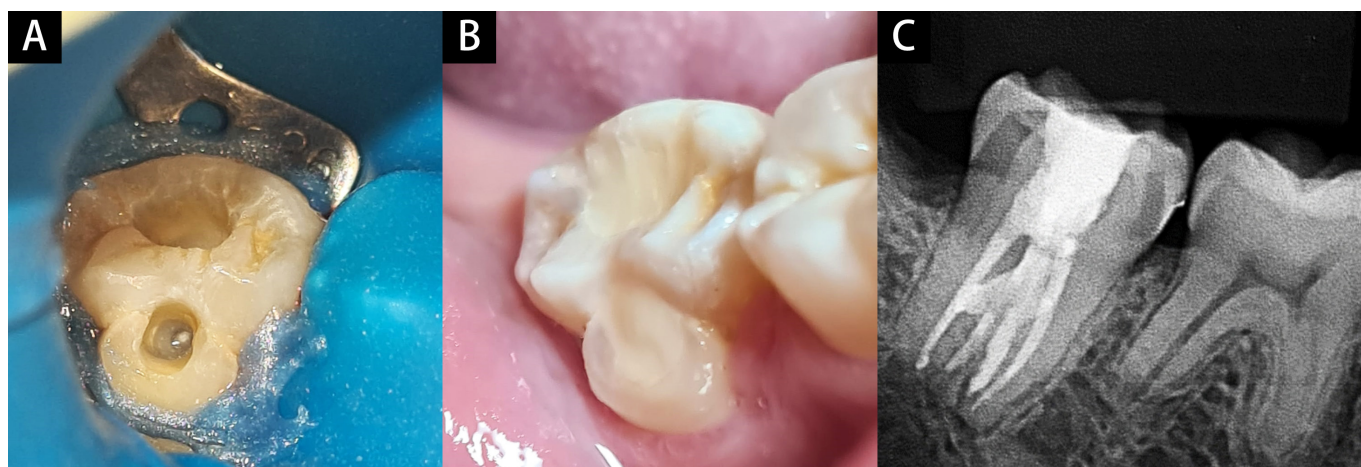
paper points (R25; VDW GmbH, Munich, Germany), and a calcium hydroxide (CH) intracanal dressing (Ultracal XS; Ultradent, South Jordan, USA) was placed (12). After a digital periapical radiograph to confirm the complete filling of the root canals by the CH dressing, the access cavities were sealed with a light-curing, ready-to-use, glass ionomer composite cement (Iono-seal; Voco, Cuxhaven, Germany).

Two weeks later, the patient returned without symptomatology and a second intervention was carried out. After the initial procedures (anesthesia and tooth isolation with a rubber dam), the temporary restorations were removed from the access cavities with a high-speed diamond bur (#1014). To remove de CH paste from the root canals, a copious amount of 2.5% NaO-Cl solution was activated using an ultrasonic tip (E1 Irrisonic). Next, the canals were dried with absorbent paper points (R25) and obturated with AH Plus sealer (Dentsply Sirona, Tulsa, USA) and gutta-percha cones (R25; VDW GmbH, Munich, Germany). First, the gutta-percha cones were selected and locked 1 mm below the WL. After, the

Figure 3
A) Clinical image during endodontic treatment. Two access cavities were performed: traditional access in the center of the occlusal surface, and in the center of the occlusal surface of the supernumerary cusp to locate the supernumerary canal. **B)** Clinical image after endodontic treatment showing both access cavities restored. **C)** Final periapical radiograph.

romandibular joint and requested that the treatment be stopped. Despite being a diagnosis of irreversible pulpitis, the treatment had to be conducted in two sessions, seeking to respect the patient's request and his joint pain threshold. Therefore, the root canals were dried with sterile absorbent

romandibular joint and requested that the treatment be stopped. Despite being a diagnosis of irreversible pulpitis, the treatment had to be conducted in two sessions, seeking to respect the patient's request and his joint pain threshold. Therefore, the root canals were dried with sterile absorbent



selected cones were coated with AH Plus sealer and cemented into root canals. The filling material was thermoplasticized using a McSpadden condenser (#55; Dentsply Maillefer, Tulsa, USA) activated in a clockwise direction, until it reached 5 mm above the WL. Then, the vertical compaction was performed by a manual gutta-percha condenser (#1-4; Odous de Deus, Belo Horizonte, Brazil), and the excess of gutta-percha was removed up to 1mm below the cemento-enamel junction. Next, the access cavities were restored with a double seal using glass ionomer cement (Ionoseal) and composite resin (Z250 Filtek; 3M, Saint Paul, USA). After checking the functional occlusion of the tooth, the final periapical radiograph was performed (Figure 3B).

The radiographic and clinical review were performed after 1 month, and the absence of signs and symptoms related to this tooth was verified. The follow-up visits at 12 and 24 months showed no radiographic or clinical changes and the patient was symptom-free.

Discussion

The anatomical variability of root canal morphology is an ongoing challenge for diagnosis and endodontic therapy (6, 7). The presence of a C-shaped canal makes it difficult for the clinician to diagnose, prepare, clean and fill the root canals (1). In the present case, fusion with a supernumerary tooth made the stages of endodontic treatment even more difficult. To date, there are no cases in the literature that report endodontic management of a C-shaped mandibular molar fused with a supernumerary tooth.

The diagnosis in cases of C-shaped canals in molars can be complex, mainly due to its peculiar anatomy (4). This report describes a case of irreversible pulpitis in a healthy second mandibular molar with a C-shaped canal system and fused with a supernumerary tooth. Even in healthy teeth, infection of the pulp tissue can occur if there is a pathway for bacteria to access the pulp cavity (13). This is possible in the presence of traumatic events, which

may have caused cracks or fractures, or due to anatomical changes, such as the presence of fusion gaps between the tooth and the supernumerary, as in the present case (13). Thus, microorganisms can invade the non-exposed dental pulp through the dentinal tubules, leading to pulpitis (14, 15). In addition, the patient's age may have been a factor that also influenced the rate of bacterial invasion of dentinal tubules (16). According to Kakoli et al. (16), there is a direct influence of age on bacterial tubular invasion, in which bacterial infection of dentinal tubules occurs to a greater extent and more rapidly in young patients when compared to elderly patients. Therefore, the presence of cracks or union gaps in enamel are areas that require supervision by the clinician, especially in young patients.

Although periapical radiographs are essential for diagnosis and planning in endodontics, two-dimensional images provide more limited information, and CBCT may be helpful in more complex cases (9). The CBCT image is a resource for the clinician, as it allows three-dimensional visualization of the anatomy of the teeth, providing a more detailed view, which can affect the treatment recommendations (9). In the present case, the three-dimensional image was essential, mainly due to the peculiar anatomy of the C-shaped canal fused to a supernumerary tooth. In addition, new strategies implemented recently can contribute the clinician overcome the difficulties that anatomical complexities can present to treatment - such the computer-aided dynamic navigation technology (17, 18). The potential of this technique is to guide the coronary access and location of the orifices of the root canals in teeth with a modified position due to anatomical alterations (17); a recent study (18) showed that the use of dynamic navigation is accurate for this proposal. Thus, the use of CBCT images and a dynamic navigation system can allow better understanding and interpretation of complex anatomical structures, benefiting the management of the case, optimizing the treatment outcome, and providing greater comfort to the patient.



In the present case, the supernumerary canal was separated from the second molar canal system in the cervical third, but merged in the middle and apical thirds, forming a single C-shaped canal in the buccal direction. The understanding and visualization of the complex anatomy of this network of root canals were facilitated with the use of magnifying tools – such as the microscope. The use of the dental operating microscope in endodontic practice has become common since the early 1990s (10, 19). According to Kersten et al. (19), the use of the operating microscope in endodontics increased from 52% in 1999 to 90% in 2007. There are several benefits of its use in endodontic procedures: it facilitates the access and location of the canal orifices, favors the detection of fracture lines, improves the surgical technique, and increases the ability to examine, model, and clean root canals, especially in more complex cases, such as C-shaped root canal anatomy (10).

In a C-shaped root canal preparation, special attention should be paid to the 'isthmus', 'trough', and 'fin', which may contain remnants of pulp tissue and can serve as a bacterial reservoir for future infections (20). Due to these particular anatomical features, cleaning, and shaping these root canals are challenging for the clinician (1). In an *ex vivo* study, the Reciproc Blue file was associated with large percentages of untouched canal walls after preparing C-shaped canals in mandibular molars (1), which makes irrigation an essential step in the endodontic treatment of these teeth, as it allows cleaning beyond of instruments from the untouched areas of the root canal (21). However, dentin tissue debris may also be present on the isthmus and fins during instrumentation (1). Results of previous studies have revealed that the accumulation of dentin debris occurred in all samples of C-shaped canals, regardless of the file system used for the preparation (1, 22). This accumulated debris can compromise the efficiency of irrigation, intracanal dressing, and the sealing provided by the filling (23, 24). Therefore, in this present case report, the PUI was proposed to activate NaOCl and

EDTA solutions and also to remove the CH dressing.

The effectiveness of the PUI can be attributed to the production of acoustic micro-waves, cavitation, and heat generation (22, 25). PUI has been encouraged to optimize different stages of endodontic treatment (25). Previous studies have reported that the ultrasonic activation of irrigating solutions significantly reduces the debris accumulation within the C-shaped canals, favoring the cleaning of areas inaccessible to the instrumentation and leaving the free space to receive the filling materials, favoring a better seal (22, 25). In addition, PUI has been reported to optimize smear layer removal, especially in the apical third, and the removal of dressings from the root canals (25). Pabel and Hulsmann (25) demonstrated that the highest efficacy in removing the CH dressing from the root canal walls resulted from the use of ultrasonic methods, such as PUI.

Another challenge in the endodontic treatment of C-shaped canals refers to the filling process (26, 27). The absence of three-dimensional filling in the critical areas of the C-shaped canals, as in ribbon-shaped communications, must invariably lead to a greater degree of bacterial microleakage (20, 26). Based on the anatomical complexities of C-shaped canals, the use of thermoplasticized gutta-percha filling techniques has been defended, in which the softened gutta-percha compaction should fill the root canal irregularities (26, 27). In the present case report, we performed the thermoplasticization of gutta-percha cones using a McSpadden condenser, obtaining a satisfactory final result.

Traditionally, root canal obturation is performed using gutta-percha and sealer (28). Currently, there is a trend for endodontic professionals to use resin-based epoxy sealers associated with the warm obturation technique (29). However, the use of thermoplasticized gutta-percha filling techniques should be performed with caution by clinicians, as prolonged use of the compactor can promote apical extrusion of the filling material and exaggerated heating of the sealer (26, 28). Soo et al. (26) demonstrated that the apical



portion of the C-shaped canal proved to be the most difficult part of achieving an adequate filling without material overflow. In addition, the heat generated using thermoplasticization can affect the physico-chemical properties of epoxy resin-based sealers (28). A recent study (28) demonstrated that heating AH Plus for 10 or 30 seconds fastened the setting process and decreased its viscosity. However, for this heating time, these changes were considered minor and AH Plus appeared to be a suitable cement for use at high temperatures (28).

Endodontically treated teeth have a higher risk of mechanical failure than sound teeth (30, 31). This can be attributed to the loss of coronal or root structure due to endodontic access or preparation (31). In the present case, direct resin restoration was the treatment performed due to the conservative approach in the coronal access cavities. However, the access cavity preparation by itself tends to compromise the mechanical integrity provided by the sound tooth and allows greater tooth flexion during function, which can result in the fracture of the endodontically treated tooth (31). In the present report, the final restoration was performed consecutively with the endodontic treatment. Despite the double seal using glass ionomer cement, this is usually not recommended due to the long setting time of the AH Plus and can be highlighted as a potential limitation of this case.

Conclusion

Although anatomical variations of root canals are rare, their importance cannot be underestimated, as they can influence the prognosis of individual cases. C-shaped root canal fused with a supernumerary tooth is an anatomically rare condition that demands appropriate management. The use of CBCT imaging and magnifying tools are essential for the diagnosis and understanding of this root anatomy. For these teeth, in addition to the traditional methods of root canal shaping and filling, it is necessary to associate techniques that enhance the cleaning and disinfection,

such as ultrasonic activation of the irrigating solution, and better sealing of the root canal system, such as gutta-percha thermoplasticization.

Clinical Relevance

Clinicians need to know and manage anatomical anomalies, such as C-shaped root canals. In the treatment of a fused tooth with C-shaped canals, preoperative analysis of CBCT scans associated with magnifying tools, and appropriate endodontic techniques can lead to favorable outcomes.

Conflict of Interest

The authors deny any conflicts of interest related to this study.

Acknowledgments

None.

References

- 1 Zhao Y, Fan W, Xu T, Tay FR, Gutmann JL, Fan B. Evaluation of several instrumentation techniques and irrigation methods on the percentage of untouched canal wall and accumulated dentine debris in C-shaped canals. *Int Endod J.* 2019;52(9):1354-65.
- 2 Sert S, Aslanalp V, Tanalp J. Investigation of the root canal configurations of mandibular permanent teeth in the Turkish population. *Int Endod J.* 2004;37(7):494-9.
- 3 Shemesh A, Levin A, Katzenell V, Itzhak JB, Levinson O, Avraham Z, et al. C-shaped canals-prevalence and root canal configuration by cone beam computed tomography evaluation in first and second mandibular molars-a cross-sectional study. *Clin Oral Investig.* 2017;21(6):2039-44.
- 4 Amoroso-Silva PA, Ordinola-Zapata R, Duarte MA, Gutmann JL, del Carpio-Perochena A, Bramante CM, et al. Micro-computed tomographic analysis of mandibular second molars with c-shaped root canals. *J Endod.* 2015;41(6):890-5.
- 5 Anthonappa RP, King NM, Rabie AB. Aetiology of supernumerary teeth: a literature review. *Eur Arch Paediatr Dent.* 2013;14(5):279-88.
- 6 Zhu M, Liu C, Ren S, Lin Z, Miao L, Sun W. Fusion of a supernumerary tooth to right mandibular second molar: a case report and literature review. *Int J Clin Exp Med.* 2015;8(8):11890-5.
- 7 Ley AM, Viana FLP, Cruz SML, Vasconcelos BC. Fused tooth: clinical approach to endodontic treatment. *Gen Dent.* 2019;67(6):59-61.
- 8 Ahmed HMA, Dummer PMH. A new system for classifying tooth, root and canal anomalies. *Int Endod J.* 2018;51(4):389-404.
- 9 Lo Giudice R, Nicita F, Puleio F, Alibrandi A, Cervino



- G, Lizio AS, et al. Accuracy of periapical radiography and CBCT in endodontic evaluation. *Int J Dent*. 2018;2018:2514243.
- 10 Al Shaikhly B, Harrel SK, Umoren M, Augsburg RA, Jalali P. Comparison of a dental operating microscope and high-resolution videoscope for endodontic procedures. *J Endod*. 2020;46(5):688-93.
 - 11 Fan B, Pan Y, Gao Y, Fang F, Wu Q, Gutmann JL. Three-dimensional morphologic analysis of isthmuses in the mesial roots of mandibular molars. *J Endod*. 2010;36(11):1866-9.
 - 12 Mohammadi Z, Dummer PM. Properties and applications of calcium hydroxide in endodontics and dental traumatology. *Int Endod J*. 2011;44(8):697-730.
 - 13 Abbott PV. Diagnosis and management of transverse root fractures. *Dent Traumatol*. 2019;35(6):333-47.
 - 14 Zheng J, Wu Z, Niu K, Xie Y, Hu X, Fu J, et al. Microbiome of deep dentinal caries from reversible pulpitis to irreversible pulpitis. *J Endod*. 2019;45(3):302-9.e1.
 - 15 Love RM, Jenkinson HF. Invasion of dentinal tubules by oral bacteria. *Crit Rev Oral Biol Med*. 2002;13(2):171-83.
 - 16 Kakoli P, Nandakumar R, Romberg E, Arola D, Fouad AF. The effect of age on bacterial penetration of radicular dentin. *J Endod*. 2009;35(1):78-81.
 - 17 Pirani C, Spinelli A, Marchetti C, Gandolfi MG, Zamparini F, Prati C, et al. Use of dynamic navigation for a minimal invasive finding of root canals: a technical note. *G Ital Endod*. 2020;34(1).
 - 18 Torres A, Boelen GJ, Lambrechts P, Pedano MS, Jacobs R. Dynamic navigation: a laboratory study on the accuracy and potential use of guided root canal treatment. *Int Endod J*. 2021;54(9):1659-67.
 - 19 Kersten DD, Mines P, Sweet M. Use of the microscope in endodontics: results of a questionnaire. *J Endod*. 2008;34(7):804-7.
 - 20 Kato A, Ziegler A, Higuchi N, Nakata K, Nakamura H, Ohno N. Aetiology, incidence and morphology of the C-shaped root canal system and its impact on clinical endodontics. *Int Endod J*. 2014;47(11):1012-33.
 - 21 van der Sluis LW, Versluis M, Wu MK, Wesselink PR. Passive ultrasonic irrigation of the root canal: a review of the literature. *Int Endod J*. 2007;40(6):415-26.
 - 22 Lee SJ, Wu MK, Wesselink PR. The effectiveness of syringe irrigation and ultrasonics to remove debris from simulated irregularities within prepared root canal walls. *Int Endod J*. 2004;37(10):672-8.
 - 23 Paqué F, Peters OA. Micro-computed tomography evaluation of the preparation of long oval root canals in mandibular molars with the self-adjusting file. *J Endod*. 2011;37(4):517-21.
 - 24 De-Deus G, Reis C, Beznos D, de Abranches AM, Coutinho-Filho T, Paciornik S. Limited ability of three commonly used thermoplasticized gutta-percha techniques in filling oval-shaped canals. *J Endod*. 2008;34(11):1401-5.
 - 25 Pabel AK, Hülsmann M. Comparison of different techniques for removal of calcium hydroxide from straight root canals: an in vitro study. *Odontology*. 2017;105(4):453-9.
 - 26 Soo WK, Thong YL, Gutmann JL. A comparison of four gutta-percha filling techniques in simulated C-shaped canals. *Int Endod J*. 2015;48(8):736-46.
 - 27 Gok T, Capar ID, Akcay I, Keles A. Evaluation of different techniques for filling simulated c-shaped canals of 3-dimensional printed resin teeth. *J Endod*. 2017;43(9):1559-64.
 - 28 Aksel H, Makowka S, Bosaid F, Guardian MG, Sarkar D, Azim AA. Effect of heat application on the physical properties and chemical structure of calcium silicate-based sealers. *Clin Oral Investig*. 2021;25(5):2717-25.
 - 29 Vasconcelos I, Manilha C, Ginjeira A. A survey on root canal obturation trends: warm versus cold obturation technique. *G Ital Endod*. 2021;36(1):151-62.
 - 30 Bromberg CR, Alves CB, Stona D, Spohr AM, Rodrigues-Junior SA, Melara R, et al. Fracture resistance of endodontically treated molars restored with horizontal fiberglass posts or indirect techniques. *J Am Dent Assoc*. 2016;147(12):952-8.
 - 31 Kishen A. Mechanisms and risk factors for fracture predilection in endodontically treated teeth. *Endod Topics*. 2006;13(1):57-83.