

REVIEW ARTICLE

Diversity of root canal morphology in mandibular premolars and its treatment strategies

ABSTRACT

Variations in root and canal configurations can be observed in every tooth group. Mandibular premolars are a group of teeth where deviations in the root canal anatomy are common and are among the most difficult to treat endodontically. Diagnosis of root canal anomalies before endodontic treatment is a basic requirement. The root number and canal configurations aberrations such as double canal, C-shaped root canal system, 3-, 4-, and 5-canal are observed in mandibular premolars. There are relationships between some coronal and radicular features and multiple canal anatomy in mandibular premolars. There are significant correlations between external root morphologies and internal root canal systems of the mandibular premolars. Similarly, root characteristics may be related to some coronal features. This comprehensive review aims to examine the morphological variations observed in mandibular premolars and discuss the clinical and radiographic signs in the diagnosis of teeth with complex root canal systems before endodontic treatments.

Hakan Aydın¹**Kürşat Er^{2*}**

¹Department of Endodontics, Faculty of Dentistry, Antalya Bilim University, Antalya, Turkey.

²Department of Endodontics, Faculty of Dentistry, Akdeniz University, Antalya, Turkey.

Received 2023, September 21

Accepted 2023, October 11

KEYWORDS Mandibular premolar, root canal morphology, diversity, complexity, root canal treatment

Corresponding Author

Prof. Dr. Kürşat Er | Department of Endodontics, Faculty of Dentistry, Akdeniz University, Antalya | Türkiye.
Tel. +90 (505) 6542725, fax: +90 (242) 3106967 | Email. qursater@hotmail.com
Email: raghupublications820@gmail.com | Tel: +601128001325

Peer review under responsibility of Società Italiana di Endodonzia

10.32067/GIE.2023.37.01.23

Società Italiana di Endodonzia. Production and hosting by Ariesdue. This is an open access article under the CC BY-NC-ND license (<http://creativecommons.org/licenses/by-nc-nd/4.0/>).



Introduction

Observing variations in root canal morphologies is a common phenomenon for all tooth groups, and after numerous studies (1-3) and case reports on this subject, this situation is now considered routine. Root canal treatment (RCT) success can be achieved by managing accurately all treatment stages. The basic prerequisite for achieving this is a comprehensive knowledge of the anatomy of the root canal complexity (2). The anomalous root canal morphology can be observed in every tooth group with different percentage and degree, and when ignored, it is 1 of the major causes of endodontic failure (3,4). Having information about all root canal combinations that may be encountered and considering the possible existence of additional root canals and complex root canal systems in each case before endodontic procedures will minimize undesirable treatment results (5). Mandibular premolars are 1 of the tooth groups with complex canal shapes and are thought to be the most difficult to treat (1). There may be a misperception that their treatment is easy because they mostly exhibit a single root/root canal character and contain an oval form in cross-section and an oval root canal compatible with this form. However, these teeth are 1 of the tooth groups that show wide morphological variation. Second canal frequencies are significantly higher (6). Besides the double canal variant, the numbers and root canal configurations aberrations with C-shaped root canal system (7), 3-canal (8,9), 4-canal (2), and 5-canal (10,11) have been reported in the literature on mandibular premolars. Due to such a wide spectrum of canal variability, it is defined as the *Endodontist's Enigma* (12). One of the basic prerequisites in the ideal treatment of mandibular premolars exhibiting anomalies in the root canal morphology is to diagnose this condition before treatment. Therefore, the aim of this review study was to examine the clinical and radiographic features that should be taken into consideration in the diagnosis of root

canal configurations observed in mandibular premolars. This is thought to help clinicians in the treatment process.

Review

Prevalence of multiple canals

There are many epidemiological studies (13-15) conducted on mandibular premolars in different populations, races, ethnicities, and geographical regions, and the dominant root canal anatomy in both mandibular premolars is that they are 1-root and 1-canal. In a systematic review (16) that included studies in which all methodologies evaluating root canal anatomy were used as analytical tools, a prevalence of 97.2% 1-root and 2.6% 2-root were reported in first premolars. On the other hand, the presence of a 1-canal was found to be 73.55%, while the prevalence of a second canal was detected at a high frequency of 23.55%. Complicated root and canal structure was less detected in mandibular second premolars, and a 1-root prevalence of 99.28% and a 1-canal prevalence of 86.9% were presented (16). In a recent review that compiled studies using cone-beam computed tomography (CBCT) and micro-CT imaging as evaluation methods, the presence of multiple canals was found in 26.7% of mandibular first premolars and 8.2% of second premolars (17). Another recent systematic review (18) on mandibular second premolars reported that studies presented a complex canal prevalence of 0-10.5%. In these mentioned reviews, 3 and/or more root canals were rare in both premolars.

Especially with the increasing use of CBCT for dental purposes, the number of studies (1,6,19) on the prevalence of root and canal anatomy has increased in the last decade. In this way, the disadvantages of performing *ex vivo* studies on a limited number of teeth have been overcome (20). With larger sample numbers, the actual incidence rates in the researched population are better understood (21). The unclear interpretation of 2D radiographs has been resolved, and the effects of demographic and individual factors such as sex, tooth position, age, and symmetrical involvement

can be revealed (22). It is known that ethnic and geographical regional differences are effective factors in the root canal anatomy pattern in all tooth groups (3). In a CBCT study evaluating the prevalence of canal multiplicity in mandibular premolars from 23 different countries, the world average was found to be 23.8% in first premolars and 5.3% in second premolars (13). The lowest lingual canal prevalences were presented in Australia and East-Asian countries for both premolars, the highest in Africa for first premolars, and the highest in Europe, Africa, and West Asia geographical regions for second premolars. Complex root canal system in mandibular premolars is more common in men and shows sex differences (13,18). The most common canal configuration in mandibular premolars with complex root canal anatomy is Vertucci type 5 (1-2, Fig. 1). Vertucci type 3 (1-2-1), type 2 (2-1, Fig. 2), and type 4 (2-2, Fig. 3) are other more common configurations (1, 6, 14).

Coronal and radicular features

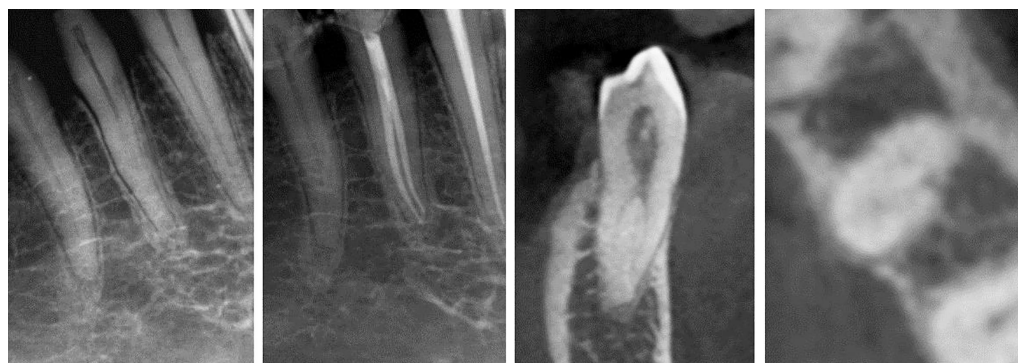There are significant correlations between external root morphologies and internal root canal systems of the teeth (5). Similarly, root characteristics may be related to some coronal features (21). Clinical and radiographic examinations of crown and root structures before RCT are the first steps in understanding complex root canal configurations. The mesiodistal (MD) and buccolingual (BL) dimensions of the crown, crown height, and distance between cusps are some macromorphological metric features that should be examined before RCT (23). In teeth with wider crown

widths, the number of roots and canals and the possibility of exhibiting complex canal features may increase (21). Additionally, the increase in the number of cusps and/or their being more prominent may result in deviation from the normal root anatomy (21). As in the crown structure, the development of tooth roots or the presence of radicular structures such as developmental grooves can lead to complex root canal anatomy (24). For this reason, it is important to visually examine the coronal structures of the teeth and evaluate their metric and non-metric properties before the treatment.

Mandibular premolars have 2 tubercles, 1 on the buccal and 1 on the lingual (23). That's why another name for these teeth is lower bicuspid teeth. Turner et al. (25) determined all non-metric features that could be observed for all tooth groups in 1991, based on their observations, anthropological studies, and literature information over many years, and made a scoring system according to their existences and degrees. The graded standards of these dental characteristics called the Arizona State University Dental Anthropology System (ASUDAS), are widely used in dental anatomy (26-28). In this scoring system, non-metric dental features that may be specific to mandibular premolars are stated as follows; presence of odontoma on the occlusal surface, lingual cusp variations (absence of cusp in the lingual region, presence of 1-, 2-, or 3-cusp in the lingual and size differences of buccal/lingual cusp), presence of developmental radicular grooves, Tomes' root, and number of roots. Identifying these features(s) and

Figure 1

The most common second canal type in mandibular premolars is Vertucci type 5 (1-2). Root canal system, which continues as a 1-canal after the CEJ, ends as 2 separate canals separating in the coronal, middle, or apical thirds.



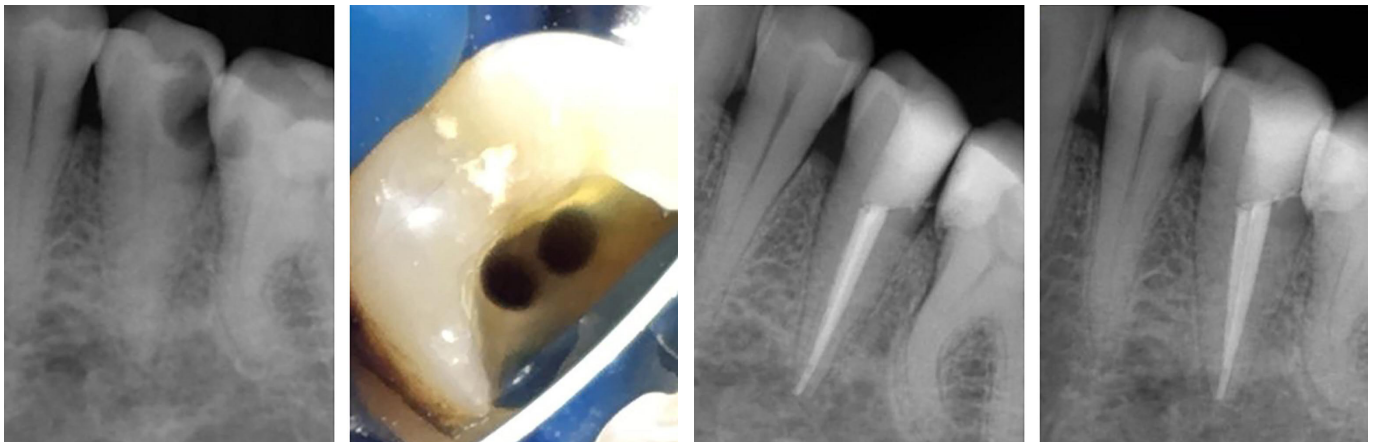


Figure 2
RCT of a mandibular second premolar exhibiting Vertucci type 2 (2-1) root canal configuration. A 1-canal is observed in the pre-operative periapical radiography. However, the eccentric location of the canal in the root indicates the presence of a second canal.

having knowledge about their effects on root canal diversity can be useful in diagnosing. Among the mentioned non-metric characteristics, the most important features that cause complexity in root canal anatomy are the presence of developmental grooves and Tomes' roots.

these depression areas are one of the predisposing factors for the onset and spreading of localized periodontitis. These grooves act as reservoirs for microorganisms and can lead to persistent infections (26).

In mandibular premolars, when the roots are divided into 2 or 3 by root furcation and terminate independently, they are considered separate roots. On the other hand, the presence of longitudinal developmental root grooves along the root and 2 or more unseparated root-like division cones in a 1-root are called radicals and are not designated as separate roots (25,29). There are 2 separate roots in maxillary

Developmental radicular grooves and Tomes' root trait

Root grooves are longitudinal depressions located on the root surfaces of teeth (27). Advantageously, these grooves increase the area of the root surface and load capacity of the periodontal membrane. However,

Figure 3
RCT of a mandibular second premolar with Vertucci type 4 (2-2) root canal configuration. The initial radiograph taken at a straight angle provided limited information about the second canal. The presence of the second canal is observed in the angled radiograph.

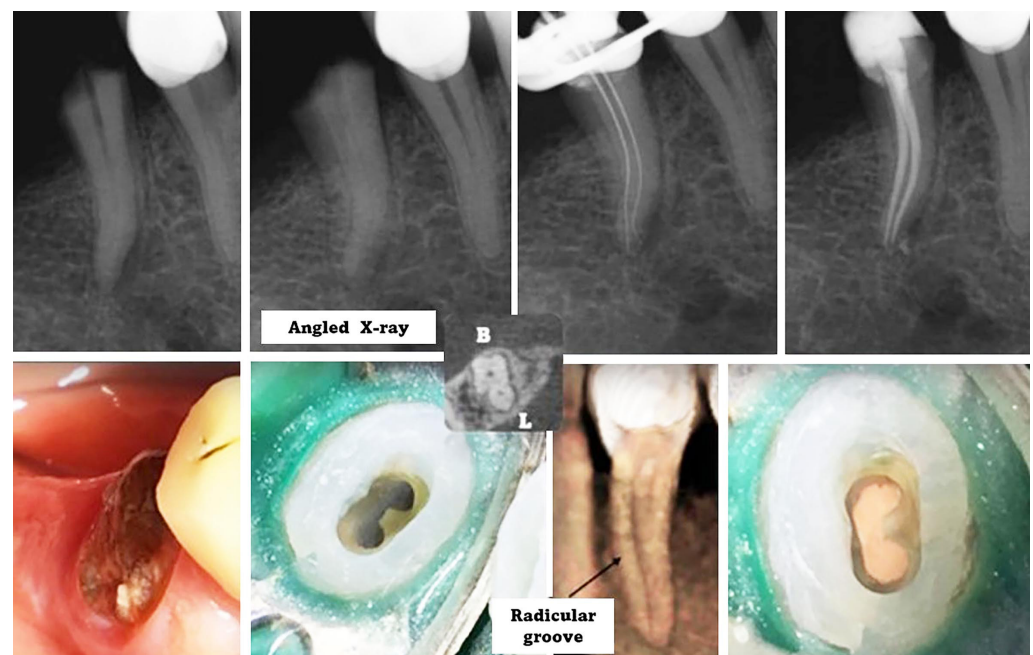
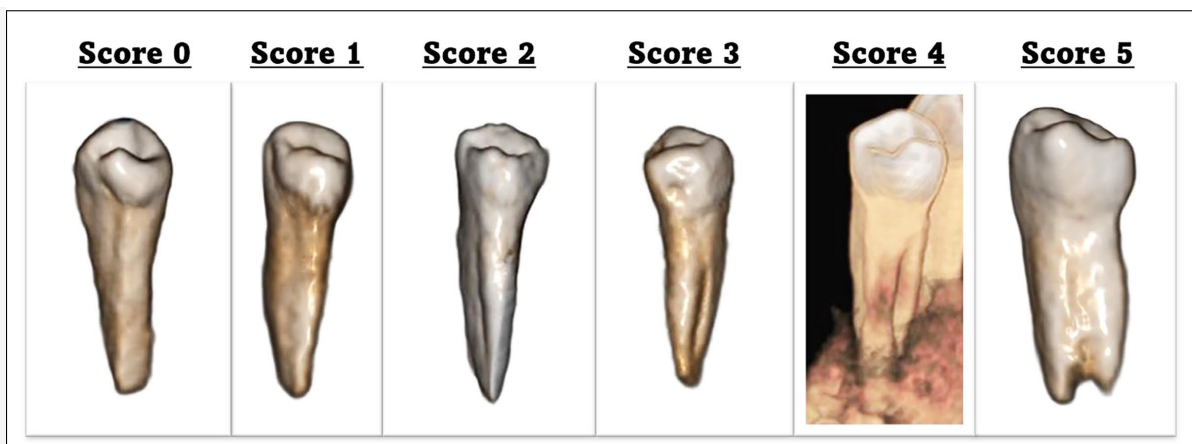

Figure 4
Examples of
radicular
grooves
according to
the ASUDAS
scoring
system.



premolars, or in cases where 2-root are fused, these roots are round in cross-section. However, in the presence of root grooves in mandibular premolars, the cross-section of the roots has a form that cannot be identified as separate roots. Radicular grooves in mandibular premolars were examined in detail anthropologically and a scoring system was developed according to their severity (Fig. 4) (29,30). According to the ASUDAS classification, the scores are as follows. **Score 0:** Developmental groove is absent or, if present, shallow rather than a V-shaped depression; **Score 1:** Developmental groove is present and has a shallow V-shaped cross-section; **Score 2:** Developmental groove is present and has a V-shaped cross-section of moderate depth; **Score 3:** A V-shaped and deep groove is present. The groove extends at least one-third of the entire length of the root; **Score 4:** Double groove present on both mesial and distal surfaces; **Score 5:** Two or more roots present. Teeth other than Score 5 are considered single-rooted. Cases Scores 3 and 4 (teeth with deep radicular grooves) are known as Tomes' root trait.

Radicular grooves in mandibular premolars may differ in terms of depth, length, complexity, and location (26). Grooves deeper than one-third of the root in the BL or MD direction are called deep grooves, and those that are more superficial are called shallow grooves (31). Not every indentation is described as a groove; if there is only a shallow and rounded indentation extending longitudinally on the proximal

surface, it is called a concavity, and if there is a V-shaped cross-section, it is called a radicular groove (26). Radicular grooves, whose incidence is affected by differences in race, population, geographical region, and examination method, are encountered with a prevalence of up to 40% in mandibular first premolars (32). It is less common in mandibular second premolars (33). Developmental root grooves are often located on the mesial surface of the root, especially in the mesiolingual (ML) region (7,32). However, it can also be seen on the distal, buccal, and lingual surfaces of the root (6,26). These invaginations, located on the proximal surface, form a C-shaped root in cross-section of the root. It can be single or can be found on both sides of the root (26). The initial level is approximately 3 mm below the cemento-enamel junction (CEJ) (7). The deepest points are in the middle levels of the root (27). Not all radicular grooves continue apically. Most of them initiate in the coronal third and end in the apical third (32). The groove length is approximately 65% of the root length (7). Only 40-43% extends apically (7,32). As it is located mostly on the mesial surface of the root, it causes significant reductions in dentin thickness on this surface (34). Increasing groove depth and angle leads to significant decreases in mesial dentin thickness (34). In a study (34) evaluating C-shaped mandibular premolars with radicular grooves, it was shown that the mesial canal wall could decrease up to 0.17 mm.

The most important point from an endo-

dontic perspective is that there is a serious relationship between the radicular groove and the complex canal forms (Fig. 5) (31). A broad spectrum of morphological deviation is observed in mandibular premolars with radicular grooves (26). In a micro-CT study (26), only 8.5% multiple canals were observed in mandibular first premolars without Tomes' root (ASUDAS 0-2), while this proportion was found to be very high as 78.2% in the Tomes' root group. Additionally, the incidence of multiple canals increased with a rising ASUDAS score. In another study, the presence of 2 or more canals was found in 93.8% of mandibular first premolars with radicular grooves (35). Many *ex vivo* and *in vivo* studies have supported this finding (6,27,32). More than half of the mandibular first premolars, which feature Tomes' root (ASUDAS 3-4), have double canals as well as 2 separate canal terminations, which further increases the importance of the treatment of these teeth (27). It has been shown that the radicular groove depths in teeth with 1-canal morphology are less shallow than in double canal variants and do not extend to the apex (32).

Mandibular premolars with radicular grooves also have high furcation canal (33%) and apical delta frequencies (43%) (24). Furcation canals, called radicular groove accessory canals, originate from the pulp chamber or the semilunar buccal canal close to the canal furcation and end in the radicular groove (28). Diameters can be as large as 0.21 mm and may cause an extension of the endodontic lesion into the periodontal region (Fig. 6) (28). When primary endodontic infection causes a periodontal lesion, it may cause the formation of a deep pocket, raising suspicion of a vertical fracture.

Another common canal feature in teeth with radicular grooves that needs to be examined in detail is the C-shaped root canal system.

C-shaped root canal system

Although the C-shaped root and canal system is an anatomical formation that is mainly observed in mandibular second molars, it can also be observed in maxillary molars and mandibular premolars (1,36). The C-shaped feature, characterized by the presence of webs and fins between individual canals, has been a subject of particular interest as it poses many therapeutic challenges. There are fundamental differences between the C-shape root canal system in mandibular molars and premolars. While it is observed in mandibular molars when the mesial and distal roots are fused because of incomplete separation, in mandibular premolars it is observed in cases of radicular groove, which is an attempt to increase the number and complexity of the roots. C-shape structure in mandibular premolars is evaluated separately based on root and root canal (7,31). Single-rooted mandibular premolars, where a deep radicular groove is present, have a C-shaped root structure in cross-section (Fig. 5 and 6).

Different root canal shapes are observed in cross-sections of C-shaped mandibular premolars. Fan et al. (7) determined 6 different configurations could be observed in C-shaped mandibular premolars cross-sections. **Category 1 (C1):** Resembling the letter C, continuous shape without any

Figure 5
There is a significant correlation between the presence of a radicular groove and the presence of the second canal. Radiographic and CBCT views of the mandibular first premolar with a radicular groove on the mesial surface extending to the root apex. The radicular groove is observed as a distinct vertical line on the radiograph (black arrow).

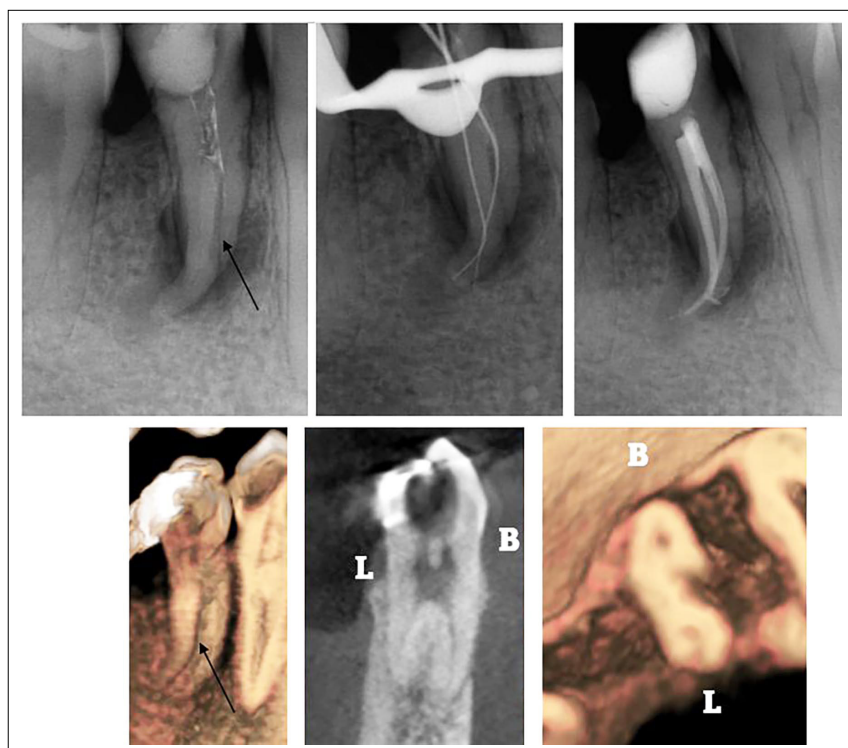

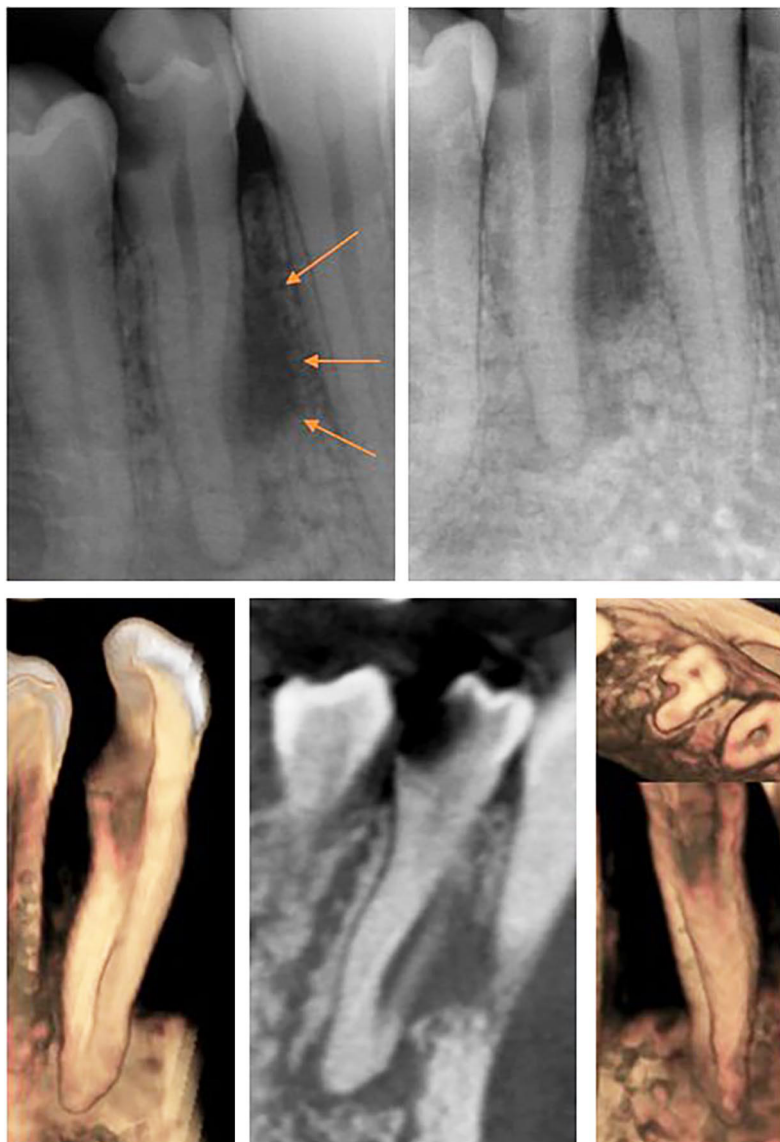


Figure 6

Periapical and CBCT images of the mandibular first premolar with apical periodontitis.

There is a deep radicular groove on the ML surface of the tooth and a radicular groove extending to the apex (ASUDAS scoring class 3, Tomes' root, clearly visible on the angled periapical radiograph). There is a lateral lesion centered on the deepest level of the groove.

The primary endodontic problem through the radicular groove accessory canal caused the periodontal lesion.

division or separation between the canals; **Category 2 (C2):** A semicolon-like shape, without continuity in the outline of the letter 'C'; **Category 3 (C3):** With two flat, oval, or round canals; **Category 4 (C4):** A single canal is present; this category has 3 subtypes. *C4a*, round form with nearly equal aspect ratio of the canal. *C4b*, oval canal form in which the long diameter of the canal is less than 2 times the short diameter. *C4c*, flat canal form in which the long diameter in the cross-section of the canal is more than twice the short diameter; **Category 5 (C5):** With 3 or more canals; **Category 6 (C6):** Canal lumen not visible. Four different features can be seen in

C-shaped mandibular premolars (31); *a)* Only continuous C-shape: this type has a continuous C-shaped canal system. This C-shaped canal gradually turns into a non-C-shaped round or oval canal or divides into 2-canal; *b)* Semilunar buccal canal; the single canal system, which starts as oval coronally, then divides into a semilunar buccal canal and a non-C-shaped lingual canal. The semilunar buccal canal may later turn into a smaller semilunar canal or a non-C-shaped canal; *c)* Combination of a continuous C-shape and a semilunar buccal canal: a continuous C-shaped canal is divided into a semilunar buccal canal and a non-C-shaped lingual canal; *d)* Semilunar buccal canal is interrupted by 1 or smaller non-C-shaped canal. A mandibular premolar tooth with a C-shaped root structure is not included in the C-shaped root canal system category if it has 2 separate, non-C-shaped root canals (34). In cases of *C1*, and *C2* configuration and the presence of a significant isthmus between 2/3 canals, it is considered a C-shaped tooth (26,34). In some CBCT studies, the conditions of the presence of radicular grooves and exhibiting *C1* and *C2* configuration at any position of the root canal system have been considered (33). Different diagnostic criteria and examination methods have led to variable prevalence being reported. As with radicular grooves, C-shaped root canal prevalence is affected by ethnic and regional differences and varies depending on the methodology used. A relatively high prevalence of 20% has been reported in *ex vivo* micro-CT studies (26,34). Conversely, lower incidences have been presented *in vivo* CBCT studies. Martins *et al.* (33) reported low prevalences of 2.3% for first premolars and 0.6% for second premolars in the Portuguese population. In another study, it was reported that in the Turkish population, it was 4.6% in first premolars and 1.1% in second premolars (6). Their incidence is higher in the first premolars (33). There have been reports that C-shape is more common in men (33). However, no difference was observed in terms of tooth position (33). It has been observed that it is more unilaterally (33).

There is mostly a 1-canal in the coronal third of mandibular premolars with a C-shaped root canal system (7). Since radicular grooves are mostly located in the middle third, the prevalence of C1 and C2 canal configurations increases in this region. C2 and C3 canal shapes are dominant in the apical third. (7). Because the C-shape configuration is located after the orifice of a round or oval canal and away from the apex, the root structure has been named by 3 different names. Non-C-shaped coronal and apical section and C-shaped middle section (31). C-shaped canals are mostly located 6-11 mm below the CEJ (34). There is a strong correlation between the presence of radicular grooves and the C-shape. In a study comparing mandibular first premolars with and without radicular grooves, no C-shape configuration was detected in any teeth without radicular grooves (31). On the contrary, C-shaped canals were identified in 66.2% of teeth with radicular grooves. Additionally, C-shape was observed to be more relevant in deep grooves. In another *ex vivo* study (24), 67% C-shape configuration was found in mandibular premolars with radicular grooves. In an *in vivo* study (6), all C-shaped canals encountered in both premolars were detected in teeth with radicular grooves.

The root length, which continues as a C-shape, is approximately 4.5 mm (31). Mandibular premolars with buccal radicular grooves are observed especially in the second premolars, and the axial morphology creates a 'reversed C-shaped canal system' (15). In these cases, the main canal is almost close to the lingual surface of the root.

Since radicular grooves are so important in mandibular premolars, their presence should lead clinicians to be more careful about the second canal.

Mandibular premolars with 3-5 root canals

It is scarce variation for mandibular premolars to have 3 or more canals (1). Information about the external and internal root canal anatomy of teeth with 3-canal consists mostly of case reports (4,8,9,37). There is only 1 study (38) in the literature on the qualitative and quantitative characteristics of mandibular premolars with 3-canal. In this study, 16 mandibular premolars with 3-canal were evaluated. Nine of the 16 teeth were seen in single-rooted teeth with radicular grooves (Fig. 7 and 8). In 3 samples, although the main root was divided into mesial and distal by a deep groove at the middle level, it continued to be fused up to the apical. In 3 samples, it was determined that there was division at the apical level on the buccal side of the root. Only 1 sample was observed to have 3 separate roots (Fig. 9 and 10). That is, 3-canal teeth mostly have 1- or 2-root (Fig. 7 and 8). In 15 of these teeth, canal localizations were observed as mesiobuccal (MB), distobuccal (DB), and lingual canals (Fig. 7-10). In the other single tooth, 1 buccal and 2 lingual canals were observed. Cases of fusion of DB/Lingual and DB/MB canals have been detected. While the shape of the canal orifices was triangular except for 1 tooth, it was found to be linear in 1 tooth. In mandibular premolars with 3-canal, this location of the canals allows the de-

Figure 7

RCT of a mandibular first premolar with a 1-root and 3-canal. The root canal system begins as a 1 common canal (yellow arrow). The canals are divided into 3 by canal trifurcation, which is localized in the coronal third (green arrow). Root canals are in MB, DB, and DL.

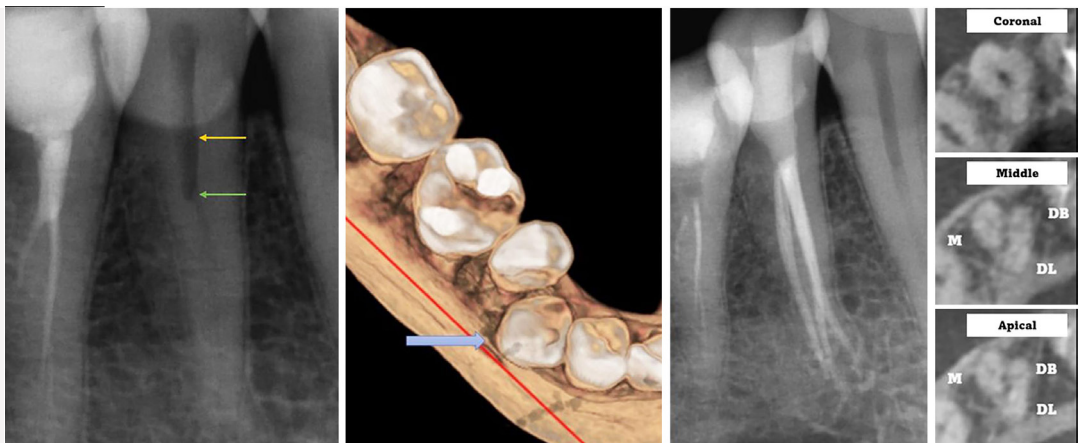


Figure 8

CBCT multiplanar and reconstruction images of a mandibular second premolar with a 1-root and exhibiting 1-3-1 root canal configuration. There are 2 radicular grooves on the buccal and lingual surfaces of the tooth (ASUDAS score 4, Tomes' root). Root canals begin as a single, oval, common canal, and the canal trifurcation point is in the coronal third. Root canals are MB, DB, and DL. While the DB and DL canal orifices are closer to each other, the distance between the MB and lingual canal orifices is the longest.

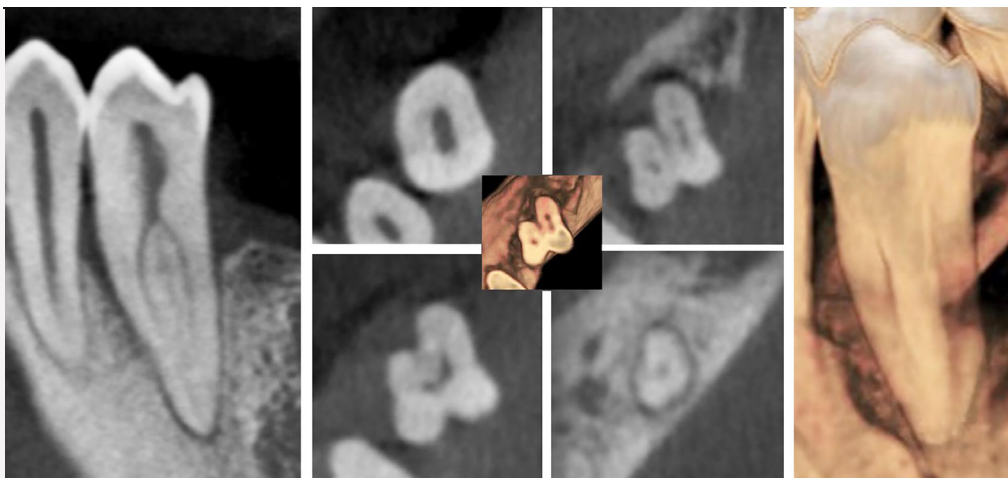


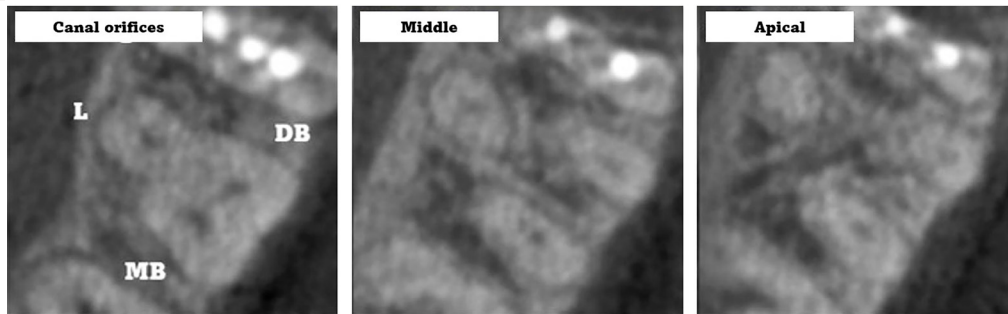
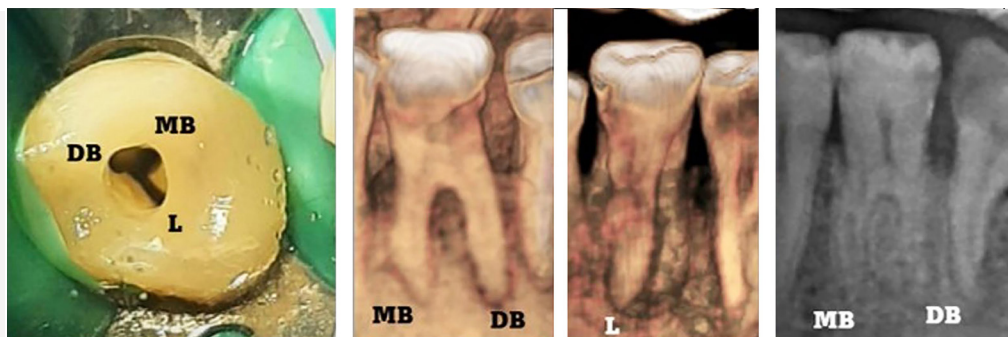
Figure 9

Initial, working length, main apical cone, and final periapical radiographs of the 3-rooted lower left mandibular second premolar (ASUDAS score 5). The periodontal ligament spaces of the 3-root are diagnosed on the pre-treatment periapical radiography.

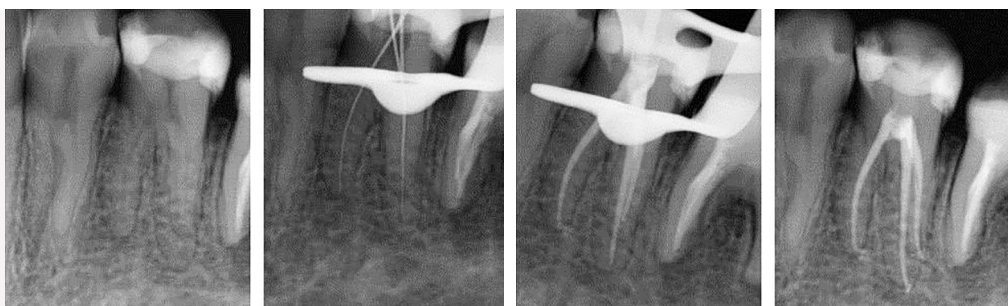

Figure 10

Root canal orifices and CBCT images of the same tooth are in figure 9. CBCT images showed that the tooth had 3 separate roots and canals. There are 2 roots in the buccal and one root in the lingual. The fact that the root canal trifurcation level is in the coronal third facilitates direct access.



tection of at least 2-canal, mesially and distally, on 2D radiographs (Fig. 7 and 9). Lotfi *et al.* (11) defined the presence of a double canal in the distal and a 1-canal in the mesial as teeth with atypical canal

orifices. In this type of 3-canal case, the DB and distolingual (DL) canal orifices are in the same direction in the pulpal floor anatomy, and there is a canal orifice on the ML wall (11). Canal orifice distances are

often unequal. The distance between MB-Lingual canals was found to be the longest, and DB-Lingual was the shortest (Fig. 8) (38). Root furcation is mostly located in the middle third (Fig. 10). The average distance of the pulp chamber floor to the CEJ is 5.5 mm. This distance minimizes the risk of perforation during access cavity preparation (38). At root canal furcation levels close to the CEJ, visibility of the canal orifices is easier (Fig. 10).

In 4-canal mandibular premolars, the canal locations were reported to be 2 buccal and 2 lingual canals (2). Five canal cases with double DB, DL, MB, and ML locations have also been observed (10).

Developmental anomalies

Some developmental malformations can be encountered in mandibular premolars, which complicate the root canal anatomy and need to be differentiated. Major ana-

tomical variations such as dens invaginatus, taurodontism, fusion or gemination, and fusion with adjacent supernumerary teeth can be seen in mandibular premolars and may lead to deviations in root canal systems (39,40). Although their incidence in mandibular premolars is low, they should be taken into consideration before treatment.

Coronal and radicular clinical appearance

The evaluation of crown structures before RCT in mandibular premolars and how these features predict root and canal anatomy are unclear. Although the excessive material loss in teeth requiring RCT often makes it difficult to evaluate the coronal properties, an attempt can be made to get an interpretation by examining the crown structures of antimeric teeth due to the high symmetrical involvement in coronal and radicular deviations. Among the dou-

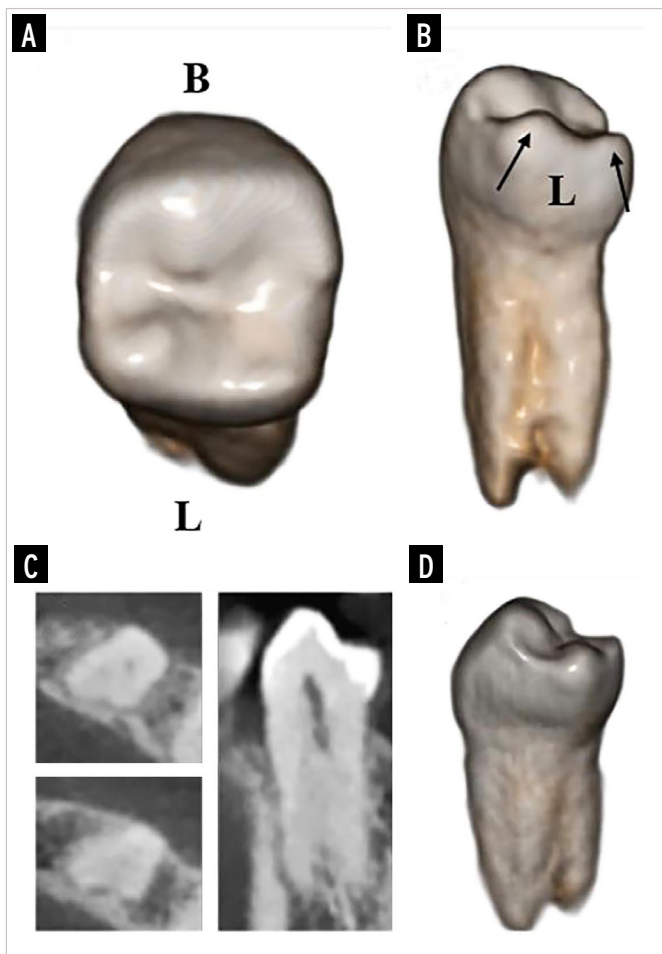


Figure 11

Multiplanar and 3D reconstruction CBCT images of a mandibular second premolar ending in 2 separate roots. **A)** Occlusal view of the tooth. The lingual part of the crown is more voluminous and prominent than the buccal part; **B)** Lingual view of the tooth. Presence of double cusps with an additional cusp increase in the lingual. Radicular structures show integrity in connection with these tubercles. Root structures terminate as double roots in the mesial-distal direction (ASU-DAS score 5). Black arrows indicate the lingual cusps; **C)** Atypical radicular and canal morphology is observed in multiplanar CBCT sections; **D)** Proximal aspect of the tooth.

Figure 12

External view of a mandibular second premolar in which the lingual crown structure is more voluminous than the buccal crown structure. The double tubercle on the lingual is supported by prominent root structures and results in the presence of a deep radicular groove on the lingual.

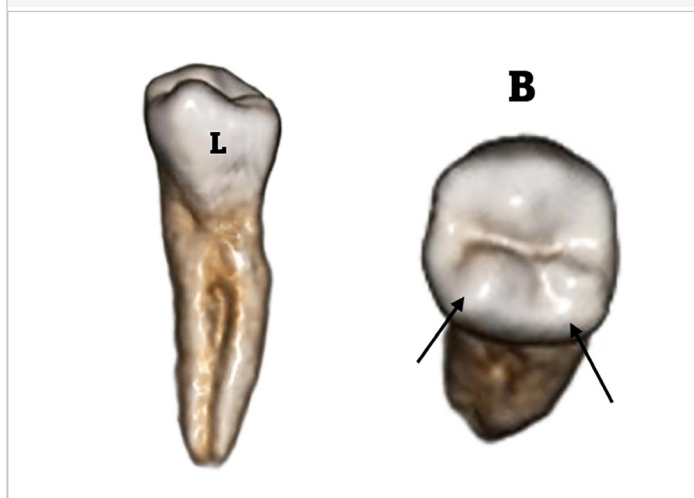


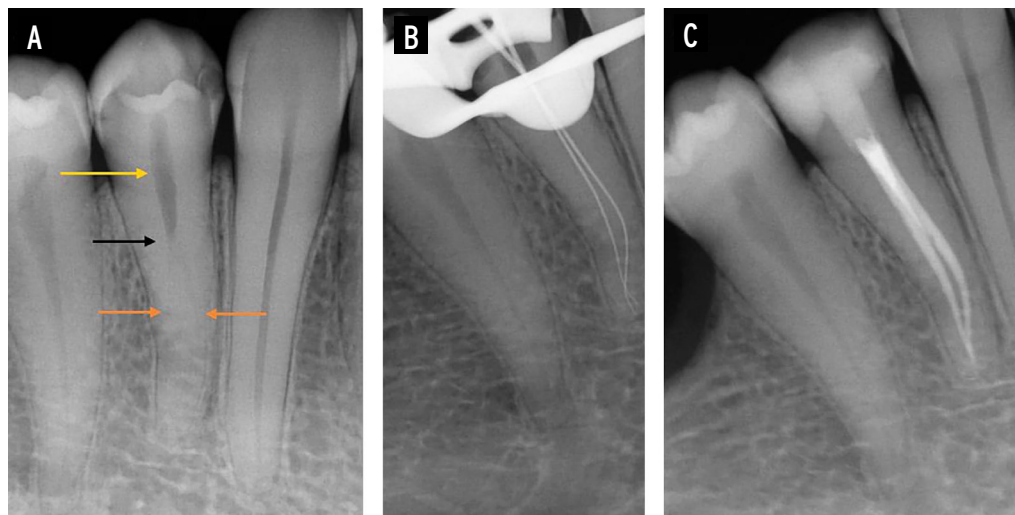
Figure 13

RCT of a 2-canal mandibular first premolar. Initial periapical X-ray shows that the integrity of the root canal is disrupted in the middle third (orange arrow). After this level, the canal is viewed as a single and vague canal. Additionally, the root groove appears as a vertical line on the lateral surface of the root (black arrow).

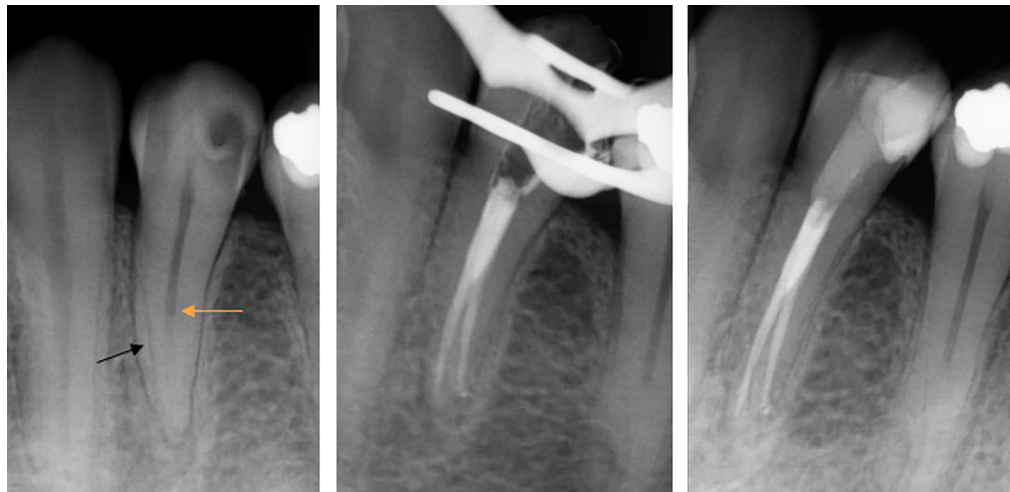

Figure 14

A) Pre-treatment periapical radiograph and **B, C)** RCT of a 2-canal mandibular premolar. When the initial periapical X-ray is examined carefully, the presence of a single distinct canal is viewed after the CEJ (yellow arrow). The canal course disappeared between the coronal and middle thirds (fast-break phenomenon, black arrow). After this point, 2 canals are observed very faintly (Orange arrows). These findings diagnose this tooth as having 2-canal.



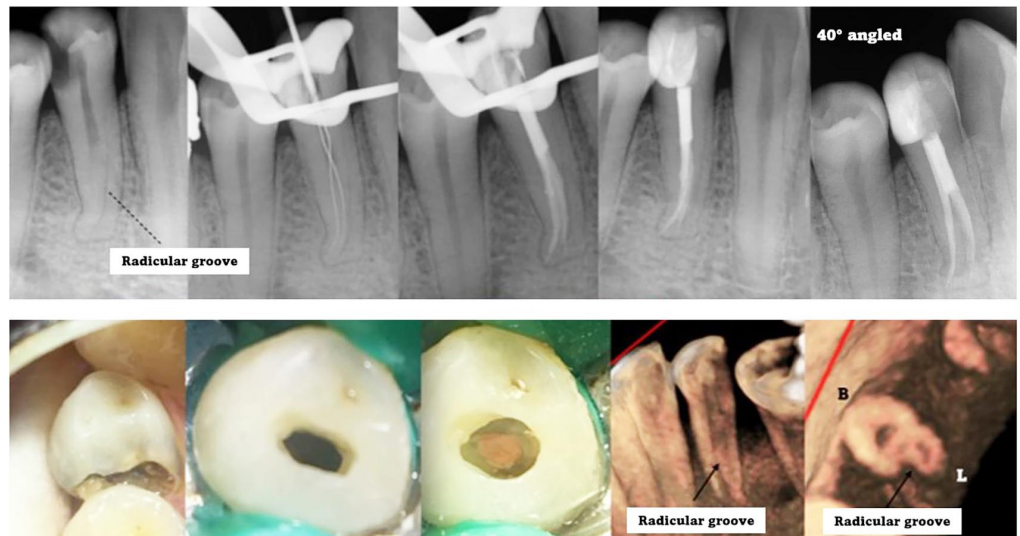
ble tubercles found on mandibular premolars, the buccal tubercle is more developed and prominent than the lingual tubercle. One of the features of the ASUDAS mandibular premolar crown is the number of cusps in the lingual region. In some cases, the lingual and buccal tubercles are fused and there is a single tubercle on the tooth. However, there may be cases with 2 or 3 lingual cusps (30). The additional number of cusps in the lingual is observed more in the second premolars (29). However, there is limited information about the deviations of the coronal structures of mandibular premolars with complicated root and canal anatomy from normal variants. Some case reports presented the crown dimensions and the number and development of the occlusal cusps within normal limits and stated that they had typical coronal struc-

tures (4,11,37). However, Martins *et al.* (13) pointed out that the incidence of double canals is affected by ethnicity and geographical regions, with the highest rates in Africans and the lowest rates in Asians, and they pointed out that the sizes of the teeth are quite variable between these 2 races. They suggested that larger premolars in Africans may affect the incidence of second canals. Additionally, as shown in figures 11 and 12, it is seen that there are double cusps on the lingual side of the mandibular second premolars, which have 2 separate roots, and this additional cusp is supported by the root structure. Therefore, more caution should be exercised in cases of additional cusps.

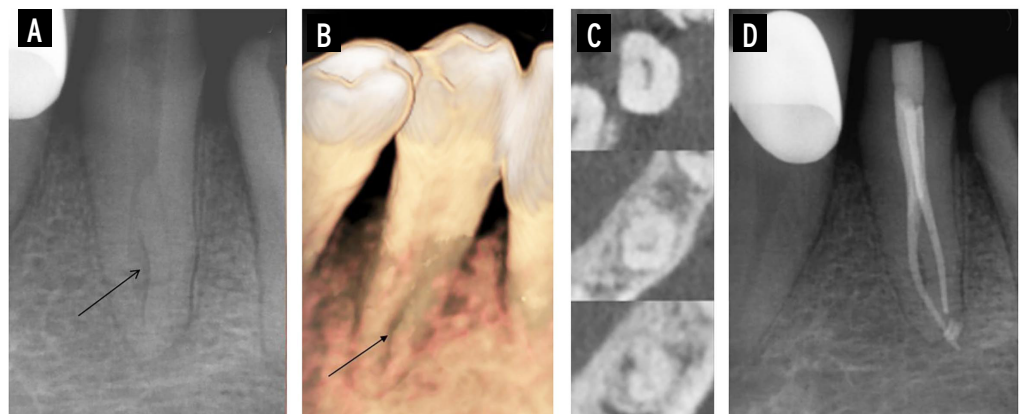
Another component that can be evaluated clinically is visual inspection of the roots. If there is gum recession, the presence of

Figure 15

Assessment of the outline of the root and the condition of the periodontal ligament in the initial periapical radiograph can provide information about the general outline of the root. Deep and long radicular grooves can be observed as vertical lines on the radiograph.

**Figure 16**

A) Pre-operative periapical radiograph, **B)** 3D reconstruction image, **C)** axial cross-sectional CBCT images in the coronal, middle, and apical thirds, and **D)** post-treatment periapical radiograph of a rotated mandibular first premolar. The rotation of the tooth presented clear indications of the buccal and lingual canals in the pre-operative radiograph (canal bifurcation level is in the middle third, up to this level it is observed in 1-canal radiography). In addition, its rotation caused the radicular groove on the mesial surface (ASUDAS score 3) to be interpreted as a separate canal. In the CBCT images, it is observed that there is a C-shaped canal in the buccal C2 category and a lingual non-C-shaped canal.



furcation in the root can be evaluated. The location of radicular grooves on the proximal surfaces of double-canal teeth may not be beneficial in buccal recessions, but in the presence of more than 1-root, the mesial and distal placement of the roots may make examinations possible.

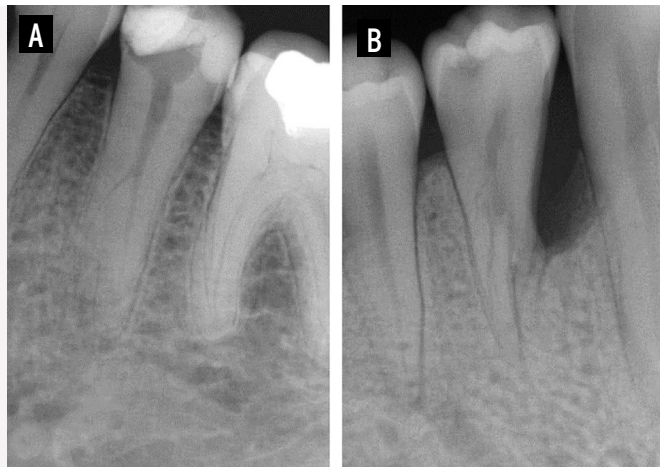
Radiographic appearance

Since coronal structures do not contribute to every case, the most effective diagnostic tool for root canal multiplicity in mandibular premolars is periapical radiographs. Although the knowledge and skills of endodontists or clinicians are important in successful RCT, multiple canals should be understood by detecting the presence of some radiographic findings. In mandibular bicuspid teeth with complicated root canals, the number, position, shape, and outline of the roots should be assessed on radiography

(41). The first rule of radiographic investigation is that the radiographs must be of sufficient quality and taken in the appropriate position. In the next step, knowing which radiographic signs are present will increase the diagnosis of the presence of additional canals (41).

During radiographic examination, the evaluation of root contours and canals must be done separately (42). The presence of a double shadow of the periodontal ligament and the observation of the periodontal ligament space on both sides of the root are features to be evaluated along the contours of the root. Since the root canals in 2-canal mandibular premolars are localized in the BL direction, radiographic assessment of the second canal is not possible in most cases. The superposition of roots and canals can cause problems in the radiographic definition of root canal anatomy (43). The

Figure 17
Radiographic views of mandibular premolars with 3-canal. **A)** A mandibular second premolar has an atypical root shape and different root contours. The outer contours of the roots and the tracing of the periodontal ligament indicate the multiple root structures. **B)** A mandibular first premolar in which the furcation level of the roots is observed.



lingual canal is completely or partially overlapped with the buccal canal (44). The most effective way to overcome this problem is to take multiple radiographs from different angles (Fig. 3). Martinez-Lozano *et al.* (43) evaluated canal visualization of mandibular premolars with different horizontal and vertical angles. They reported that horizontal angulation facilitates detection in the second canal and that radiographs taken at a 40° angle are more effective than 20°. They also stated that vertical angulation also had a significant effect. Some radiographic findings are related to the presence of a second canal. The most typical radiographic finding in these teeth is sudden narrowing or even disappearance of the root canal (45). This finding, described as a *fast break*, is the result of the root canal splitting into 2 or more branches at this point (Fig. 1,7,13,14,18). Sudden canal narrowing is a good radiographic criterion for intricate root canal systems and there are no differences in the detection of this cri-

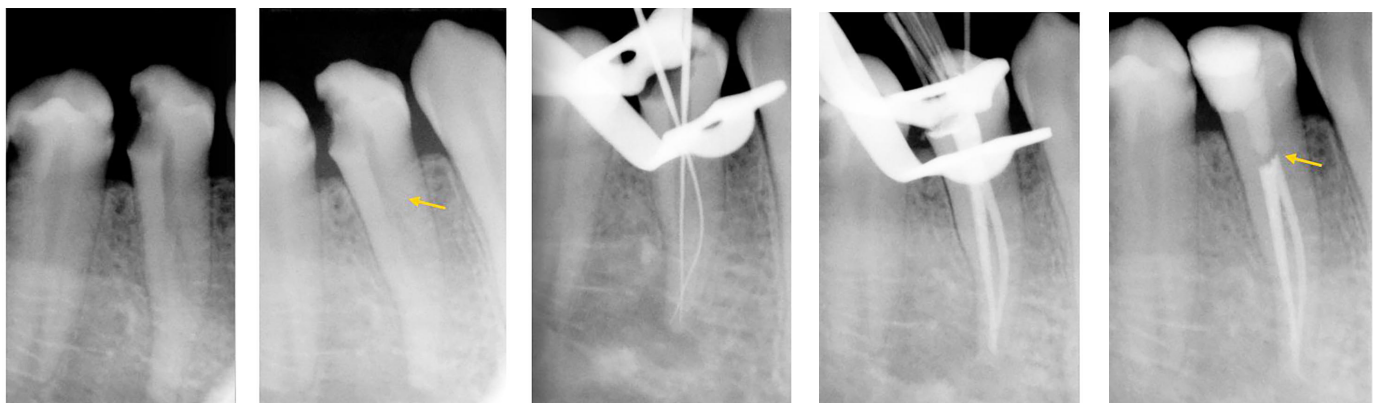
terion between observers (45). Deviation of the canal to one side during the canal course is another indicator of root canal bifurcation (42). In angled radiographs, the canal bifurcation can be observed in the BL direction. In some cases, after the fast break phenomenon, the canal becomes less clear and faint (Fig. 13) or can be observed as 2 faint canals (Fig. 14).

The high prevalence of multiple canals in mandibular premolars with radicular grooves

makes it important to examine this anatomical formation on radiography (Fig. 5,6,13,15,16). Radicular grooves usually present as a radiolucent parapulpal line on X-ray. This parapulpal line can be observed longitudinally (Fig. 15). When the radicular groove is observed, the presence of a second canal should be considered more comprehensively. However, in some cases, it can be perceived as a separate canal and may suggest the presence of a third canal in a double-canal tooth (Fig. 16).

In mandibular premolars with 3 or more canals, signs of apical separation of the roots and sudden changes in the radiographic density of the root canal in the middle and apical thirds are observed in the radiography (Fig. 7) (2). If there are 3 separate canals within a 1-root, multiple weak radiolucent lines may be seen within a 1-root (46). Radiographic signs of teeth with 2/3 roots or 3 canals are in most cases more pronounced than those of teeth with 2 canals (Fig. 9 and 17) (41). However, in some cases, the

Figure 18
In a complicated canalled mandibular premolar, the root canal bifurcation level in the coronal third is a factor that facilitates the detection and treatment of the canals. The yellow arrow shows the bifurcation point of the canals.



superposition of roots in a narrow area may prevent the viewing of all root canals (41). Zoya-Farook *et al.* (9) stated that the radiographic appearance of the 3-canal case appeared bulbous. Atypical root shapes and different root contours indicate the additional number of roots.

In cases where clinical and radiographic findings cannot provide a clear interpretation, CBCT provides more advanced root and canal configuration information (Fig. 1,3,5-7,10,16). The 3D structure of CBCT and its elimination of the superposition of surrounding tissues enable us to understand features such as the number of roots and canals and the presence of merging in the canals before treatment (1). In a study (47) of premolars, CBCT imaging was significantly more accurate than periapical radiography in determining root canal anatomy. If the indication criteria are observed, CBCT is the most clinically effective method in the diagnosis of root and canal anatomy.

Access cavity and negotiation of canals

Multiple canals can be understood with some findings intra-operatively in mandibular premolars, where an interpretation is provided clinically and radiographically. Another factor that increases the difficulty in the RCT of mandibular bicuspid with multiple root canal systems is the limited field of visualization due to the relatively small size of the access cavities (2). It is not easy to explore and manage the canals in small access cavity preparations in the mesiodistal direction (2). The most important supporting equipment in the treatment of mandibular premolars with complicated root canals is the use of magnification tools (46). In this way, deeply split root canals can be scouted not only with imagination but also visually (12). The overall quality and success rate of the treatment is increased. Careful inspection and observation of the pulp chamber floor and walls reduce errors (10).

In both 1- and 2-canalled mandibular premolars, the root canals start as a 1-canal orifice. The most common canal orifice shape is an oval form. This is followed by flattened-ribbon shape, eight-shaped, and

triangular 1-canal orifice shapes, respectively (35). However, there are no significant differences between the canal orifices of double and 1-canalled teeth, making the detection and treatment of the lingual canal difficult.

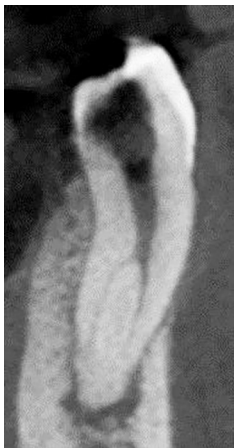In 2-canal teeth, the canals are in the BL direction and the split points are mostly in the middle third, with less apical and coronal division (44). It is easier to find canals in separations close to the coronal third (Fig. 3 and 18). In root canals that have a deep bifurcation in the middle and apical thirds, it becomes difficult to detect the lingual canal. The buccal canal is the canal that is large, and the canal instrument moves straight through. The lingual canal is the canal that is more difficult to scout, explore, and prepare. When the lingual canal is separated at a sharp angle, an image resembling the letter 'h' is formed in the coronal section of the 2-canal (Fig. 19).

It has been suggested to enlarge the pulp chamber with Gates-Glidden burs to facilitate better observation and detection of the canal orifices (9). It is a common procedure to use a pre-curved K-file over the root canal walls with tactile examination and capture a catch point. There have been clinicians reporting that the use of dyes such as methylene blue is beneficial (8). It has been suggested that in teeth with 3 or more canals, placing a small amount of calcium hydroxide at the bifurcated dentin point increases vision in the root canals and facilitates canal exploration (10). Sodium hypochlorite bubbling test and observation of bleeding points are other useful methods (48).

In teeth with 3-canal, the canal orifices deviate from the normal BL direction and are not in a straight direction. The presence of a third canal should be suspected in the pulp chamber floor deviating from the normal anatomy in a triangular shape or a wider form in the MD direction. It is crucial to understand the topographic location of the furcation and determine the location of the canal orifices (8). Anatomical landmarks of the pulp chamber floor can help in the diagnosis of complex

Figure 19

In mandibular premolars with 2-canal, the buccal canal continues straight. The lingual canal is separated from the main canal at a certain angle. In some cases, this angle can be very sharp and is named the 'h' canal.



root canals. Black spots should be observed on careful examination of the pulpal floor and walls. Interpretation of the pulp floor map is useful in diagnosing all canals.

Root canal preparation

In mandibular premolars with 2-canal, the buccal canal is wider and considered the main canal. The lingual canal is separated from the main canal at a sharp angle of approximately 34° (44). While the lingual canals are straight from the lingual view, they are mostly bifurcated from the proximal view at a severe angle (44). There are cases where this angle is 65° (44). Additionally, the lingual canal is often curvature. Although coronal flaring is recommended in the lingual canal to reduce curvature (44), Gu et al. (34) pointed out the thinness of the dentin thickness in the lingual region and recommended conservative shaping in the lingual canal, as excessive removal of dentin in the coronal region would weaken the root. There is only 1 study (49) in the literature that evaluates the root canal instrumentation of mandibular premolars with radicular grooves and a lingual canal. In this study, ProTaper Next (PTN) and XP-endo Shaper (XPS) systems were compared. With XPS, less apical canal transport and more remaining dentin thickness were achieved in the lingual canal. No difference was observed after preparations in the buccal canal. In the lingual section, attention was drawn to the thinness of the dentin, and it was emphasized that it could be a danger zone. Lower taper systems have been

recommended to prevent the risk of perforation and root fracture. Using fresh instruments and observing distortions on the files will reduce the possibility of fracture (46).

Retreatment

The possibility of the presence of second or third canals should be considered in endodontic failure of mandibular premolars (Fig. 20). Lack of treatment for additional root canals is one of the major factors in the development of apical periodontitis. In mandibular premolars with a complex root canal system, some signs are examined to diagnose the missed canal. In some cases, the presence of the untreated canal is visible on the radiography (Fig. 21). In some cases, the second canal may be seen, although less clearly (Fig. 22).

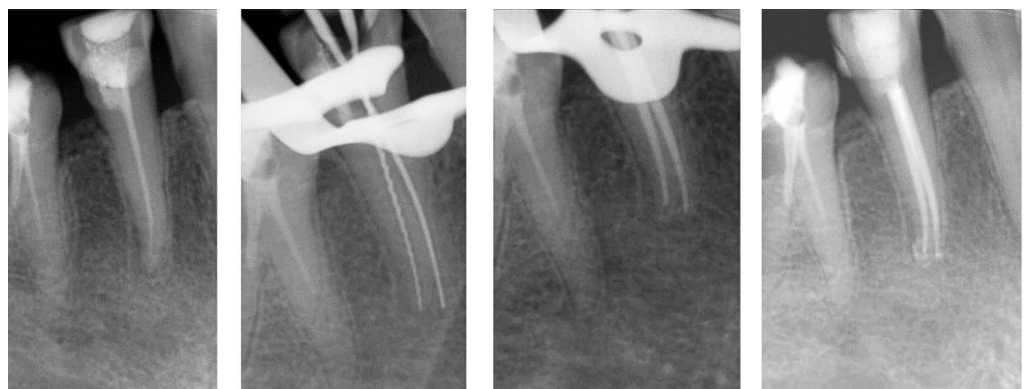
Another sign of the presence of a missed lingual canal in mandibular premolars that previously performed RCT is the eccentric placement of the canal filling in the treated buccal canal (Fig. 23 and 24). Since the canal is in the center of the root in 1-canalled mandibular premolars, root canal filling is seen in the center of the root in straight and angled radiographs. Root canal filling located towards 1 side of the root is a clue that only one canal has been treated.

Conclusion

Complicated root and canal patterns are frequently encountered in mandibular premolars. Some clinical and radiograph-

Figure 20

One of the major causes of endodontic failure in mandibular premolars is untreated lingual canals.



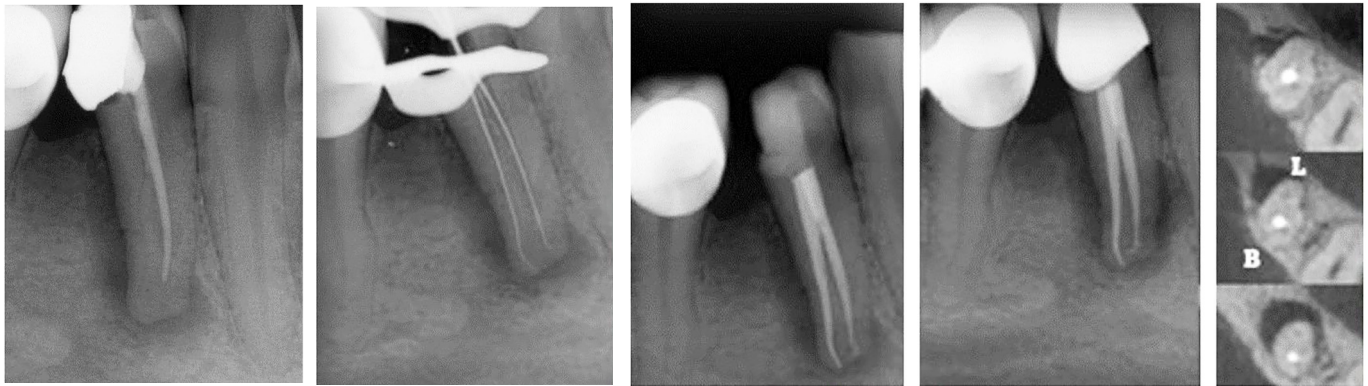


Figure 21
RCT of a mandibular second premolar with 2 canals in which the lingual canal is omitted. The lingual canal can be observed on the pre-treatment radiography.

ic signs should be evaluated to diagnose supplemental root canal configurations. In teeth with wider crown widths, the number of roots and canals and the possibility of exhibiting complex canal features may increase. Lingual tubercle variations (absence of tubercle in the lingual region, presence of 1-, 2-, or 3-tubercle in the lingual, and size differences of buccal/lingual tubercles) may be indicators of root canal multiplicity. There are significant correlations between radicular grooves and a variety of root canal configurations.

Moreover, a broad spectrum of morphological deviation and a C-shaped root canal system are observed in mandibular premolars with radicular grooves. Radicular grooves usually present as a radiolucent parapulpal line on radiograph. Periapical radiography is the one of the most effective diagnostic methods for mandibular premolar root canal abnormalities. The presence of a double shadow of the periodontal ligament and the observation of the periodontal ligament space on both sides of the root are features to be evaluated along the

Figure 22
A mandibular first premolar that treatment of the lingual canal was missed. In the initial periapical X-ray, after the incomplete gutta-percha level, both canals can be observed as vague.

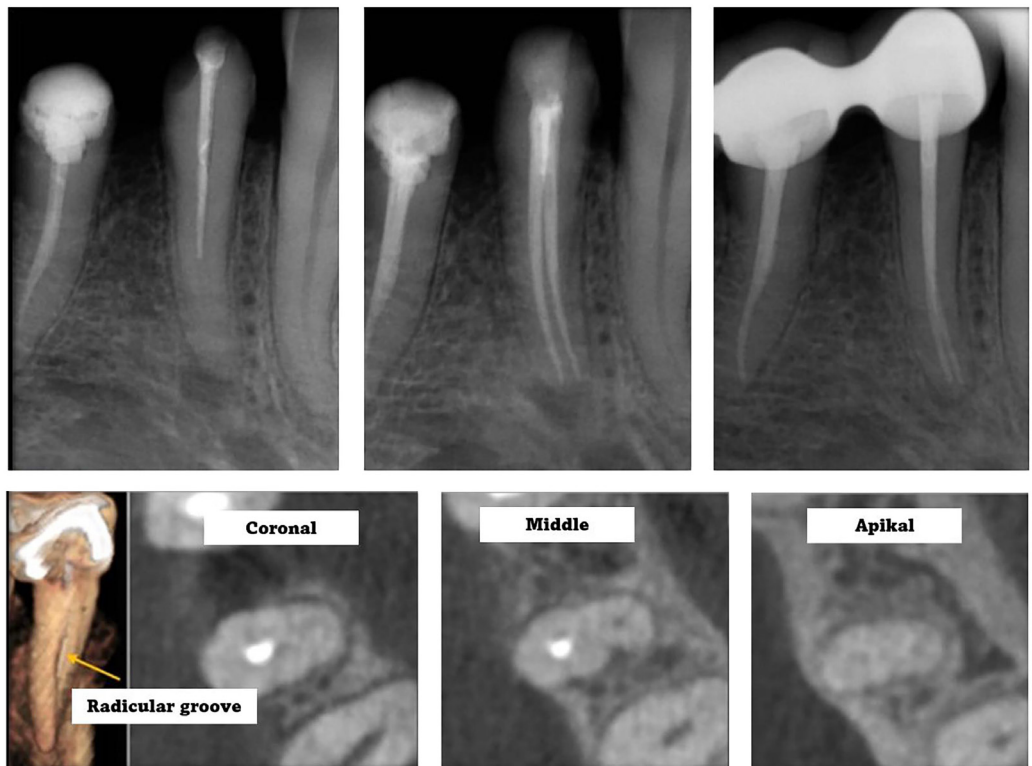


Figure 23

Retreatment of a mandibular first premolar. **A)** Initial periapical radiograph, **B)** post-operative periapical radiograph, and **C)** 6-month follow-up. In the initial periapical radiograph, the eccentric location of gutta-percha (yellow arrow) and the radicular groove (black arrow) are signs of the presence of the second canal.

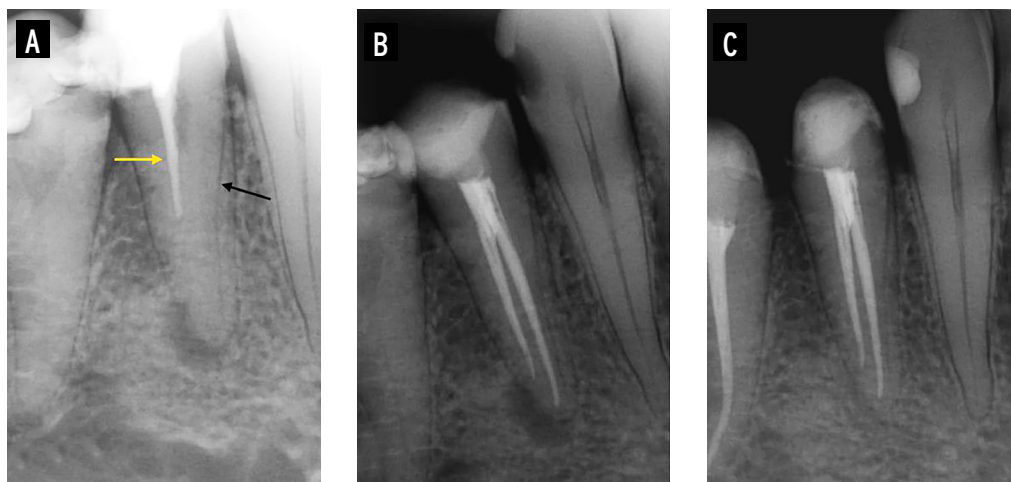
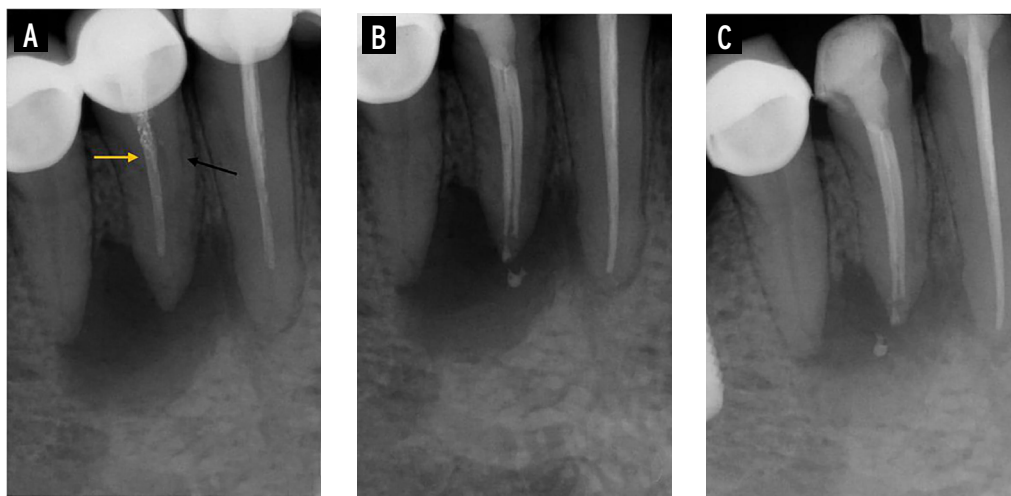


Figure 24

RCT of the mandibular first premolar with a large cyst-like periapical lesion. **A)** Pre-operative X-ray, **B)** post-operative X-ray, and **C)** 3-month follow-up film. Initial periapical radiograph shows inadequate and eccentrically located canal filling. Eccentric placement of gutta-percha is a finding observed in 2-canal teeth (yellow arrow). Additionally, the presence of a radicular groove is another radiographic sign (black arrow). These findings indicate the existence of a second canal.



contours of the root. Taking multiple radiographs from different angles, sudden narrowing or even disappearance of the root canal, and the eccentric position of the root canal files are important radiographic findings. Additionally, CBCT method can provide more specific information regarding the teeth. As a result, to recognize complicated root canal morphology will enhance the reduction of endodontic treatment iatrogenic errors and mishaps.

Clinical Relevance

In mandibular premolars, the presence of a complicated root canal system can be understood before or during root canal treatment with comprehensive information

and careful clinical and radiographic examinations.

Conflict of Interest

The authors declared no conflict of interest.

Acknowledgements

The Authors declare that they have no funding.

References

- 1 Aydin H. Correlations between additional roots in maxillary second molars, maxillary first premolars, mandibular first molars and mandibular first premolars: a retrospective cone-beam computed tomography analysis. *Odontology* 2022;110:584-95.
- 2 Tzanetakis GN, Lagoudakos TA, Kontakiotis EG.

- Endodontic Treatment of a Mandibular Second Premolar with Four Canals Using Operating Microscope. *J Endod* 2007;33:318-21.
- 3 Martins JNR, Gu Y, Marques D, et al. Differences on the root and root canal morphologies between Asian and white ethnic groups analyzed by cone-beam computed tomography. *J Endod* 2018;44:1096-104.
 - 4 Cleghorn BM, Christie WH, Dong CCS. Anomalous mandibular premolars: A mandibular first premolar with three roots and a mandibular second premolar with a C-shaped canal system. *Int Endod J* 2008;41:1005-14.
 - 5 Aydın H, Çiloğlu Ö. Relationship between root canal merging and presence of C-shaped canal in fused rooted maxillary molar teeth. *Braz Dent Sci* 2022;25:e2964.
 - 6 Kaya Büyükbayram I, Sübay RK, Çolakoğlu G, et al. Investigation using cone beam computed tomography analysis, of radicular grooves and canal configurations of mandibular premolars in a Turkish subpopulation. *Arch Oral Biol* 2019;107:104517.
 - 7 Fan B, Yang J, Gutmann JL, et al. Root canal systems in mandibular first premolars with C-shaped root configurations. Part 1: microcomputed tomography mapping of the radicular groove and associated root canal cross-sections. *J Endod* 2008;34:1337-41.
 - 8 Borna Z, Rahimi S, Shahi S, et al. Mandibular second premolars with three root canals: a review and 3 case reports. *Iran Endod J* 2011;6:179-82.
 - 9 Zoya-Farook A, Abhishek P, Shahabadi A. Cone-beam computed tomographic evaluation and endodontic management of a mandibular first premolar with Type IX canal configuration: case report. *J Endod* 2017;43:1207-13.
 - 10 Zhang M, Xie J, Wang YH, et al. Mandibular first premolar with five root canals: a case report. *BMC Oral Health* 2020;20:253.
 - 11 Nouroloyouni A, Lotfi M, Salem Milani A, et al. Endodontic management of a two-rooted mandibular first premolar with five root canals with cone-beam computed tomography: a case report. *J Dent (Shiraz)* 2021;22:225-8.
 - 12 Al-Mahroos NAE, Al-Mahroos SAE, Al-Shahrani S. Management of mandibular premolars with various C-shaped root canal configurations: a case series. *Saudi Endod J* 2022;12:322-30.
 - 13 Martins JNR, Zhang Y, von Zuben M, et al. Worldwide prevalence of a lingual canal in mandibular premolars: a multicenter cross-sectional study with meta-analysis. *J Endod* 2021;47:1253-64.
 - 14 Ok E, Altunsoy M, Nur BG, et al. A cone-beam computed tomography study of root canal morphology of maxillary and mandibular premolars in a Turkish population. *Acta Odontol Scand* 2014;72:701-6.
 - 15 Chen YC, Tsai CL, Chen YC, et al. A cone-beam computed tomography study of C-shaped root canal systems in mandibular second premolars in a Taiwan Chinese subpopulation. *J Formos Med Assoc* 2018;117:1086-92.
 - 16 Kottoor J, Albuquerque D, Velmurugan N, et al. Root anatomy and root canal configuration of human permanent mandibular premolars: a systematic review. *Anat Res Int* 2013;22:1-14.
 - 17 Karobari MI, Assiry AA, Lin GSS, et al. Roots and root canals characterization of permanent mandibular premolars analyzed using the cone beam and micro computed tomography-a systematic review and metanalysis. *J Clin Med* 2023; 12: 2183.
 - 18 Wolf TG, Anderegg AL, Wierichs RJ, et al. Root canal morphology of the mandibular second premolar: a systematic review and meta-analysis. *BMC Oral Health* 2021; 21: 309.
 - 19 Martins JNR, Marques D, Silva EJNL, et al. Prevalence studies on root canal anatomy using cone-beam computed tomographic imaging: a systematic review. *J Endod* 2019; 45: 372-86.
 - 20 Aydın H. Comparing the crown and root metric properties of double-rooted and single-rooted mandibular canine teeth. *Oral Radiol* 2023;39:301-11.
 - 21 Aydın H. Relationship between crown and root canal anatomy of four-rooted maxillary molar teeth. *Aust Endod J* 2020;47:298-306.
 - 22 Aydın H, Mobaraki S. Comparison of root and canal anatomy of taurodont and normal molar teeth: a retrospective cone-beam computed tomography study. *Arch Oral Biol* 2021;130:105242.
 - 23 Mohsen R. Metric and non-metric dental traits of premolars with root canals configuration among the Egyptians. *Egypt Dent J* 2023;69:1025-47.
 - 24 Ordinola-Zapata R, Monteiro Bramante C, Gagliardi Minotti P, et al. Micro-CT evaluation of C-shaped mandibular first premolars in a Brazilian subpopulation. *Int Endod J* 2015;48:807-13.
 - 25 Turner II CG, Nichol CR, Scott GR. Scoring procedures for key morphological traits of the permanent dentition: the Arizona State University dental anthropology system. In: Kelly MA, Larsen CS (eds.) *Advances in dental anthropology*. New York: Wiley-Liss Inc; 1991. p. 13-31.
 - 26 Gu Y, Zhang Y, Liao Z. Root and canal morphology of mandibular first premolars with radicular grooves. *Arch Oral Biol* 2013;58:1609-17.
 - 27 Boschetti E, Silva-Sousa YTC, Mazzi-Chaves JF, et al. Micro-CT evaluation of root and canal morphology of mandibular first premolars with radicular grooves. *Braz Dent J* 2017;28:597-603.
 - 28 Guerreiro D, Shin JM, Pereira M, et al. Radicular Groove Accessory canal morphology in mandibular first premolars: micro-computed tomographic study. *J Endod* 2019;45:554-9.
 - 29 Scott GR, Pilloud MA. *Dental Morphology*. In: *Biological Anthropology of the Human Skeleton*. Hoboken, NJ, USA: John Wiley & Sons, Inc.;2018. p.257-92.
 - 30 Scott GR, Maier C, Heim K. Identifying and Recording Key Morphological (Nonmetric) Crown and Root Traits. In: *A Companion to Dental Anthropology*. Wiley;2015.p.245-64.
 - 31 Fan B, Ye W, Xie E, et al. Three-dimensional morphological analysis of C-shaped canals in mandibular first premolars in a Chinese population. *Int Endod J* 2012;45:1035-41.
 - 32 Chen J, Li X, Su Y, et al. A micro-computed tomography study of the relationship between radicular grooves and root canal morphology in mandibular first premolars. *Clin Oral Investig* 2015;9:329-34.
 - 33 Martins JNR, Francisco H, Ordinola-zapata R. Prevalence of C-shaped configurations in the mandibular first and second premolars: a cone-beam computed tomographic in vivo study. *J Endod* 2017;43:890-5.
 - 34 Gu YC, Zhang YP, Liao ZG, et al. A micro-computed



- tomographic analysis of wall thickness of c-shaped canals in mandibular first premolars. *J Endod* 2013;39:973-6.
- 35 Liu N, Li X, Liu N, et al. A micro-computed tomography study of the root canal morphology of the mandibular first premolar in a population from southwestern China. *Clin Oral Investig* 2013;17:999-1007.
- 36 Aydın H. Analysis of root and canal morphology of fused and separate rooted maxillary molar teeth in Turkish population. *Niger J Clin Pract* 2021;24:435-42.
- 37 Ring J, Ring KC. Rare Root canal configuration of mandibular second premolar using cone-beam computed tomographic scanning. *J Endod* 2017;43:1897-900.
- 38 Ordinola-Zapata R, Bramante CM, Villas-Boas MH, et al. Morphologic micro-computed tomography analysis of mandibular premolars with three root canals. *J Endod* 2013;39:1130-5.
- 39 Er K, Kuştarci A, Özan Ü, et al. Nonsurgical endodontic treatment of dens invaginatus in a mandibular premolar with large periradicular lesion: a case report. *J Endod* 2007;33:322-4.
- 40 Aydın H, Er K, Kustarci A, et al. Root canal treatment of a supernumerary tooth fused with a mandibular premolar: a case report. *Clin Dent Res* 2017;41:43-8.
- 41 Lotfi M, Vosoughhosseini S, Zand V, et al. A mandibular second premolar with three canals and atypical orifices. *J Oral Sci* 2008;50:363-6.
- 42 Sun Y, Lu TY, Chen YC, et al. The best radiographic method for determining root canal morphology in mandibular first premolars: a study of Chinese descendants in Taiwan. *J Dent Sci* 2016;11:175-81.
- 43 Martínez-Lozano MA, Forner-Navarro L, Sánchez-Cortés JL. Analysis of radiologic factors in determining premolar root canal systems. *Oral Surg Oral Med Oral Pathol Oral Radiol Endod*. 1999;88:719-22.
- 44 Li X, Liu N, Liu N, et al. A micro-computed tomography study of the location and curvature of the lingual canal in the mandibular first premolar with two canals originating from a single canal. *J Endod* 2012;38:309-12.
- 45 Yoshioka T, Villegas JC, Kobayashi C, et al. Radiographic evaluation of root canal multiplicity in mandibular first premolars. *J Endod*. 2004;30:73-4.
- 46 Solete P, Antony SPD, Teja KV, et al. Endodontic management of aberrant canal morphology in mandibular premolar: a case series. *J Conserv Dent* 2023;26:236-40.
- 47 Sousa TO, Haïter-Neto F, Nascimento EHL, et al. Diagnostic accuracy of periapical radiography and cone-beam computed tomography in identifying root canal configuration of human premolars. *J Endod* 2017;43:1176-9.
- 48 Albuquerque D, Kottoor J, Hammo M. Endodontic and clinical considerations in the management of variable anatomy in mandibular premolars: a literature review. *Biomed Res Int* 2014;2014:512574.
- 49 Cerqueira NM, Louzada VG, Silva-Sousa YTC, et al. Effect of canal preparation with XP-endo Shaper and ProTaper Next on root canal geometry and dentin thickness of mandibular premolars with radicular grooves and two canals: a micro-CT study. *Clin Oral Investig* 2021;25:5505-12.