

## CASE REPORT

# Treatment planning and therapy of a severely compromised two-rooted maxillary central incisor

## ABSTRACT

**Aim:** This case report presents the diagnosis and therapy of a severely compromised two-canal maxillary central incisor.

**Summary:** Tooth #21 was referred for treatment. 2D and 3D Radiographic evaluation revealed the presence of a severely compromised two-canal central incisor. Root canal therapy was performed. In the two-year follow-up the tooth was fully functional.

**Key learning points:**

- Meticulous treatment planning and treatment is a valid option even in complicated and compromised cases.
- Root canal treatment can provide concrete therapeutical choices even in heavily compromised cases.

Andreas Krokidis<sup>1\*</sup>

Antonio Cerutti<sup>2</sup>

<sup>1</sup>National and Kapodestrian University of Athens, Department of Endodontics, Greece

<sup>2</sup>Department of Restorative Dentistry, Università degli Studi di Brescia, Italy,

Received 2023, November 8

Accepted 2024, January 8

**KEYWORDS** Two-canal central incisor, CBCT, root canal treatment

**Corresponding Author**

Andreas Krokidis | 77 Vas Sofias avenue, 11521, Athens | Greece  
Tel. +306945659915 Email: endokrokidis@gmail.com

Peer review under responsibility of Società Italiana di Endodonzia

10.32067/GIE.2024.38.01.01

Società Italiana di Endodonzia. Production and hosting by Ariesdue. This is an open access article under the CC BY-NC-ND license (<http://creativecommons.org/licenses/by-nc-nd/4.0/>).

## Introduction

The major goal of endodontic therapy is to three-dimensionally shape, disinfect, and obturate the canal system in order to promote healing of the periapical tissues (1). Clinicians are expected to treat the entire canal system, necessitating robust knowledge of endodontic anatomy. The most common reason of failure is untreated anatomy and is more common in the maxillary molars and mandibular premolars (2).

In the literature, maxillary central incisors are usually referenced as single-rooted teeth (3-5).

The anatomic variation of two roots in a central incisor is rare and sometimes difficult to diagnose. Some cases of two-rooted maxillary central incisors have been reported in the past (6-20). Comprehensive diagnosis and treatment planning are fundamental in these cases for a successful outcome. Nevertheless, in none of the cases previously reported in the literature, the state of the tooth under treatment has been that compromised, as the present case report. As it will be described, in addition to the severe conditions of the tooth treated below, (necrotic pulp, abscess, high mobility, and loss of buccal bone plate) the rare anatomic configuration describes an interesting case report demonstrating the range of action of endodontics and the effectiveness of endodontic treatment in combination to a correct diagnosis and treatment plan.

In the present case, non-surgical endodontic treatment of a severely compromised two-rooted maxillary central incisor was completed.

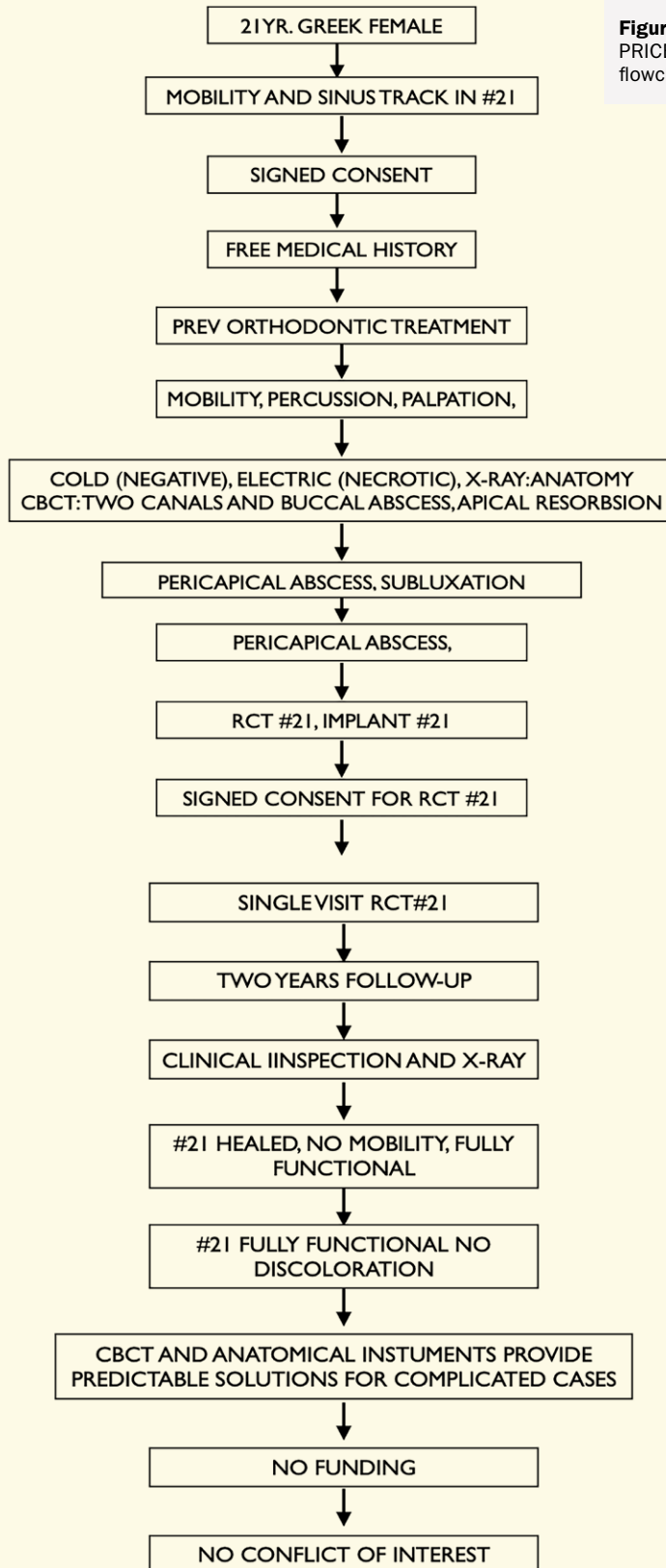
This case report has been written according to Preferred Reporting Items for Case reports in Endodontics (PRICE) 2020 guidelines (21). PRICE flowchart (Figure 1) and PRICE checklist were followed. The patient was fully informed and agreed for the treatment.

## Report

A 21-year-old female Greek patient was referred for the evaluation of a central incisor due to mobility and a fistula present in the buccal area of the #21. The patient had previously completed orthodontic therapy, after which a fixed retainer was placed lingual to the six maxillary anterior teeth. She reported a history of trauma with a fork, after which she began experiencing mobility of the tooth and sensitivity while eating. Clinical evaluation revealed that tooth #21 presented with grade III mobility, pain upon palpation and percussion, and no response to cold or hot stimuli. Furthermore, an active sinus tract was present clinically in the area corresponding with the apex of tooth #21.

Radiographic evaluation with intraoral radiographs revealed the presence of a periradicular lesion in the mesial part of the root, corresponding to irregular anatomy in the same area. The presence also of apical root resorption was evident (Figure 2A). In order to further evaluate the periradicular lesion and the anatomy of the canal system, cone-beam computed tomography (CBCT) was advised. An evaluation of the CBCT images revealed a bifurcation of the root in the medial and apical third into two different roots. The mesio-buccal root appeared to be shorter resorbed apically and with a periapical lesion which was perforating the buccal bone, which made the prognosis of endodontic treatment much worse than initially believed. Each root presented one individual canal, so from the main canal in the coronal area was dividing into two individual canals with exits (Figure 3A-3E). Since no evidence of previous carious lesions were found, the pathology might have occurred due to intense orthodontic movement or a previous trauma which the patient did not recall. The treatment options were either to treat endodontically, or proceed with extraction and restore the #21 area either with a fixed partial bridge or placing an implant.

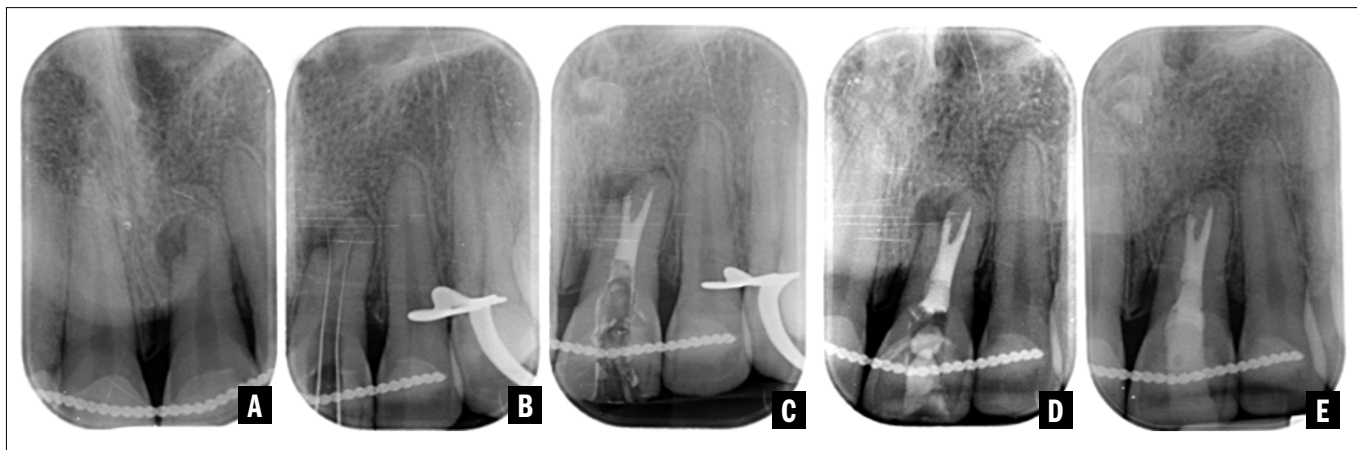
The patient was informed about the overall condition of the tooth and the



**Figure 1**  
PRICE  
flowchart.

treatment alternatives. The two more effective and suitable treatment plans were, extraction and implant placement, or root canal therapy in order to maintain the tooth or in the worst case scenario, considering the state of compromise of the whole area of the #21, provide better conditions for a future implant placement (22). She elected to proceed with the more conservative treatment option of saving tooth #21 with a root canal treatment and repositioning of the orthodontic palatal splint, which was broken.

The tooth was anaesthetised, and isolation was achieved by placing a rubber dam over the six maxillary anterior teeth and then isolating the palatal of tooth #21 with a chemical dam. Access was gained with a long round bur mounted in a high speed handpiece. The pulp chamber was found to be dark, characteristic finding of teeth with necrotic pulp, and as expected, void of biological content. Through scouting with a 10k file, the main canal exit was located, and the working length was measured with the use of an apex locator (Morita Root ZX, Tokyo, Japan). Afterwards, the hand file was pre-shaped in the last one millimetre, and the lateral walls were precisely scouted to locate and enter the second mesio-buccal canal of the tooth. The working length of the second canal was also measured with an apex locator. K-files were used to radiographically confirm the working length (Figure 2B). Chemomechanical preparation of both canals was performed with 35.04 rotary files (Race Evo, FKG Dentaire, LaChaux de Font, Switzerland). The root canals were copiously irrigated with a 5.25% sodium hypochlorite solution in a Luer lock syringe with an Iriflex (PD, Le Lochle, Switzerland) needle. A premixed calcium hydroxide paste was placed into the canals (Multi-Cal, Pulpdent, Watertown, USA) for a week. During the second appointment, calcium hydroxide was removed with an Xp Endo Finisher at 1000 rpm/1 Ncm (FKG Dentaire, LaChaux de Font, Switzerland); then, the same file was used to activate a



**Figure 2**  
**A)** Preoperative radiograph:  
**B)** working length,  
**C)** obturation, **D)** obturation  
 with temporary filling, **E)**  
 two-year follow-up.

5.25% sodium hypochlorite solution for 30 sec. Afterwards, the canals were irrigated for 2 min with 17% EDTA, which was also activated for 30 sec. The final irrigation was performed with sodium hypochlorite for 3 min. Gutta percha cones were fitted, and the canals were dried with paper cones.

A bioceramic sealer was placed in the canal space (Totalfill BC sealer, FKG Dentaire, LaChaux de Font, Switzerland), and then the cones were inserted and cut in the canal orifice using a cold hydraulic technique. (Figure 2C) A temporary filling was placed (Figure 2D), and the patient was referred back to her general dentist for the final restoration and repositioning of the orthodontic splint. Since there were no complaints and due to the restrictions of the COVID-19 pandemic, the follow-up was performed after two years. Clinically, the tooth was functional and stable, and the lesion demonstrated radiographic healing (Figure 2E). After the finishing the treatment and until the follow-up, the patient did not experience any pain or discomfort in the area. In the two year follow-up no discoloration was evidenced in the tooth #21.

### Discussion

The central incisor is typically considered a simple tooth to treat endodontically. Even though the canal space may be excessively wide or narrow due to a

history of trauma, the presence of two root canals is rare but must be taken into consideration to avoid a negative outcome. Clinicians should be able to evaluate the case and prepare for anatomical anomalies (23).

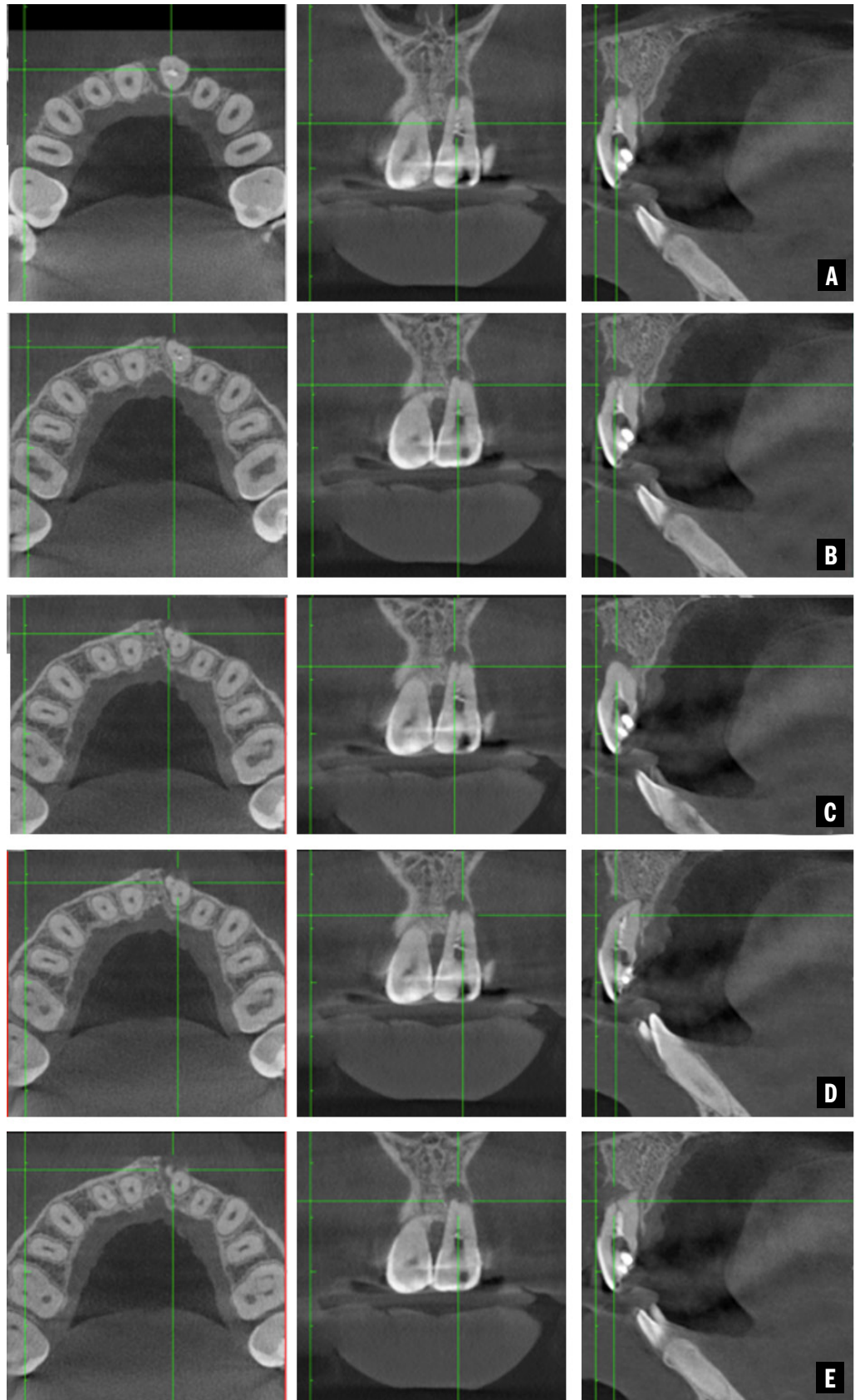
Even though the case report is weak of evidence (24), anatomical variabilities are always important to be reported since as mentioned before the main cause of endodontic failure is untreated anatomy (2). After two years of follow-up the tooth presented mobility was absent and periodontal probings measured 3-5 mm (mesial) in the circumference of the tooth. These clinical findings in combination to the radiographic exam, confirmed the healing of the treated tooth. Nonetheless follow-up must continue until at least four years (25). It might be of a great interest also to evidence a three dimensional healing through a second CBCT image, but because of the age of the patient and the absence of other indications this might not be necessary.

### Conclusion

In complex cases, treatment planning is fundamental after assessing all the necessary information. In particular, radiographic imaging is essential for the initial evaluation of an endodontic case. In the majority of cases, two-dimensional intraoral radiographs are adequate to assess intracanal anatomy. However, cases with anatomical irregularities or

**Figure 3**

CBCT slices (sagittal, axial and coronal) from the mesial third of #21 (A) to apical third (E). The bifurcation of #21 is evident after figure C.





pathologies require the use of CBCT for three-dimensional imaging. CBCT imaging helps assess the anatomy of the canal system and the condition of the periapical tissues (26-29).

Although in many cases, irregularities in the number and shape of the roots are bilateral (30), in the present case, the contralateral central incisor (tooth #11) presented with no anatomical variations upon evaluation by CBCT. Thus, the abnormal anatomy of the central incisor was unilateral in this case.

In addition, the crown of the tooth was normal in shape and identical to the shape of the contralateral central incisor (31). Thus, developmental abnormalities such as gemination and fusion were ruled out. This case report highlights the importance of treatment planning and meticulous evaluation of the initial internal anatomy of the root canal before initiating endodontic therapy. It is well known that the internal anatomy of each individual tooth is unique, and this must always be taken into consideration while treating a root canal space. Within the limitations of this report, it is important to highlight the ability of the root canal treatment to maintain, heavily compromised anatomically unique teeth.

### Clinical Relevance

Meticulous treatment planning and the use of all diagnostic means available, are fundamental for a successful and predictable treatment.

### Conflict of Interest

None.

### Acknowledgements

Written informed consent was obtained from the patient to publish this report in accordance with the journal's patient consent policy.

### References

- AAE Clinical Practice Committee. *Guide to Clinical Endodontics*. 2013;6th ed. AAE.
- Song M, Kim HC, Lee W, Kim E. Analysis of the Cause of Failure in Nonsurgical Endodontic Treatment by Microscopic Inspection during Endodontic Microsurgery. *Journal of Endodontics*; 2011;37:11: 1516-9.
- Vertucci FJ. Root canal anatomy of the human permanent teeth. *Oral Surgery Oral Medicine Oral Pathology*; 1984;58: 589-9.
- Pineda F, Kuttler Y. Mesiodistal and buccolingual roentgenographic investigation of 7,275 root canals. *Oral Surgery Oral Medicine Oral Pathology*; 1972;33:101-10.
- Calışkan MK, Pehlivan Y, Sepetçioğlu F, Türkün M, Tuncer SS. Root canal morphology of human permanent teeth in a Turkish population. *Journal of Endodontics*;1995; 21:200-4.
- Patterson JM. Bifurcated root of upper central incisor. *Oral Surgery Oral Medicine Oral Pathology*; 1970;29: 222.
- Heling B. A two-rooted maxillary central incisor. *Oral Surgery Oral Medicine Oral Pathology*; 1977;43: 649.
- Mader CL, Konzelman JL. Double-rooted maxillary central incisor. *Oral Surgery Oral Medicine Oral Pathology*; 1980;50:99.
- Sinai IH, Lustbader S. A dual-rooted maxillary central incisor. *Journal of Endodontics*;1984; 10:105-6.
- Libfeld H, Stabholz A, Friedman S. Endodontic therapy of bilaterally geminated permanent maxillary central incisors. *Journal of Endodontics*;1986; 12:214-6.
- Michanowicz AE, Michanowicz JP, Ardila J, Posada A. Apical surgery on a two-rooted maxillary central incisor. *Journal of Endodontics*;1990;16:4545.
- Al-Nazhan S. Two root canals in a maxillary central incisor with enamel hypoplasia. *Journal of Endodontics*; 1991;17:469-71.
- Lambruschini GM, Camps J. A two-rooted maxillary central incisor with a normal clinical crown. *Journal of Endodontics*;1993;19:95-6.
- Gonzalez-Plata RR, Gonzalez-Plata EW. Conventional and surgical treatment of a two-rooted maxillary central incisor. *Journal of Endodontics*; 2003;29:422-4.
- Ravindranath M, Neelakantan P, Subba Rao CV. Maxillary lateral incisor with two roots: a case report. *General Dentistry*;2011;59:68-9.
- Ghoddusi J, Zarei M, Vatanpour M. Endodontic treatment of maxillary central incisor with two roots. A case report. *N Y State Dental Journal*;2007;73:46-7.
- Mangani F, Ruddle CJ. Endodontic treatment of a "very particular" maxillary central incisor. *Journal of Endodontics*;1994;20:560-1.
- Genovese FR, Marsico EM. Maxillary central incisor with two roots: a case report. *Journal of Endodontics*;2003;29:220-1.
- Cabo Vale M, Gonzales JM. Maxillary central incisor with two root canals: an unusual presentation. *Journal of Oral Rehabilitation*;2001;28:797-8.
- Cimilli H, Kartal N. Endodontic treatment of unusual central incisors. *Journal of Endodontics*;2022;28:480-1.
- Nagendrababu V, Chong B S , McCabe P , et al. PRICE 2020 guidelines for reporting case reports in Endodontics: a consensus-based development. *International Endodontic Journal*;2020;53:619-626.



- 22 Torabinejad M, et al. Outcomes of root canal treatment and restoration, implant-supported single crowns, fixed partial dentures, and extraction without replacement: A systematic review. *The Journal of Prosthetic Dentistry*; 2007;98: 285-311
- 23 Vertucci FJ. Root canal morphology and its relationship to endodontic procedures. *Endodontic Topics*; 2005;10:3-29.
- 24 Hassan Murad M, Noor Asi A , Mouaz Alsawas. New evidence pyramid. *Evidence Based Medicine*, 2016;21:125-7.
- 25 Peters C I, Peters O A. Cone beam computed tomography and other imaging techniques in the determination of periapical healing. *Endodontic Topics*; 2012;26:1601-153857
- 26 S Patel et al Cone beam computed tomography in Endodontics - a review of the literature. *International Endodontic Journal*; 2019;52(8):1138-1152.
- 27 Patel S,Harvey S Guidelines for reporting on CBCT scans. *International Endodontic Journal*; 2012;54:628-633.
- 28 Shehab Eldin Saber SE, et al Anatomical Analysis of Mandibular Posterior Teeth using CBCT: An Endo-Surgical Perspective *European Endodontic Journal*;2021;6(3):264-270.
29. Abella, F et al (2015). Endodontic applications of cone beam computed tomography: case series and literature review. *Giornale Italiano Di Endodonzia*;2015;29(2),38–50.
- 30 Sabala CL, Benenati FW, Neas BR. Bilateral root or root canal aberrations in a dental school patient population. *Journal of Endodontics*;1994;20:38-42.
- 31 Rajendran A., Sivapathasundharam B. *Shafer's Textbook of Oral Pathology*, 7th ed. India: (2012), Elsevier.