



Available online at www.sciencedirect.com

ScienceDirect

journal homepage: www.elsevier.com/locate/gie



FOCUS

Endodontic applications of cone beam computed tomography: case series and literature review



Applicazioni della tomografia computerizzata a fascio conico in Endodonzia: casi clinici e revisione della letteratura

Francesc Abella*, Kala Morales, Iván Garrido, Javier Pascual, Fernando Duran-Sindreu, Miguel Roig

Department of Restorative Dentistry and Endodontics, Universitat Internacional de Catalunya, Sant Cugat del Vallès, Barcelona, Spain

Received 22 July 2015; accepted 28 July 2015
Available online 26 September 2015

KEYWORDS

Cone beam computed tomography;
Decision-making;
Diagnosis;
Endodontics;
Periapical lesions;
Root canal treatment.

Abstract Cone beam computed tomography (CBCT) is a relatively new method that produces three-dimensional (3D) information of the maxillofacial skeleton, including the teeth and their surrounding tissue, with a lower effective radiation dose than traditional CT scans. Specific endodontic applications for CBCT are being identified as the use of this technology becomes more common. CBCT has great potential to become a valuable tool for diagnosing and managing endodontic problems, as well as for assessing root fractures, apical periodontitis, resorptions, perforations, root canal anatomy and the nature of the alveolar bone topography around teeth. This article aims to review cone beam technology and its advantages over CT scans and conventional radiography, to illustrate current and future clinical applications in endodontic practice, and to highlight areas of further research of CBCT in endodontics. Specific case examples illustrate how treatment planning has changed with the images obtained with CBCT technology compared with only periapical radiography.

© 2015 Società Italiana di Endodonzia. Production and hosting by Elsevier B.V. All rights reserved.

* Corresponding author at: Universitat Internacional de Catalunya, Dentistry Faculty, C/ Josep Trueta s/n, 08195 Sant Cugat del Vallès, Spain. Tel.: +34 504 2000; fax: +34 504 2031.

E-mail: franabella@uic.es (F. Abella).

Peer review under responsibility of Società Italiana di Endodonzia.



Production and hosting by Elsevier

<http://dx.doi.org/10.1016/j.gien.2015.08.002>

1121-4171/© 2015 Società Italiana di Endodonzia. Production and hosting by Elsevier B.V. All rights reserved.

PAROLE CHIAVE

Tomografia computerizzata a fascio conico;
 Processo decisionale;
 Diagnosi;
 Endodonzia;
 Lesioni periapicali;
 Trattamento endodontico.

Riassunto La tomografia computerizzata a fascio conico (CBCT) è un metodo relativamente nuovo che produce informazioni tridimensionali (3D) dello scheletro maxillofaciale, compresi i denti e il loro tessuto circostante, con una dose di radiazione inferiore rispetto alle TC tradizionali. La CBCT può essere utilizzata in Endodonzia per specifiche applicazioni e l'utilizzo di questa tecnologia si sta diffondendo sempre di più. La CBCT ha un grande potenziale per diventare uno strumento prezioso per la diagnosi e la gestione dei problemi endodontici, nonché per valutare le fratture radicolari, la presenza di lesioni periapicali, riassorbimenti, perforazioni, anatomie canalari particolari e la natura della topografia dell'osso alveolare intorno ai denti. Questo articolo si propone di rivedere la tecnologia a fascio conico e i suoi vantaggi rispetto alla TC e radiologia tradizionale, per illustrare le sue applicazioni cliniche attuali e future in endodonzia, e per evidenziare le aree di ulteriore ricerca che potranno caratterizzare la CBCT in endodonzia. Specifici casi clinici illustreranno inoltre come la pianificazione del trattamento sia cambiata grazie alle immagini ottenute con la tecnologia CBCT rispetto alla sola radiografia periapicale.

© 2015 Società Italiana di Endodonzia. Production and hosting by Elsevier B.V. Tutti i diritti riservati.

Introduction

Breakthroughs in diagnostic radiology over the last 30 years have led to the development of new technologies with applications in dentistry. The development of hardware and software has facilitated new approaches to dentomaxillofacial treatment and treatment planning. One such advance is cone beam computed tomography (CBCT).

CBCT imaging is a relatively new method of visualizing an individual tooth or the dentition in relation to the surrounding skeletal tissues that creates three-dimensional (3D) images of the area of interest.^{1,2} This imaging technique is an increasingly used diagnostic tool in endodontic practice.³

In contrast to traditional radiographic methods, which reproduce the 3D anatomy as a two-dimensional (2D) image, CBCT allows the observation of an individual tooth or teeth in any view, rather than in predetermined 'default' views.⁴ Thus, CBCT has the potential to improve diagnosis, treatment planning, and the assessment of the outcome of endodontic treatment. The disadvantage of CBCT is its use of ionizing radiation, which means that clinicians must consider the ALARA principle (as low as reasonably achievable) when using the technique and any other imaging modalities. It is important to appraise the effective radiation dose associated with various imaging modalities, their resolution, and the information they provide to the clinician.⁵

The European Society of Endodontology recommended that CBCT imaging should only be considered if the additional information provided by the reconstructed 3D images would aid diagnosis and/or enhance the management of a tooth with an endodontic problem.⁶ However, the endodontic literature (and all other dental disciplines) is replete with case reports and *ex-vivo* studies, whereas the number of well-designed clinical trials validating the use of CBCT in endodontics is small, which makes a meta-analysis impossible. The aim of this review, therefore, is to present the pertinent literature, highlighting the relative advantages and disadvantages of CBCT, and to discuss its application in the diagnosis, treatment planning and outcome of endodontic treatment.

Cone beam computed tomography

The first prototype CBCT scanner was developed in 1982 for angiographic applications.⁷ A CBCT scanner for dentomaxillofacial use was developed in the late 1990s and, since the very first report,⁸ use of this technique has become widespread in dentistry. Using CBCT, a 3D volume of data is acquired in the course of a single sweep of the scanner. The technique is contingent upon a simple, direct relationship between the sensor and the source, which rotates synchronously 180–360° around the patient's head. The X-ray beam, which is cone-shaped (hence the name of the technique), captures a cylindrical or spherical volume of data, described as the field of view (FOV).⁹ CBCT devices are divided into four subcategories:¹⁰ dentoalveolar (FOV < 8 cm); maxillomandibular (FOV 8–15 cm); skeletal (FOV 15–21 cm); and head and neck (FOV > 21 cm).

Effective radiation dose

One of the major advantages of CBCT over computed tomography (CT) is the significantly lower effective radiation dose to which patients are exposed.⁹ The effective dose of CBCT scanners may vary, but it can be almost as low as that of a panoramic dental X-ray.^{11–14} The dose depends on the region of the jaw to be scanned, the exposure settings of the CBCT scanner, the size of the FOV, the exposure time(s), the tube current (mA) and the energy/potential (kV)^{15,16}. The radiation dose can be reduced using a smaller FOV, fewer projections (180°) and a bigger voxel size.^{17,18}

For endodontic applications, the FOV should be limited to the region of interest; that is, the FOV should encompass the tooth (or teeth) under investigation and the surrounding structures. This is an effective way to reduce the radiation dose.¹ The radiation dose of a small-volume CBCT scanner is comparable to that of 2–7 standard periapical radiographs (PRs), whereas the radiation dose of a large-volume scanner is similar to that of a full-mouth series of PRs.^{17,19} The tube current (mA) selected should be as low as possible, so that the image produced is of sufficient diagnostic yield even

though this may result in a degree of noise.⁴ Whenever possible, the mA and exposure times should be reduced.¹⁸ The voxel size used in CBCT is often a device-related compromise. Reducing voxel size beyond that required to produce reconstructed images of a sufficient yield should be avoided to prevent unnecessarily high radiation doses.⁴

An accepted compromise between radiation dose and image quality must be reached to adhere to the ALARA principle.²⁰ This is especially relevant when assessing children, who are more susceptible to the potential effects of ionizing radiation.²¹ At all ages, the associated risks for women are slightly higher than those for men. Therefore, exposure of a patient to ionizing radiation must never be considered routine. Furthermore, CBCT operators must be adequately trained in CBCT radiology and in the interpretation of the images obtained, because both differ substantially from conventional radiography.²

Drawbacks and limitations of cone beam computed tomography

Despite the obvious advantages that CBCT offers in dentistry, the technology has drawbacks and limitations. At present, CBCT systems have significantly lower spatial resolution than PRs (15–20 lines per mm),^{22,23} but the resolution of the reconstructed scans is improving as new systems are developed.

A significant problem affecting the image quality and diagnostic accuracy of CBCT images is the scatter and beam hardening caused by high-density neighbouring structures and materials.^{24,25} If the scattering and beam hardening is close to or associated with the tooth under assessment, the resulting CBCT images may be of minimal diagnostic value.²⁶ Crowns, bridges, implants, fillings and intracanal posts can mimic endodontic complications or hide existing ones.^{27,28} Ritter et al.²⁸ determined the influence of patients' age, sex, body mass index, and existing dental restorations and implants on the image quality of CBCT. The authors concluded that the patient's age and the number of existing dental restorations have a negative impact on CBCT image quality. However, further studies are required to identify the factors associated with age that influence the quality of CBCT images.

Clinical applications of cone beam computed tomography in endodontics

The radiographic examination is an essential part of endodontic management, from the initial diagnosis to the assessment of treatment outcome. CBCT overcomes several limitations of conventional radiography.^{2,9,14} For example, the spatial relationship of the roots of multi-rooted teeth can be visualized in 3D²⁵ and the true size and 3D nature of periapical lesions can also be assessed.^{1,9} CBCT technology aids the diagnosis of endodontic pathosis and root and alveolar fractures, the assessment of canal morphology, the analysis of resorptive lesions, the identification of pathosis of non-endodontic origin, the evaluation of root canal preparation and filling and the pre-surgical assessment necessary for root-end surgery.

Evaluation of root canal anatomy and complex morphology

Anatomical variations exist with each type of tooth.^{29,30} The 2D nature of PRs does not consistently reveal the true number of canals present in teeth. The interpretation of an image can be confounded not only by the anatomy of its surrounding structures but also by that of the teeth themselves. In an *ex-vivo* investigation, Matherne et al.³¹ compared the ability of charge-coupled device and photostimulable phosphor plate digital radiography systems and CBCT to detect the number of root canals in 72 extracted teeth. This study found that, with digital radiography, endodontists failed to identify at least one root canal in 40% of teeth, despite using a parallax technique. However, it should be taken into account that the teeth were not sectioned to confirm the true number of root canals.

Mandibular first molars display several anatomical variations. The major variant in this type of tooth is the occurrence of a supernumerary (distolingual [DL]) root.^{32,33} In rare cases, an additional root may occur at the mesiobuccal (MB) side, known as a radix paramolaris.³⁴ According to a recent review, the frequency of mandibular first molars with DL roots is 14.4% and ethnicity is a predisposing factor for this anatomical variation.³⁵ Tu et al.,^{36,37} who investigated the apparent prevalence of DL roots identified with PRs and CBCT, observed prevalences of 21% and 33%, respectively. In conclusion, multiple PRs (especially the 25° mesial tube shift) or CBCT are required to assess the presence of DL roots.³⁵

Complex anatomy often occurs in the mesial root of mandibular molars.³⁸ Few clinical studies have investigated the prevalence of an isthmus between the MB and mesiolingual canals, which can be instrumented to length.^{39–42} Despite reports of a high prevalence of intercanal communications in mandibular molars,^{43,44} the success rate of locating and accessing a middle mesial root canal is low, ranging from 1% to 46%.^{39,40,42,45} In an *in-vitro* study, de Toubes et al.⁴⁶ compared CBCT with clinical inspection, digital radiography and operating microscope methods in the identification of middle mesial canals in mandibular first molars. Their results demonstrated that, unlike parallax digital radiography, which was deemed unreliable, there was good agreement between CBCT and the dental operating microscope in detecting accessory mesial canals.

Different studies have used CBCT to study the root canal morphology of maxillary molars.^{47,48} Blattner et al.⁴⁷ assessed the prevalence of second MB canals in extracted maxillary first and second molars *in vitro*. The teeth were sectioned axially to confirm the true number of root canals. In total, an 80% correlation was reported between CBCT findings and the results obtained by tooth sectioning. Neelakantan et al.⁴⁸ compared the efficacy of six methods (modified canal staining and clearing, CBCT, peripheral quantitative CT, spiral CT, digital radiography and contrast medium-enhanced digital radiography) in identifying the root canal systems of 95 teeth. Their results showed that CBCT was as accurate as the gold standard (a modified canal-staining and clearing technique). Moreover, as in previous studies,^{47,49,50} the level of interexaminer and intraexaminer agreement was significantly higher with CBCT (and the other 3D imaging systems) than with PRs.

3D reconstructions of CBCT images allow clinicians to fully appreciate the internal endodontic anatomy of the root canal

system in each type of tooth.^{51–54} Prior knowledge of the number of root canals and their location results in predictable identification of all root canal orifices.^{4,6,35} CBCT is also invaluable for assessing teeth with uncommon anatomy, such as teeth with an unusual number of roots, dilacerated teeth, teeth exhibiting dens invaginatus (Fig. 1), teeth with C-shaped canals and fused teeth.^{5,55} However, CBCT should be reserved for select cases where the root canal anatomy cannot be fully appreciated with conventional PRs and the dental operating microscope.^{4,6}

Detection of apical periodontitis

Periapical radiolucency, detected on PRs or by reconstructed scans obtained using CBCT, is a common sign of apical periodontitis.^{56,57} This lesion is commonly caused by bone resorption triggered by the host response to bacteria inside the root canal system.⁵⁸ A periapical lesion is defined as periapical radiolucency connected with the apical part of a root that exceeds at least twice the width of the periodontal ligament space.^{59,60}

Bender and Seltzer^{61,62} and Schwarz and Foster⁶³ showed that the size of the periapical lesion is often underestimated using PRs. CBCT enables the detection of radiolucent endodontic lesions before the lingual or buccal plate is demineralized.^{1,2,14} Use of CBCT eliminates the superimposition of anatomical structures and is useful in identifying

processes occurring within the cancellous bone.² Both *in-vitro*^{2,64} and *in-vivo*^{14,26,48,49,59,65–67} studies have shown that CBCT detects periapical lesions more effectively than PRs. Two studies^{2,68} have been undertaken to investigate whether CBCT-detected lesions are true lesions. de Paula-Silva et al.⁶⁸ examined the periapical area of 83 treated or untreated roots in dogs' teeth. Each root in which a periapical lesion was present on the CBCT images but absent on the PRs was histologically determined to have periapical inflammation. These findings confirm that CBCT scans are more sensitive in detecting apical periodontitis than PRs (Fig. 2). Overall, the specificity of PRs and CBCT is 1 (100%), as corroborated by Patel et al.² However, a human *in-vivo* study to validate these findings by histologically assessing the periapical tissues would be unethical.⁴

Using greyscale CBCT readings, Simon et al.⁶⁹ were able to differentiate solid from cystic or cavity-type lesions in 17 teeth. However, not all the lesions were intact and no attempt was made to perform serial sectioning of the biopsy material. To date, there remains no consensus on the possibility of differentiating cysts from granulomas using CBCT imaging^{70,71}; therefore, the use of CBCT is not useful in deciding whether or not to perform a periapical surgery.

Images obtained using CBCT provide the clinician with great detail and much information, allowing the presence of previously undiagnosed pathoses^{66,72} or absence of odontogenic aetiology of pain^{73,74} to be verified. However, no single

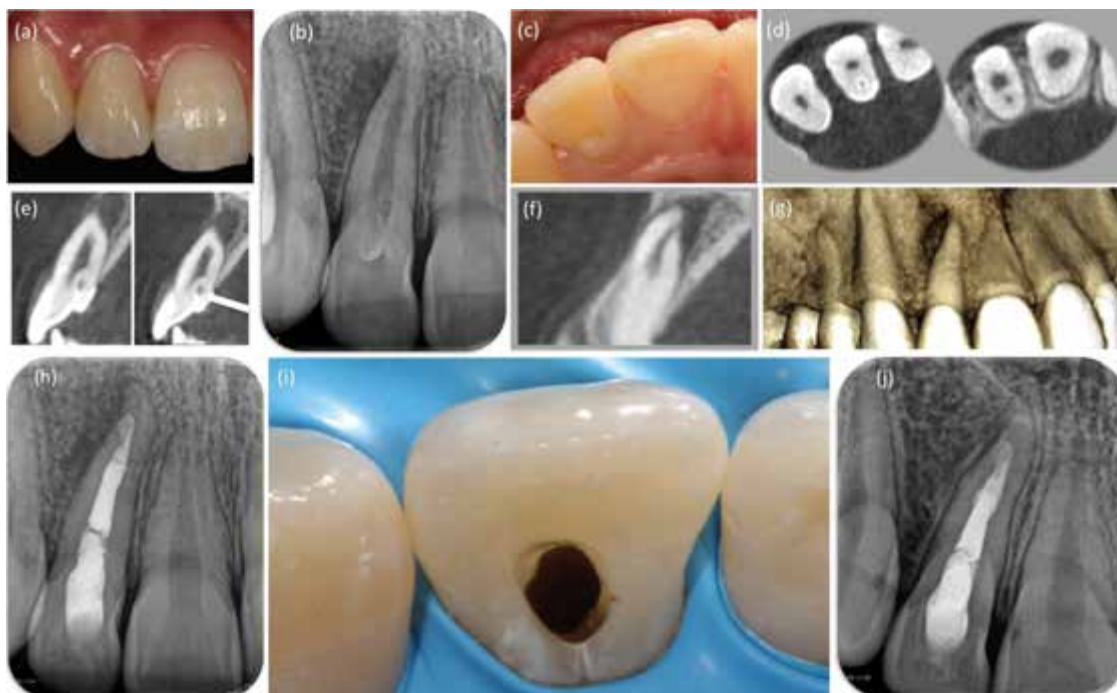


Figure 1 (a) A healthy 16-year-old woman reported episodes of pain and swelling associated with maxillary lateral incisor (tooth 12) over the previous 3 weeks. The crown of the affected tooth was intact but somewhat wider than the bilateral tooth. (b) The tooth did not respond to thermal and electrical stimuli; periodontal probing revealed a normal periodontium. Periapical radiograph showed a mature tooth, and a lateral radiolucency could be seen. (c) A small pit evident in the palatal surface was suspected of being a dens invaginatus. (d, e) Reconstructed cone beam computed tomography (CBCT) (ProMax 3Ds; Planmeca Oy, Helsinki, Finland) images confirmed the diagnosis of a dens invaginatus. The axial and sagittal views showing the enamel-line invagination (white arrow) and the relationship between the main root canal. (f) Note the lateral exit of the root canal. (g) Three-dimensional CBCT reconstruction; buccal view. (h) Post-operative radiograph. (i) Final access opening. (j) A recall periapical radiograph taken 12 months after the initial appointment. Note the complete periapical healing.

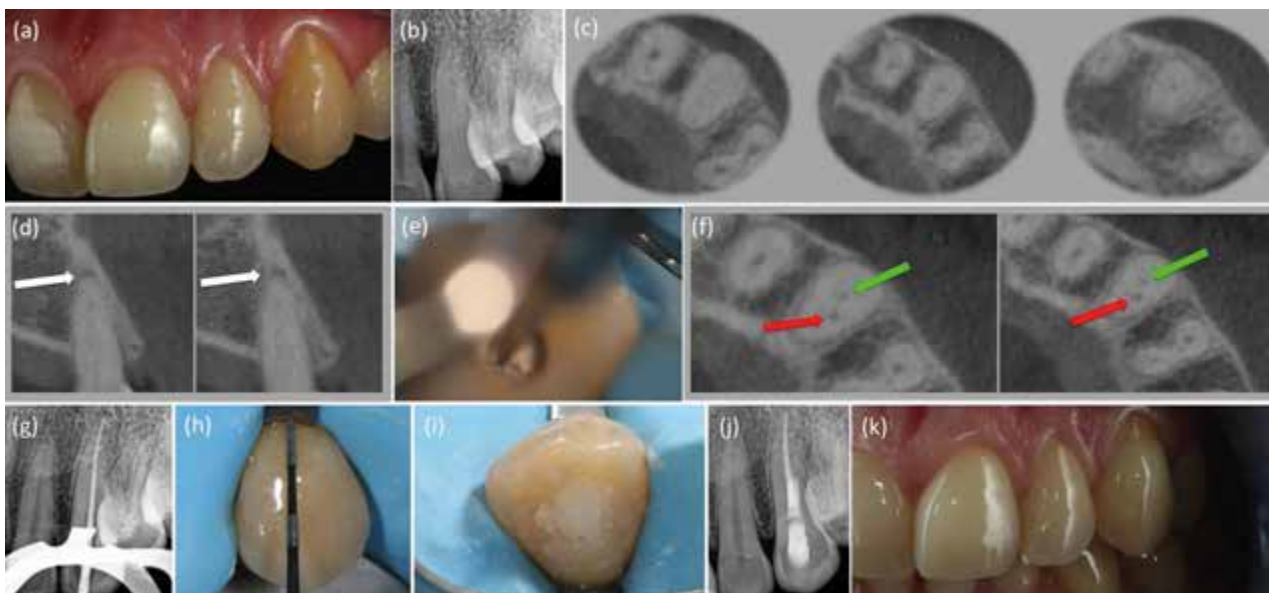


Figure 2 (a) Pre-treatment photograph of left upper canine (tooth 23) showing a yellow-brown discoloration. (b) The tooth was sensitive to percussion, but neither sinus tract nor periodontal pocket was detected. Periapical radiograph revealed a healthy periapex and an obliterated pulp space. (c) The axial cone beam computed tomography (CBCT) (CS 9000 3D; Carestream Health, Rochester, NY, USA) images showed a visible pulp space in the middle and apical portion of the root. (d) Sagittal reconstructed CBCT images revealed a periapical lesion (white arrows). (e) Despite microscopic visualization and the use of an ultrasonic tip, the root canal was not located. (f) Intraoperative CBCT axial images helped to identify location of the root canal. The red arrow denotes the root canal deviation and the green arrow denotes the correct position of the root canal. (g) Guttapercha cone before root canal filling. (h) After root canal treatment, an intracoronary bleaching was the treatment of choice. The root filling was reduced 1–2 mm below the cemento-enamel junction. (i) Sodium perborate mixed with distilled water was placed into the pulp chamber. (j) Periapical radiograph taken immediately after treatment. (k) Clinical results after 2 applications of the walking bleach technique, resulting in a slightly overbleached tooth.

test or imaging technology will provide a definitive diagnosis. A risk/benefit analysis should always be performed prior to the use of any imaging technique.⁷⁵

Assessment of the outcome of root canal treatment

Perhaps the most important area in which CBCT can be applied in endodontics is in determining the outcome of treatment. One advantage of CBCT is that regions or teeth to be compared over time do not need to be examined with the same projection geometry, as is the case in conventional radiography. Similarity between images in both geometry and contrast can be achieved *post hoc*.^{2,9}

Earlier identification of periapical radiolucent changes using CBCT may result in earlier diagnosis and more effective management of periapical disease. Mota de Almeida et al.⁷⁴ determined whether the outcome of CBCT examinations, performed in accordance with European Commission guidelines, had an impact on endodontic diagnoses. Their results showed that CBCT had a substantial impact on diagnostic efficacy; diagnoses were changed for 28 teeth (35%).

Conventional and digital PRs have been widely used for follow-up after root canal treatment. However, in teeth with apical periodontitis, microscopic findings and radiographic examinations are often divergent.⁷⁶ Chronic periapical inflammation often persists for years after root canal filling,

even in the absence of clinical symptoms and radiographic alterations.^{77,78} The most recent literature demonstrates that the detection of periapical lesions following root canal treatment using CBCT is more accurate than that using radiographic evaluation.^{68,79,80,67} de Paula-Silva et al.⁵⁸ evaluated periapical repair after root canal treatment in dogs' teeth using CBCT and PRs and compared these findings with the gold standard: microscopic evaluation. Six months after treatment, a favourable outcome was detected in 79% of teeth assessed with PRs, in comparison to 35% when CBCT was used.

These findings are similar to those of other studies.^{67,81} Patel et al.⁶⁷ compared the radiographic change in the periapical status of individual roots using digital PRs versus CBCT 1 year after primary root canal treatment. The healed rate (no periapical radiolucency) for all roots was 92.7% using PRs and 73.9% using CBCT. This rate increased to 97.2% and 89.4%, respectively, when the healing group (periapical radiolucency of reduced size) was included. In teeth with existing pre-operative periapical radiolucencies, reconstructed CBCT images also showed more failure (13.9%) when compared with PRs (10.4%). In a retrospective longitudinal cohort study, Fernández et al.⁸¹ evaluated the outcome of endodontic treatments as assessed by conventional and digital PRs and CBCT during a 5-year follow-up period. They suggested that CBCT was more sensitive than PRs for the visualization of periapical lesions in a long-term evaluation. In addition, it was found that the root canal curvature, failure to disinfect gutta-percha, the presence of missed canals and inadequate

definitive coronal restoration at follow-up were prognostic factors that negatively influenced the outcome of treatment. However, it was not possible to confirm whether these lesions were already present before commencement of the treatment, because no pre-treatment CBCT scans had been taken.

Liang et al.⁸² compared the quality of root canal treatment using PRs and CBCT in teeth with vital pulps. They found that the treatment outcome, length and density of root fillings and outcome predictors as determined using CBCT differed from the corresponding values determined using PRs. CBCT detected periapical lesions in 25.9% of the teeth, compared with 12.6% using PRs. Root fillings with voids and unsatisfactory coronal restorations negatively influenced the outcome.

Underestimation of the size of periapical lesion by PRs relative to CBCT highlights the importance of human clinical trials to determine the mean time needed for periapical healing when assessed using CBCT, especially because recent reports have suggested that persistent or periapical disease can have an impact on both oral and general health.^{83,84} It would be justifiable to use small FOV CBCT scans in clinical research trials. However, CBCT should not be used for the routine assessment of periapical disease prior to endodontic treatment.

Pre-surgical planning

Post-treatment apical periodontitis is preferably treated by nonsurgical retreatment, unless patient preference or a risk/benefit analysis indicates the use of periapical surgery.⁸⁵

Modern surgical endodontic treatment offers easier identification of root apices, smaller osteotomies and shallower resection angles, which preserve cortical bone and root length.⁸⁵ The modern technique has a much higher success rate than the traditional technique.⁸⁶ Tsesis et al.⁸⁷ reported that modern surgical endodontic treatment yields a successful outcome rate of 89%. CBCT is particularly recommended for diagnosis and treatment planning before endodontic surgery.¹

The benefits of the use of CBCT during endodontic surgery including elimination of the superimposition of anatomic structures, such as the zygomatic buttress, alveolar bone, maxillary sinus and other roots, and early detection of the presence and dimensions of apical lesions and changes in apical bone density.^{4,14} The axial, coronal and sagittal planes obtained with CBCT scans also provide clinicians with a clear view of the anatomical relationship between root apices and neighbouring structures, such as the mandibular canal,⁶⁰ mental foramen and maxillary sinus.^{65,88}

Low et al.⁶⁵ compared the radiographic findings of PRs with those of CBCT in root-treated maxillary posterior teeth under assessment for periapical surgery. CBCT identified significantly more periapical lesions (34%) than PRs, a clinically important difference. Detecting lesions with PRs alone was most difficult in second molars or in roots in close proximity to the floor of the maxillary sinus. Bornstein et al.⁸⁸ confirmed that limited CBCT imaging is a valuable diagnostic method to evaluate anatomically demanding areas, such as the posterior maxilla and maxillary sinus,

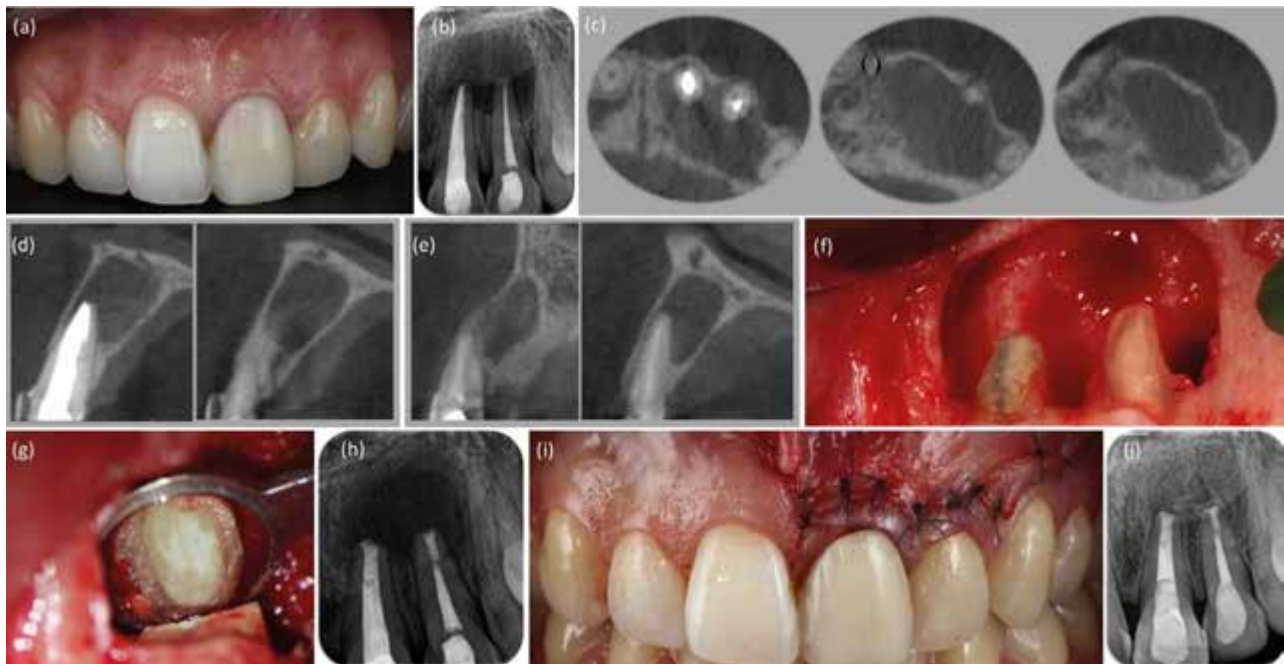


Figure 3 (a) A clinical image of the left maxillary central and lateral incisor subjected to endodontic surgery. (b) A periapical radiograph showing an apical lesion in teeth 21 and 22. (c, d, e) A cone beam computed tomography (CBCT) scan (CS 9000 3D; Carestream Health, Rochester, NY, USA) was performed before endodontic surgery. (c) Sagittal and axial images confirmed a circumscribed apical lesion. Note that the apical lesion affected neither the buccal nor palatal cortical plates. (f) A submarginal (Ochsenbein-Luebke) flap was raised to gain access and treat the apical lesion. Final size of the osteotomy. (g) Mineral trioxide aggregate (White ProRoot MTA, Dentsply Maillefer) root-end – filled apex. (h) An immediate post-operative radiograph. No bone regeneration techniques were required. (i) The flap was repositioned and sutured tightly with 5 × 0 monofilament sutures. (j) Two-year follow-up radiograph showing almost complete healing.

before periapical surgery. Malliet et al.⁸⁹ concluded that CBCT images may allow clinicians to avoid periapical surgery for maxillary molar teeth where the floor of the sinus has been perforated by a periapical lesion that is larger than estimated, which may have not been readily detected on PRs.

The study by Bornstein et al.,⁶⁰ which was performed on mandibular molars, showed that, of 58 periapical lesions detected with sagittal CBCT sections, 15 (25.9%) were not detected with PRs. These authors also found that the distance between the apices of the first mandibular molars and the upper border of the mandibular canal was not measurable in 44 of 68 PRs (64.7%). The true size, location and extent of periapical lesions can be appreciated with CBCT and the actual root with which the lesion is associated can be confirmed.⁶⁷

The use of CBCT imaging may be indicated for select cases when planning periapical surgery, but the decision should be based on several factors, such as proximity of the root apices to neighbouring anatomical structures,^{60,88} suspicion of a missing root canal,⁹⁰ or assessment of the bony defect (e.g. apicomarginal lesions, large periapical lesions communicating with the alveolar crest and through-and-through lesions)⁹¹ (Fig. 3).

Assessment of vertical root fracture, resorption or perforation

Complete or incomplete vertical root fracture (VRF) develops longitudinally along the root.⁹² If the root fragment has not

been displaced (incomplete root fracture), root fractures may be difficult to diagnose using PRs.⁹³ As reported by Tsesis et al.,⁹⁴ it is difficult to reach a definitive diagnosis based on the signs and symptoms alone, because they are not specific to fractures and may be very similar to those of endodontic or periodontal disease. Meister et al.⁹⁵ suggested that VRF could only be detected directly using PRs if there is separation of the root fragment and if the fracture traverses in the direction of the X-ray beam. If the fracture is not in the plane of the beam, the clinician is forced to make interpretations based on periradicular bone loss.

Controversy surrounds the accuracy of CBCT imaging for detecting VRF. Some studies have found that CBCT imaging is more accurate than PRs. Özer⁹⁶ created fractures of known widths ranging from 0 to 0.4 mm and reported that CBCT imaging was more successful than PRs in correctly diagnosing the fractures (82% and 42%, respectively). Bernardes et al.⁹⁷ reported that, in endodontically treated teeth, CBCT imaging detected VRF in 90% of cases, whereas PRs detected VRF in only 10%. However, this study did not confirm the presence/absence of root fracture by comparison with a reference standard.

Some studies^{98,99} have concluded that CBCT imaging is an unreliable method of detecting VRF, whereas others have found no differences between CBCT and PRs.^{100,101} Recently, Chavda et al.¹⁰² concluded that both CBCT and PRs had a high and comparable degree of specificity (0.92 for PRs and 0.83 for CBCT imaging) but that both exhibited low sensitivity, at 0.27 and 0.15, respectively. These results indicate that the

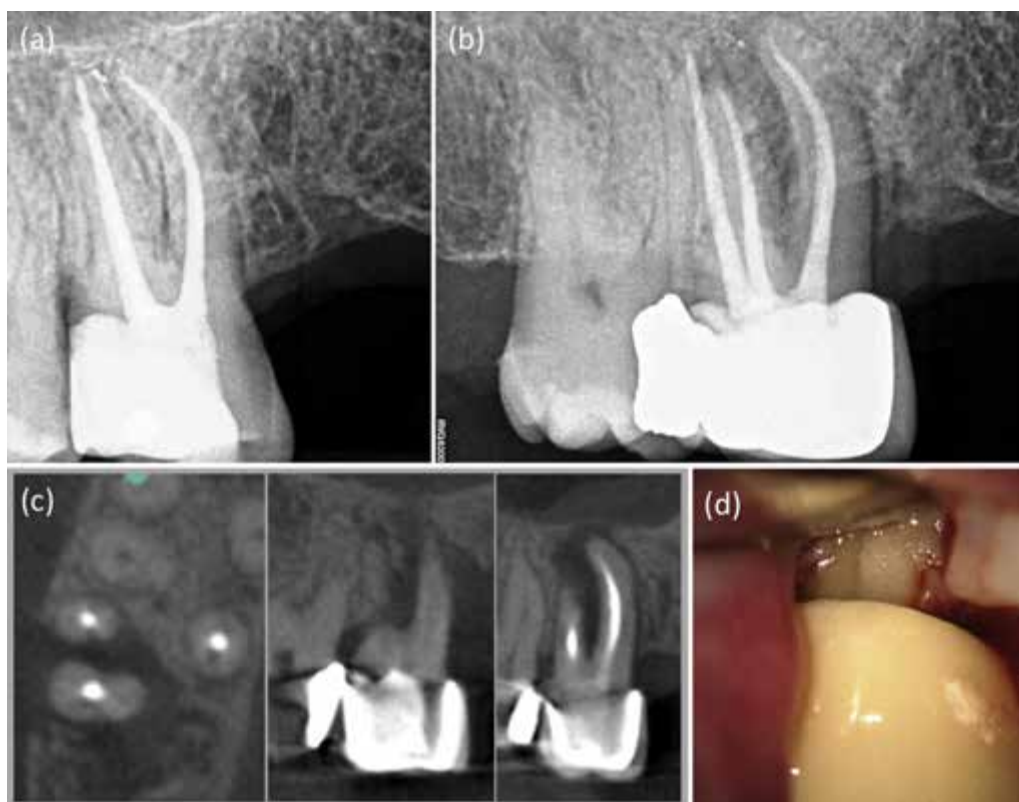


Figure 4 Example images of a right maxillary first molar (tooth 16): (a, b) digital periapical radiographs, and (c) reconstructed axial cone beam computed tomography (CBCT) (CS 9000 3D; Carestream Health, Rochester, NY, USA) slices. The fracture was not visible on either imaging modality. (d) The suspected vertical root fracture was only confirmed during the surgical flap procedure.

likelihood of detecting a VRF is low for both modalities (Fig. 4). Therefore, CBCT imaging could be a useful adjunct to a thorough clinical examination, but this system by no means guarantees a correct diagnosis of a VRF.

Root resorption is defined as the loss of dental hard tissues as a result of osteoclastic activities.¹⁰³ It can be a physiological or a pathological phenomenon. Unlike bone, which undergoes continuous physiological remodelling throughout life, root resorption of permanent teeth does not occur naturally and is invariably inflammatory in nature. Therefore, root resorption in the permanent dentition is a pathological event; if untreated, it may result in the premature loss of the affected teeth.¹⁰⁴ The diagnosis of root resorption is based primarily on radiographic examination, with supplementary information gained from the history and clinical findings.¹⁰⁵

Although PRs are currently the reference standard for the detection of root resorption, CBCT scans result in enhanced diagnosis of the presence and type of root resorption (Fig. 5).^{103,104} *In-vitro* studies^{106–109} have demonstrated the superior diagnostic accuracy of CBCT over PRs in the detection of simulated resorption cavities. Both Durack et al.¹⁰⁶ and Bernardes et al.¹⁰⁹ highlighted the ability of CBCT to detect incipient root resorption before it became identifiable using conventional radiographic systems. However, it is unclear whether voxel size affects the potential of CBCT to detect these cavities.^{108,110}

Two clinical studies^{111,112} also reported that CBCT is superior to PRs in identifying and determining the extent of root

resorption. Patel et al.¹¹¹ found that CBCT was 100% accurate in its ability to diagnose the presence of root resorption, whereas the sensitivity of PRs was significantly lower. Therefore, this imaging modality is a suitable tool for the assessment of the true condition of teeth diagnosed with root resorption that can improve their diagnosis and aid management.

Root canal perforation is a procedural error that results in communication between the root canal walls and the periodontal space; it is capable of affecting the prognosis of endodontic retreatment (Fig. 6).¹¹³ In phases 3 and 4 of the Toronto study,¹¹⁴ the observed healed rate in teeth with a perforation was 31%, lower than in teeth without perforation.

Timely detection of perforations will aid in selecting the proper therapy, thus minimizing bone loss, and in predicting the outcome and analysing failures.¹¹⁵ Radiographic detection is challenging on the labial and lingual root surface, because the image of the perforation is superimposed on that of the root. Kamburoğlu et al.¹¹⁶ found that the ProMax[®] 3D Max CBCT scanner (Planmeca Oy, Helsinki, Finland), at all voxel sizes, is useful in determining the presence and dimensions of furcal perforations when perforation is suspected. When adequate information cannot be obtained through clinical examination and using traditional 2D techniques, CBCT imaging may help to identify fractured files, cast post deviations and perforations.^{107,117} The final diagnosis and choice of clinical therapy for root perforations should always be made in conjunction with the clinical findings.

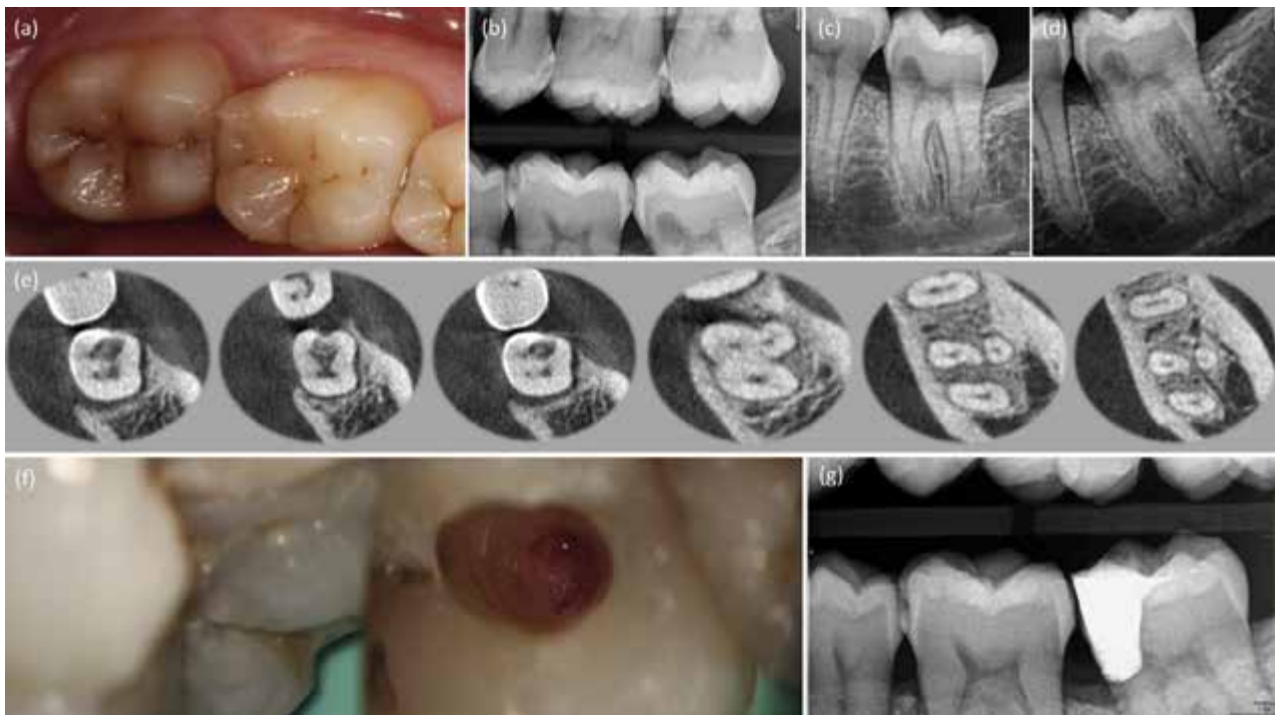


Figure 5 (a, b) A 45-year-old woman was referred by her general dental practitioner for endodontic management of a possible external cervical resorption lesion on the tooth 37. On presentation, the patient was asymptomatic. (c, d) Periapical radiographs of tooth 37 using a paralleling technique revealed a well-circumscribed and symmetric radiolucency in the cervical aspect of the tooth. (e) Axial cone beam computed tomography (CBCT) (ProMax 3Ds; Planmeca Oy, Helsinki, Finland) slices through tooth 37 showing a radiolucency with defined margins. The resorptive lesion had not perforated into the root canal. Furthermore, axial slices allowed the relationship between a supernumerary root (distolingual) and the other roots to be assessed. (f) The external cervical lesion was treated by an internal approach. (g) A post-operative periapical radiograph.

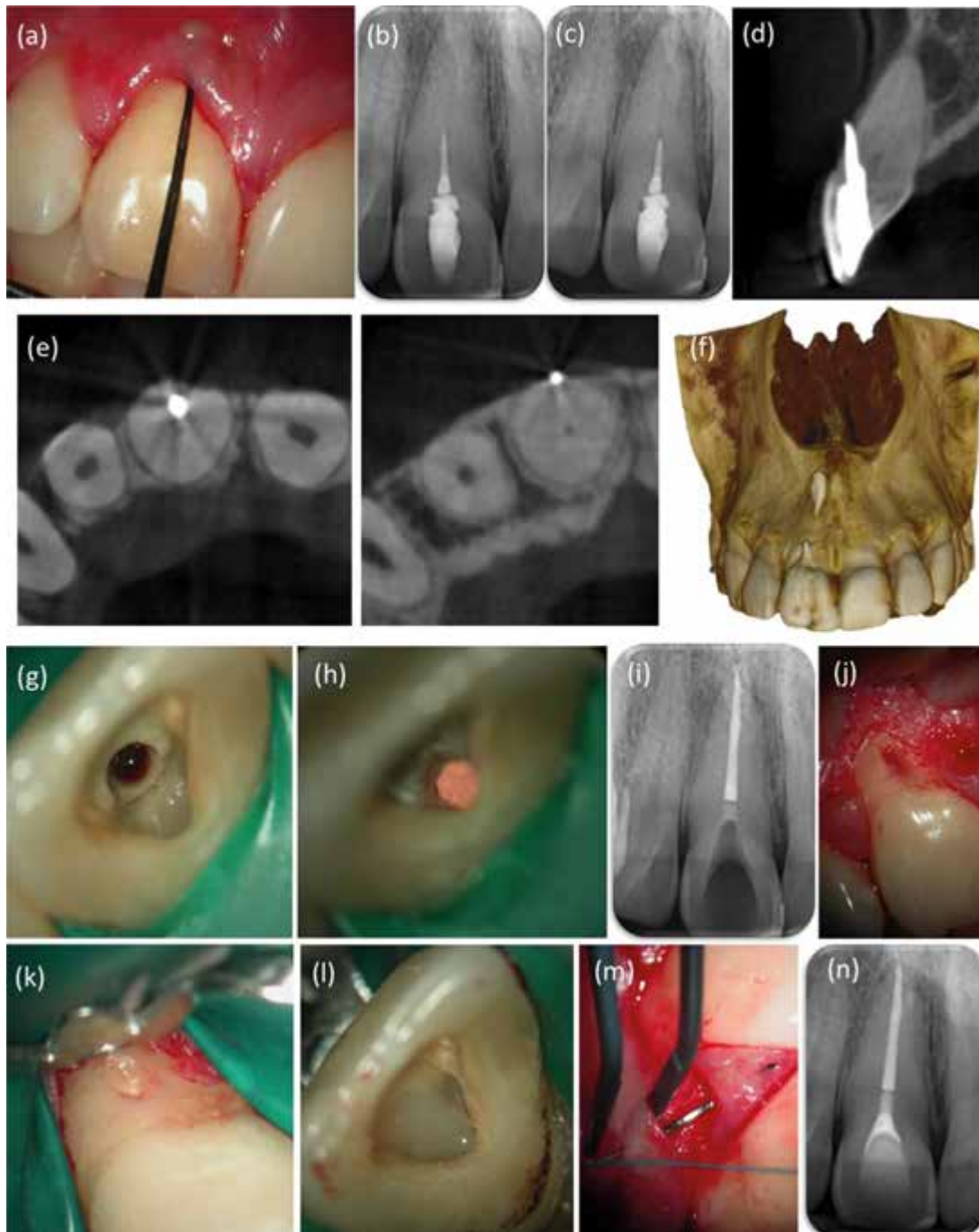


Figure 6 (a) A 30-year-old male patient presented with a chief complaint of severe pain and swelling in the maxillary incisor region. Clinical examination revealed 5-mm-deep periodontal pocket associated with tooth 11. (b, c) Pre-operative periapical radiographs of tooth 11 with different horizontal angulations. Root perforation was suspected but could not be confirmed because of superimposition of the surrounding structures. (d, e) Cone beam computed tomography (CBCT) (CS 9000 3D; Carestream Health, Rochester, NY, USA) demonstrated a root perforation on the buccal root surface 1 mm above the alveolar crest. Sagittal reconstructed CBCT images revealed that the periapical radiolucency was larger than that seen radiographically. (f) Three-dimensional CBCT reconstruction. (g, h) An adequate access cavity to locate both the root perforation and the root canal. (i) Radiographic control after filling the root canal. (j) A papilla-base flap was raised to gain access and treat the root perforation. (k–m) Treatment attempt of the perforation included sealing with a resin-composite. (n) Two-year follow-up radiograph.

Assessment of dental trauma

Traumatic dental injuries present a challenge to clinicians worldwide. Correct diagnosis, treatment planning and

follow-up of the injury are essential and must be achieved through detailed history taking and clinical and radiographic assessment.¹¹⁸ The International Association of Dental Traumatology guidelines recommend that several

projections and angles should be imaged routinely (90° horizontal angle, occlusal view and a lateral view from the mesial or distal aspect of the affected tooth)¹¹⁹.

Horizontal root fractures usually affect maxillary central incisors and are typically traumatic in origin, associated with accidents, sports injuries or fights.¹²⁰ The treatment outcome for fractured teeth may be influenced by several factors, such as the degree of dislocation, stage of root formation, location of the fracture, interval between trauma and treatment, and type of dental trauma (displacement of the coronal fragment compared with no displacement of the coronal fragment).¹²¹ One problem is that the fracture line will only be detected if the X-ray beam passes directly through it. The absence of radiographic signs when the X-ray beam is not parallel to the plane of the root fracture, tooth displacement and/or alveolar bone fracture is a limitation of intra-oral PRs.⁴

Use of CBCT allows accurate diagnosis of the presence or absence, as well as the exact location, extent and direction, of a horizontal fracture line.^{122,123} The latest trauma guidelines suggest that, in addition to conventional radiography, CBCT scans may be considered for the diagnosis of horizontal root fracture.¹¹⁸ Bornstein et al.¹²⁴ highlighted the relevance of CBCT to prognosis and treatment planning. As reported by May et al.,¹²⁵ there is a significant risk of misdiagnosing the location of a root fracture in anterior teeth when using intra-oral radiography, because of the possibility of an oblique course of the fracture line in the sagittal plane.

Conclusions

Diagnostic information directly influences clinical decisions. Accurate data facilitate better treatment-planning decisions and more predictable outcomes. CBCT is an emerging technology with the potential to revolutionize the diagnosis and management of endodontic problems. An increasing number of specific applications of CBCT in endodontics are being identified as use of the technology becomes more widespread.

The benefits of a CBCT investigation must outweigh any potential risks; therefore, cases of endodontic disease should be judged on an individual basis. Until further evidence is available, CBCT should only be considered in situations where conventional imaging systems do not yield sufficient information to allow the appropriate management of the endodontic problem. The ALARA principle must be adhered to in all cases.

CBCT imaging has the potential to become the first choice for endodontic treatment planning and outcome assessment, especially when new scanners with lower radiation doses and better resolution become available. However, the currently available literature in this field is mainly limited to technical details and diagnostic accuracy (levels 1 and 2 in a hierarchical model) and, even in these areas, the information available is limited and incomplete.⁷⁵ Further clinical trials are needed to provide insight on the increased efficacy possible with endodontic applications of CBCT, especially regarding patient outcome.

Furthermore, practitioners of CBCT must be adequately trained in CBCT radiology as well as in the interpretation of the images obtained, because the modality is completely different from conventional radiography. In summary, a

cautious and rational approach is advised when considering the use of CBCT imaging in endodontics.

Conflict of interest

The authors deny any conflicts of interest.

The authors deny any financial affiliations related to this study or its sponsors.

References

1. Cotton TP, Geisler TM, Holden DT, Schwartz SA, Schindler WG. Endodontic applications of cone-beam volumetric tomography. *J Endod* 2007;**33**:1121–32.
2. Patel S. New dimensions in endodontic imaging: part 2. Cone beam computed tomography. *Int Endod J* 2009;**42**:463–75.
3. Dailey B, Mines P, Anderson A, Sweet M. The use of cone beam computer tomography in endodontics: results of a questionnaire: 2010. AAE annual session abstract presentation PR10. *J Endod* 2010;**36**:567.
4. Patel S, Durack C, Abella F, Shemesh H, Roig M, Lemberg K. Cone beam computed tomography in Endodontics – a review. *Int Endod J* 2015;**48**:3–15.
5. Cohenca N, Shemesh H. Clinical applications of cone beam computed tomography in endodontics: a comprehensive review. *Quintessence Int* 2015;**46**:465–80.
6. European Society of Endodontology, Patel S, Durack C, Abella F, Roig M, Shemesh H, Lambrechts P, et al. European Society of Endodontology position statement: the use of CBCT in endodontics. *Int Endod J* 2014;**47**:502–4.
7. Robb RA, Sinak LJ, Hoffman EA, Kinsey JH, Harris LD, Ritman EL. Dynamic volumetric imaging of moving organs. *J Med Syst* 1982;**6**:539–54.
8. Mozzo P, Procacci C, Tacconi A, Martini PT, Andreis IA. A new volumetric CT machine for dental imaging based on the cone-beam technique: preliminary results. *Eur Radiol* 1998;**8**:1558–64.
9. Patel S, Dawood A, Whaites E, Pitt Ford T. New dimensions in endodontic imaging: part 1. Conventional and alternative radiographic systems. *Int Endod J* 2009;**42**:447–62.
10. Kau CH, Bozic M, English J, Lee R, Bussa H, Ellis RK. Cone-beam computed tomography of the maxillofacial region – an update. *Int J Med Robot* 2009;**4**:366–80.
11. Ngan DCS, Kharbanda OP, Geenty JP, Darendeliler MA. Comparison of radiation levels from computed tomography and conventional dental radiographs. *Aust Orthod J* 2003;**19**:62–75.
12. Mah JK, Danforth RA, Bumann A, Hatcher D. Radiation absorbed in maxillofacial imaging with a new dental computed tomography device. *Oral Surg Oral Med Oral Pathol Oral Radiol Endod* 2003;**96**:508–13.
13. Ludlow JB, Davies-Ludlow LE, Brooks SL. Dosimetry of two extraoral direct digital imaging devices: NewTom cone beam CT and Orthophos Plus DS panoramic unit. *Dentomaxillofac Radiol* 2003;**32**:229–34.
14. Lofthag-Hansen S, Huuononen S, Gröndahl K, Gröndahl HG. Limited cone-beam CT and intraoral radiography for the diagnosis of periapical pathology. *Oral Surg Oral Med Oral Pathol Oral Radiol Endod* 2007;**103**:114–9.
15. Suomalainen A, Kiljunen T, Käser Y, Peltola J, Kortesianiemi M. Dosimetry and image quality of four dental cone beam computed tomography scanners compared with multislice computed tomography scanners. *Dentomaxillofac Radiol* 2009;**38**:367–78.
16. Pauwels R, Beinsberger J, Collaert B, Theodorakou C, Rogers J, Walker A, et al. Effective dose range for dental cone beam computed tomography scanners. *Eur J Radiol* 2012;**81**:267–71.

17. Qu X-M, Li G, Ludlow JB, Zhang ZY, Ma XC. Effective radiation dose of ProMax 3D cone-beam computerized tomography scanner with different dental protocols. *Oral Surg Oral Med Oral Pathol Oral Radiol Endod* 2010;**6**:770–6.
18. Hedesiu M, Baciut G, Nackaerts O, Jacobs R, SERDENTEXT Consortium. Comparison of cone beam CT device and field of view for the detection of simulated periapical bone lesions. *Dentomaxillofac Radiol* 2012;**7**:548–52.
19. Patel S, Dawood A, Ford TP, Whaites E. The potential applications of cone beam computed tomography in the management of endodontic problems. *Int Endod J* 2007;**40**:818–30.
20. ICRP Publication 103. The 2007 recommendations of the international commission on radiological protection. *Ann ICRP* 2007;**37**:1–34.
21. Theodorakou C, Walker A, Horner K, Pauwels R, Bogaerts R, Jacobs R, et al. Estimation of paediatric organ and effective doses from dental cone beam CT using anthropomorphic phantoms. *Br J Radiol* 2012;**85**:153–60.
22. Yamamoto K, Ueno K, Seo K, Shinohara D. Development of dento-maxillofacial cone beam X-ray computed tomography system. *Orthod Craniofac Res* 2003;**6**:160–2.
23. Farman AG, Farman TT. A comparison of 18 different X-ray detectors currently used in dentistry. *Oral Surg Oral Med Oral Pathol Oral Radiol Endod* 2005;**99**:485–9.
24. Mora MA, Mol A, Tyndall DA, Rivera E. In vitro assessment of local tomography for the detection of longitudinal tooth fractures. *Oral Surg Oral Med Oral Pathol Oral Radiol Endod* 2007;**103**:825–9.
25. Sögür E, Baksi BG, Grondahl HG. Imaging of root canal fillings: a comparison of subjective image quality between limited cone-beam CT, storage phosphor and film radiography. *Int Endod J* 2007;**40**:179–85.
26. Estrela C, Bueno MR, Leles CR, Azevedo B, Azevedo JR. Accuracy of cone beam computed tomography and panoramic and periapical radiography for detection of apical periodontitis. *J Endod* 2008;**34**:273–9.
27. Logthag-Hansen S, Thilander-Klang A, Gröndahl K. Evaluation of subjective image quality in relation to diagnostic task for cone beam computed tomography with different fields of view. *Eur J Radiol* 2011;**80**:483–8.
28. Ritter L, Mischkowski RA, Neugebauer J, Dreiseidler T, Scheer M, Keeve E, et al. The influence of body mass index, age, implants, and dental restorations on image quality of cone beam computed tomography. *Oral Surg Oral Med Oral Pathol Oral Radiol Endod* 2009;**3**:e108–16.
29. Vertucci FJ. Root canal anatomy of the mandibular anterior teeth. *J Am Dent Assoc* 1974;**89**:369–71.
30. Kulid JC, Peters DD. Incidence and configuration of canal systems in the mesiobuccal root of maxillary first and second molars. *J Endod* 1990;**16**:311–7.
31. Matherne RP, Angelopoulos C, Kulid JC, Tira D. Use of cone-beam computed tomography to identify root canal systems in vitro. *J Endod* 2008;**34**:87–9.
32. Carabelli G. Systematisches Handbuch der Zahnheilkunde, 2nd edn. Vienna, Austria: Braumüller and Seidel; 1884: 114.
33. Bolk L. Bermerkungen über Wurzelvariationen am menschlichen unteren Molaren. *Ztg Morphol Anthropol* 1915;**17**:605–10.
34. Calberson FL, De Moor RJ, Deroose CA. The radix entomolaris and paramolaris: clinical approach in endodontics. *J Endod* 2007;**33**: 58–63.
35. Abella F, Patel S, Durán-Sindreu F, Mercadé M, Roig M. Mandibular disto-lingual roots: review and clinical management. *Int Endod J* 2012;**45**:963–78.
36. Tu MG, Tsai CC, Jou MJ, Chen WL, Chang YF, Chen SY, et al. Prevalence of three-rooted mandibular first molars among Taiwanese individuals. *J Endod* 2007;**33**:1163–6.
37. Tu MG, Huang HL, Hsue SS, Hsu JT, Chen SY, Jou MJ, et al. Detection of permanent three-rooted mandibular first molars by cone-beam computed tomography imaging in Taiwanese individuals. *J Endod* 2009;**35**:503–7.
38. Gulabivala K, Aung TH, Alavi A, Ng YL. Root and canal morphology of Burmese mandibular molars. *Int Endod J* 2001;**34**:359–70.
39. Kim Y, Perinpanayagam H, Lee JK, Yoo YJ, Oh S, Gu Y, et al. Comparison of mandibular first molar mesial root canal morphology using micro-computed tomography and clearing technique. *Acta Odontol Scand* 2015;**73**:427–32.
40. Karapinar-Kazandag M, Basrani BR, Friedman S. The operating microscope enhances detection and negotiation of accessory mesial canals in mandibular molars. *J Endod* 2010;**36**:1289–94.
41. Pomeranz HH, Edelman DL, Goldberg MG. Treatment considerations of the middle mesial canal of mandibular first and second molars. *J Endod* 1981;**7**:565–8.
42. Azim AA, Deutsch AS, Solomon CS. Prevalence of middle mesial canals in mandibular molars after guided troughing under high magnification: an in vivo investigation. *J Endod* 2015;**41**:164–8.
43. Teixeira FB, Sano CL, Gomes BP, Zaia AA, Ferraz CC, Souza-Filho FJ. A preliminary in vitro study of the incidence and position of the root canal isthmus in maxillary and mandibular first molars. *Int Endod J* 2003;**36**:276–80.
44. von Arx T. Frequency and type of canal isthmuses in first molars detected by endoscopic inspection during periradicular surgery. *Int Endod J* 2005;**38**:160–8.
45. Baugh D, Wallace J. Middle mesial canal of the mandibular first molar: a case report and literature review. *J Endod* 2004;**30**: 185–6.
46. de Toubes KM, Cortes MI, Valadares MA, Fonseca LC, Nunes E, Silveira FF. Comparative analysis of accessory mesial canal identification in mandibular first molars by using four different diagnostic methods. *J Endod* 2012;**38**:436–41.
47. Blattner TC, George N, Lee CC, Kumar V, Yelton CD. Efficacy of cone-beam computed tomography as a modality to accurately identify the presence of second mesiobuccal canals in maxillary first and second molars: a pilot study. *J Endod* 2010;**36**:867–70.
48. Neelakantan P, Subbarao C, Ahuja R, Subbarao CV, Gutmann JL. Cone-beam computed tomography study of root and canal morphology of maxillary first and second molars in an Indian population. *J Endod* 2010;**36**:1622–7.
49. Abella F, Patel S, Duran-Sindreu F, Mercadé M, Bueno R, Roig M. Evaluating the periapical status of teeth with irreversible pulpitis by using cone-beam computed tomography scanning and periapical radiographs. *J Endod* 2012;**38**:1588–91.
50. Abella F, Patel S, Duran-Sindreu F, Mercadé M, Bueno R, Roig M. An evaluation of the periapical status of teeth with necrotic pulps using periapical radiography and cone-beam computed tomography. *Int Endod J* 2014;**47**:387–96.
51. Altunsoy M, Ok E, Nur BG, Aglarci AS, Gungor E, Colak M. A cone-beam computed tomography study of the root canal morphology of anterior teeth in a Turkish population. *Eur J Dent* 2014;**8**:302–6.
52. Han T, Ma Y, Yang L, Chen X, Zhang X, Wang Y. A study of the root canal morphology of mandibular anterior teeth using cone-beam computed tomography in a Chinese subpopulation. *J Endod* 2014;**40**:1309–14.
53. Yu X, Guo B, Li KZ, Zhang R, Tian YY, Wang H. Cone-beam computed tomography study of root and canal morphology of mandibular premolars in a western Chinese population. *BMC Med Imaging* 2012;**20**:12–8.
54. Abella F, Teixidó LM, Patel S, Sosa F, Duran-Sindreu F, Roig M. Cone-beam computed tomography of maxillary first and second premolars in a Spanish population. *J Endod* 2015;**41**:1241–7.
55. Venskutonis T, Plotino G, Juodzbalys G, Mickevičienė LM. The importance of cone beam computed tomography in the management of endodontic problems: a review of the literature. *J Endod* 2014;**40**:1895–901.
56. Andreasen JO, Rud J. Correlation between histology and radiography in the assessment of healing after endodontic surgery. *Int J Oral Surg* 1972;**1**:161–73.

57. Pitt Ford TR. The radiographic detection of periapical lesions in dogs. *Oral Surg Oral Med Oral Pathol* 1984;57:662–7.
58. de Paula-Silva FW, Santamaria Jr M, Leonardo MR, Consolaro A, da Silva LA. Cone-beam computerized tomographic, radiographic, and histologic evaluation of periapical repair in dogs' post-endodontic treatment. *Oral Surg Oral Med Oral Pathol Oral Radiol Endod* 2009;108:796–805.
59. Özen T, Kamburoğlu K, Cebeci AR, Yüksel SP, Paksoy CS. Interpretation of chemically created periapical lesions using 2 different dental cone-beam computerized tomography units, an intraoral digital sensor, and conventional film. *Oral Surg Oral Med Oral Radiol Endod* 2009;107:426–32.
60. Bornstein MM, Lauber R, Sendi P, von Arx T. Comparison of periapical radiography and limited cone-beam computed tomography in mandibular molars for analysis of anatomical landmarks before apical surgery. *J Endod* 2011;37:151–7.
61. Bender IB, Seltzer S. Roentgenographic and direct observation of experimental lesions in bone, I. *J Am Dent Assoc* 1961;62:152–60.
62. Bender IB, Seltzer S. Roentgenographic and direct observation of experimental lesions in bone, II. *J Am Dent Assoc* 1961;62:708–16.
63. Schwartz SF, Foster JK. Roentgenographic interpretation of experimentally produced bone lesions. *Oral Surg Oral Med Oral Pathol* 1971;32:606–12.
64. Stavropoulos A, Wenzel A. Accuracy of cone beam dental CT, intraoral digital and conventional film radiography for the detection of periapical lesions. An ex vivo study in pig jaws. *Clin Oral Investig* 2007;11:101–6.
65. Low MTL, Dula KD, B€urgin W, von Arx T. Comparison of periapical radiography and limited cone-beam tomography in posterior maxillary teeth referred for apical surgery. *J Endod* 2008;34: 557–62.
66. Pigg M, List T, Petersson K, Lindh C, Petersson A. Diagnostic yield of conventional radiographic and conebeam computed tomographic images in patients with atypical odontalgia. *Int Endod J* 2011;44:1092–101.
67. Patel S, Wilson R, Dawood A, Foschi F, Manocci F. The detection of periapical pathosis using digital periapical radiography and cone beam computed tomography – part 2: a 1-year post-treatment follow-up. *Int Endod J* 2012;45:711–23.
68. de Paula-Silva FW, Wu MK, Leonardo MR, da Silva LA, Wesselink PR. Accuracy of periapical radiography and cone-beam computed tomography scans in diagnosing apical periodontitis using histopathological findings as a gold standard. *J Endod* 2009;35: 1009–12.
69. Simon JH, Enciso R, Malfaz JM, Roges R, Bailey-Perry M, Patel A. Differential diagnosis of large periapical lesions using cone-beam computed tomography measurements and biopsy. *J Endod* 2006;32:833–7.
70. Guo J, Simon JH, Sedghizadeh P, Soliman ON, Chapman T, Enciso R. Evaluation of the reliability and accuracy of using cone-beam computed tomography for diagnosing periapical cysts from granulomas. *J Endod* 2013;39:1485–90.
71. Rosenberg PA, Frisbie J, Lee J, Lee K, Frommer H, Kottal S, et al. Evaluation of pathologists (histopathology) and radiologists (cone beam computed tomography) differentiating radicular cysts from granulomas. *J Endod* 2010;36:423–8.
72. Nakata K, Naitoh M, Izumi M, Inamoto K, Ariji E. Evaluation of correspondence of dental computed tomography imaging to anatomic observation of external root resorption. *J Endod* 2009;35:1594–7.
73. Jiang M, You M, Wang H, Xu L. Characteristic features of the adenomatoid odontogenic tumour on cone beam CT. *Dentomaxillofac Radiol* 2014;43:20140016.
74. Mota de Almeida FJ, Knutsson K, Flygare L. The impact of cone beam computed tomography on the choice of endodontic diagnosis. *Int Endod J* 2015;48:564–72.
75. Rosen E, Taschieri S, Del Fabbro M, Beitlitum I, Tsesis I. The diagnostic efficacy of cone-beam computed tomography in Endodontics: a systematic review and analysis by a hierarchical model of efficacy. *J Endod* 2015;41:1008–14.
76. Barthel CR, Zimmer S, Trope M. Relationship of radiologic and histologic signs of inflammation in human root-filled teeth. *J Endod* 2004;2:75–9.
77. Katebzadeh N, Hupp J, Trope M. Histological periapical repair after obturation of infected root canals in dogs. *J Endod* 1999;25:364–8.
78. Katebzadeh N, Sigurdsson A, Trope M. Radiographic evaluation of periapical healing after obturation of infected root canals: an in vivo study. *Int Endod J* 2000;33:60–6.
79. Cotti E, Vargiu P, Dettori C, Mallarini G. Computerized tomography in the management and follow-up of extensive periapical lesion. *Endod Dent Trauma* 1999;15:186–9.
80. de Paula-Silva FW, Hassan B, Bezerra da Silva LA, Leonardo MR, Wu MK. Outcome of root canal treatment in dogs determined by periapical radiography and cone-beam computed tomography scans. *J Endod* 2009;35:723–6.
81. Fernández R, Cadavid D, Zapata SM, Alvarez LG, Restrepo FA. Impact of three radiographic methods in the outcome of non-surgical endodontic treatment: a five-year follow-up. *J Endod* 2013;39:1097–103.
82. Liang YH, Li G, Wesselink PR, Wu MK. Endodontic outcome predictors identified with periapical radiographs and cone-beam computed tomography scans. *J Endod* 2011;37:326–31.
83. van der Waal SV, Lappin DF, Crieleard W. Does apical periodontitis have systemic consequences? The need for well-planned and carefully conducted clinical studies. *Br Dent J* 2015;8: 513–6.
84. Nair PN. On the causes of persistent apical periodontitis: a review. *Int Endod J* 2006;39:249–81.
85. Kim S, Kratchman S. Modern endodontic surgery concepts and practice: a review. *J Endod* 2006;32:601–23.
86. Tsesis I, Rosen E, Schwartz-Arad D, Fuss Z. Retrospective evaluation of surgical endodontic treatment: traditional versus modern technique. *J Endod* 2006;32:412–6.
87. Tsesis I, Rosen E, Taschieri S, Telishevsky Strauss Y, Ceresoli V, Del Fabbro M. Outcomes of surgical endodontic treatment performed by a modern technique: an updated meta-analysis of the literature. *J Endod* 2013;39:332–9.
88. Bornstein MM, Wasmer J, Sendi P, Janner SF, Buser D, von Arx T. Characteristics and dimensions of the Schneiderian membrane and apical bone in maxillary molars referred for apical surgery: a comparative radiographic analysis using limited cone beam computed tomography. *J Endod* 2012;38:51–7.
89. Malliet M, Bowles WR, McClanahan SL, John MT, Ahmad M. Cone-beam computed tomography evaluation of maxillary sinusitis. *J Endod* 2011;37:753–7.
90. Song M, Kim HC, Lee W, Kim E. Analysis of the cause of failure in nonsurgical endodontic treatment by microscopic inspection during endodontic microsurgery. *J Endod* 2011;37:1516–9.
91. Lin L, Chen MY, Ricucci D, Rosenberg PA. Guided tissue regeneration in periapical surgery. *J Endod* 2010;36:618–25.
92. Rivera EM, Walton RE. Longitudinal tooth fractures: findings that contribute to complex endodontic diagnoses. *Endod Top* 2007;16:82–111.
93. Wang P, Yan XB, Liu D-G, Zhang WL, Zhang ZY, Ma XC. Evaluation of dental root fracture using cone-beam computed tomography. *Chin J Dent Res* 2010;13:31–5.
94. Tsesis I, Rosen E, Tamse A, Taschieri S, Kfir A. Diagnosis of vertical root fracture in endodontically treated teeth based on clinical and radiographic indices: a systematic review. *J Endod* 2010;36: 1455–8.
95. Meister F, Lommel TJ, Gerstein H. Diagnosis and possible causes of vertical root fracture. *Oral Surg Oral Med Oral Pathol Oral Radiol Endod* 1980;49:243–53.

96. Özer SY. Detection of vertical root fractures of different thicknesses in endodontically enlarged teeth by cone beam computed tomography versus digital radiography. *J Endod* 2010;**36**:1245–9.
97. Bernardes RA, de Moraes IG, Húngaro Duarte MA, Azevedo BC, de Azevedo JR, Bramante CM. Use of cone-beam volumetric tomography in the diagnosis of root fractures. *Oral Surg Oral Med Oral Pathol Oral Radiol Endod* 2009;**108**:270–7.
98. Patel S, Brady E, Wilson R, Brown J, Manocci F. The detection of vertical root fractures in root filled teeth with periapical radiographs and CBCT scans. *Int Endod J* 2013;**46**:1140–52.
99. Brady E, Manocci F, Brown J, Wilson R, Patel S. A comparison of cone beam computed tomography and periapical radiography for the detection of vertical root fractures in nonendodontically treated teeth. *Int Endod J* 2014;**47**:735–46.
100. da Silveira PF, Vizzotto MB, Liedke GS, da Silveira HL, Montagner F, da Silveira HE. Detection of vertical root fractures by conventional radiographic examination and cone beam computed tomography – an in vitro analysis. *Dent Traumatol* 2013;**1**:41–6.
101. Junqueira RB, Verner FS, Campos CN, Devito KL, do Carmo AM. Detection of vertical root fractures in the presence of intracanal metallic post: a comparison between periapical radiography and cone-beam computed tomography. *J Endod* 2013;**39**:1620–4.
102. Chavda R, Manocci F, Andiappan M, Patel S. Comparing the in vivo diagnostic accuracy of digital periapical radiography with cone-beam computed tomography for the detection of vertical root fracture. *J Endod* 2014;**40**:1524–9.
103. Patel S, Pitt Ford TR. Is the resorption external or internal? *Dent Update* 2007;**34**:218–29.
104. Patel S, Ricucci D, Durack C, Tay F. Internal root resorption: a review. *J Endod* 2010;**36**:1107–21.
105. Gulabivala K, Searson LJ. Clinical diagnosis of internal resorption: an exception to the rule. *Int Endod J* 1995;**28**:255–60.
106. Durack C, Patel S, Davies J, Wilson R, Manocci F. Diagnostic accuracy of small volume cone beam computed tomography and intraoral periapical radiography for the detection of simulated external inflammatory root resorption. *Int Endod J* 2011;**44**:136–47.
107. D’Addazio PS, Campos CN, Özcan M, Teixeira HGC, Passoni RM, Carvalho ACP. A comparative study between cone-beam computed tomography and periapical radiographs in the diagnosis of simulated endodontic complications. *Int Endod J* 2011;**44**:218–24.
108. Kamburoğlu K, Kursun S. A comparison of the diagnostic accuracy of CBCT images of different voxel resolutions used to detect simulated small internal resorption cavities. *Int Endod J* 2010;**43**:798–807.
109. Bernardes RA, de Paulo RS, Pereira LO, Duarte MA, Ordinola-Zapata R, de Azevedo JR. Comparative study of cone beam computed tomography and intraoral periapical radiographs in diagnosis of lingual-simulated external root resorptions. *Dent Traumatol* 2012;**28**:268–72.
110. Neves FS, Vasconcelos TV, Vaz SL, Freitas DQ, Haiter-Neto F. Evaluation of reconstructed images of different voxel sizes of acquisition in the diagnosis of simulated external root resorption using cone beam computed tomography. *Int Endod J* 2012;**234**–9.
111. Patel S, Dawood A, Wilson R, Horner K, Manocci F. The detection and management of root resorption lesions using intraoral radiography and cone beam computed tomography- an in vivo investigation. *Int Endod J* 2009;**42**:831–8.
112. Estrela C, Reis Bueno M, Alencar AH, Mattar R, Valladares Neto J, Azevedo BC, et al. Method to evaluate inflammatory root resorption by using cone beam computed tomography. *J Endod* 2009;**35**:1491–7.
113. Ingle JI. A standardized endodontic technique utilizing newly designed instruments and filling materials. *Oral Surg Oral Med Oral Pathol* 1961;**14**:83–91.
114. de Chevigny C, Dao TT, Basrani BR, Marquis V, Farzaneh M, Abitbol S, et al. Treatment outcome in endodontics: the Toronto study—phase 4: initial treatment. *J Endod* 2008;**34**:258–63.
115. Alhadainy HA. Root perforations. A review of literature. *Oral Surg Oral Med Oral Pathol* 1994;**78**:368–74.
116. Kamburoğlu K, Yeta EN, Yilmaz F. An ex vivo comparison of diagnostic accuracy of cone-beam computed tomography and periapical radiography in the selection of furcal perforations. *J Endod* 2015;**41**:696–702.
117. Shemesh H, Cristescu RC, Wesselink PR, Wu M-K. The use of cone-beam computed tomography and digital periapical radiographs to diagnose root perforations. *J Endod* 2011;**4**:513–6.
118. Diangelis AJ, Andreasen JO, Ebeleseder KA, Kenny DJ, Trope M, Sigurdsson A, et al. International Association of Dental Traumatology guidelines for the management of traumatic dental injuries: 1. Fractures and luxations of permanent teeth. *Dent Traumatol* 2012;**28**:2–12.
119. Flores MT, Andersson L, Andreasen JO, Bakland LK, Malmgren B, Barnett F, et al. Guidelines for the management of traumatic dental injuries: I. Fractures and luxations of permanent teeth. *Dent Traumatol* 2007;**23**:66–71.
120. Andreasen JO, Lauridsen E, Andreasen FM. Contradictions in the treatment of traumatic dental injuries and ways to proceed in dental trauma research. *Dent Traumatol* 2010;**26**:16–22.
121. Roig M, Espona J, Mercadé M, Duran-Sindreu F. Horizontal root fracture treated with MTA, a case report with a 10-year follow-up. *Dent Traumatol* 2011;**27**:460–3.
122. Ilgüy D, Ilgüy M, Fisekcioglu E, Bayirli G. Detection of jaw and root fractures using cone beam computed tomography: a case report. *Dentomaxillofac Radiol* 2009;**38**:169–73.
123. Costa FF, Gaia BF, Umetsubo OS, Paraiso Cavalcanti MG. Detection of horizontal root fracture with small-volume cone-beam computed tomography in the presence and absence of intracanal metallic post. *J Endod* 2011;**37**:1456–9.
124. Bornstein MM, Wölner-Hansen AB, Sendi P, von Arx T. Comparison of intraoral radiography and limited cone beam computed tomography for the assessment of root-fractured permanent teeth. *Dent Traumatol* 2009;**25**:571–7.
125. May JJ, Cohenca N, Peters OA. Contemporary management of horizontal root fractures to the permanent dentition: diagnosis radiologic assessment to include cone-beam computed tomography. *J Endod* 2013;**39**(3 Suppl):S20–5.