

CASE REPORT/CASE REPORT

Immediate Crown Replacement: a case report of extensive radicular fracture with intra-canal anchorage

Case report relativo alla cementazione adesiva immediata, con ancoraggio intra-canalare, di corona naturale in seguito a frattura radicolare

KEYWORDS

Dental injury,
Complicated crown-radicular
fractures,
Open flap isolation,
Reattachment,
Fiber post.

PAROLE CHIAVE

Traumi dentali,
fratture corono radicolari,
cementazione adesiva,
riattacco,
perni in fibra di vetro.

Abstract

Aim: Fracture by trauma is one of the most common type of dental injury in the permanent dentition. The purpose of this case report is to present the multidisciplinary management of a subgingival crown-root fracture in one patient.

Summary: In this article we report one case of complicated crown-radicular fractures reattachment, in a traumatized maxillary permanent central incisor, which was treated with a novel method preserving coronal integrity after fiber post placement.

Obiettivi: La frattura da trauma è uno dei tipi più comuni di danno dentale nella dentizione permanente. Lo scopo di questo case report è di presentare la gestione multidisciplinare di una frattura corono-radicolare sub-gengivale.

Sommario: In questo articolo riportiamo un caso di cementazione adesiva di una frattura corono-radicolare complicata di un incisivo laterale mascellare permanente traumatizzato. L'elemento è stato trattato con nuovo metodo preservando l'integrità coronale dopo il posizionamento di un perno in fibra di vetro.

Introduction

Traumatic dental injury is a neglected oral condition, despite its relatively high prevalence and significant impact on individuals and public relations (1). Management of traumatic dental injuries (TDI) should involve a multidisciplinary approach to optimize healing while maintaining function and esthetics (2).

Reports suggest that most dental injuries occur during the first two decades of life, usually around 8-12 years and that 70% of such injuries involve the maxillary central incisors followed by maxillary lateral incisors and mandibular incisors (3).

Traumatic lesions in the permanent dentition have an incidence that ranges from 15.2% to 17.8%. The most frequent causes are falls, accidents occurred during sports or as a consequence of violent episodes (4). There have been numerous classifications since the 50s of the last century that tried to codify traumatic dental lesions based on topographic and morphological criteria. The International Association of Dental Traumatology (IADT) has developed in 2017 a consensus statement based on a review of the dental scientific literature (5).

It's an evolution of the Andreasen Classification (1950) and try to propose different therapies for different clinical situations.

**Davide Guglielmi*,
Fabio G.M. Gorni.**

San Raffaele University, Milan.

Received 2019, February 27

Accepted 2019, March 10

Corresponding author

Dr. Davide Guglielmi

Studio Dentistico Fabio Gorni & Partners | Via San Raffaello Sanzio 8 | 20149 Milano | E-mail: dr.davideguglielmi@gmail.com

Peer review under responsibility of Società Italiana di Endodonzia

[10.32067/GIE.2019.33.01.08](https://doi.org/10.32067/GIE.2019.33.01.08)

Società Italiana di Endodonzia. Production and hosting by Ariesdue. This is an open access article under the CC BY-NC-ND license (<http://creativecommons.org/licenses/by-nc-nd/4.0/>).

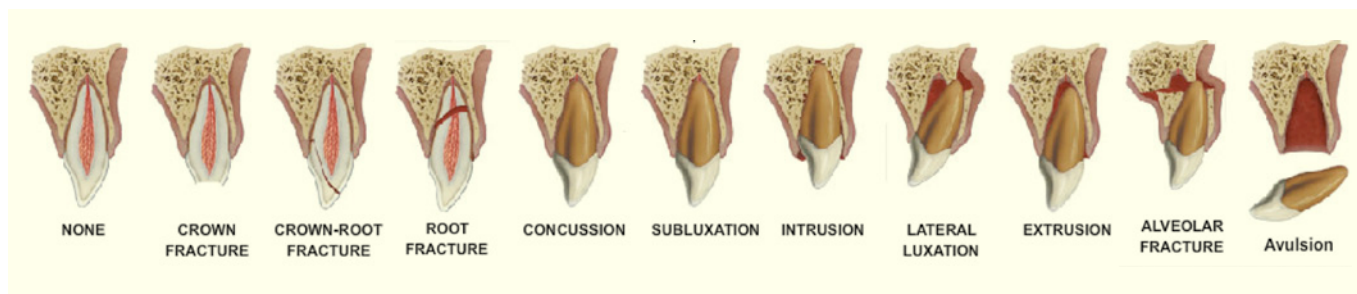


Figure 1
Schematic Illustration about Fractures and Luxations of Permanent Teeth - Diangelis AJ, Andreassen JO, Ebeleseder KA, et al. International Association of Dental Traumatology guidelines for the management of traumatic dental injuries: 1. Fractures and luxations of permanent teeth. Dent Traumatol 2012;28:2-12.

This classification is divided in (Fig. 1):

- infractions,
- enamel fractures,
- enamel-dentine fractures,
- enamel-dentine-pulp fractures,
- crown-root fracture without pulp exposure,
- crown-root fracture with pulp exposure (complicated),
- root fracture,
- alveolar fracture,
- concussion,
- subluxation,
- concussion,
- subluxation,
- extrusive luxation,
- lateral luxation,
- intrusive luxation.

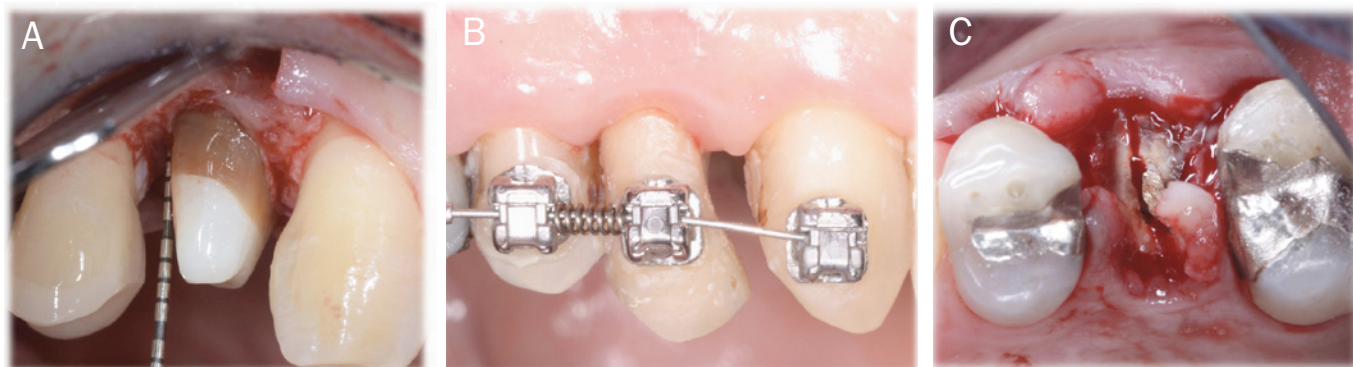- removal of the coronal fragment with subsequent endodontic treatment, after that gengivectomy/gingivectomy + ostectomy and osteoplasty and to conclude, a restoration with a post retained crown: this treatment is only indicated in crown-root fractures with palatal subgingival extension;
- orthodontic extrusion of the remaining root: removal of the coronal segment with subsequent endodontic treatment, and orthodontic extrusion of the remaining tooth with sufficient length after extrusion to support a post-retained crown;
- surgical extrusion: removal of the mobile fracture fragment with subsequent surgical reposition of the root in a more coronal position;
- extraction with immediate or delayed implant-retained crown restoration or a conventional bridge (Fig. 2) (2-5).

Complicated crown-radicular fractures, involving the enamel, dentin, and pulp account for up to 20% of all TDJ with the majority in the maxillary anterior region (2-6). From the guidelines of the International Association of Dental Traumatology endorsed by the American Academy of Pediatric Dentistry in cases of crown-radicular fractures with pulp exposure (without open apex), emerged different therapies:

The challenge is to identify the most suitable treatment for a given patient using a combination of evidence-based guidelines and clinical experience (7).

Here we report a case where a new conservative approach was performed, with included the reattachment of the fractured segment, root canal therapy, or surgery and the insertion of a fiber post.

Figure 2
Different clinical images about the therapy of three different crown-radicular fractures with pulp exposure: **a)** surgical crown lengthening **b)** orthodontic extrusion (photo with kindly permission of Dr. D. Damaiola, Dr. G. & G. Bormida) **c)** extraction therapy for the presence of a vertical fracture.



Case Report

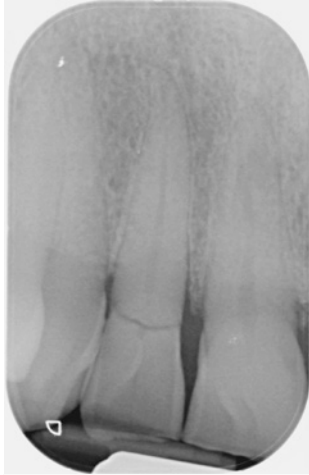

Figure 3

The preoperative radiograph shows clearly a root fracture which is higher than the mesial and distal bone peaks. It also shows how the fracture enters the pulp chamber of the lateral incisor at issue.

This case report refers to a 70-year-old patient with a fractured lateral incisor. Medical history was non contributory. Clinical and radiographic examination revealed a complicated oblique crown fracture on element 1.2 that extended sub-gingivally in the buccal aspect. In this case we noticed bleeding of the gingival sulcus, sensibility testing was negative and there was tenderness during the percussion test (Fig. 3). The fractured segment was held in place by the gingival attachment. After administration of local anesthesia (1.0cc of articaine 2% with 1:100,000 adrenaline), the fractured segment was extracted with great care, in order to preserve hard and soft tissues (Fig. 4A, 4B).

The fractured segment was then cleaned with 2% chlorhexidine solution and stored in isotonic saline solution (Fig. 5). Isolation of the operative field during root canal therapy and cementation phases was very complex due to the peculiar shape of the fracture. For this reason an intra-sulcular incision was performed using a 15c surgical blade (Swann Morton Surgical Blades - Sheffield - England). The papillae were incised apico-coronally in order to preserve the interdental vascular supply (8) (Fig. 6).

Once the surgical flap had been raised, a buccal osseous resective surgery (ORS) performed in order to have at least 2 mm of the exposed root coronally to the alveolar crest: these 2 mm will be very important, so as to provide space for the correct formation of the supracrestal attachment (9).

At this point the rubber dam (Dental Dam

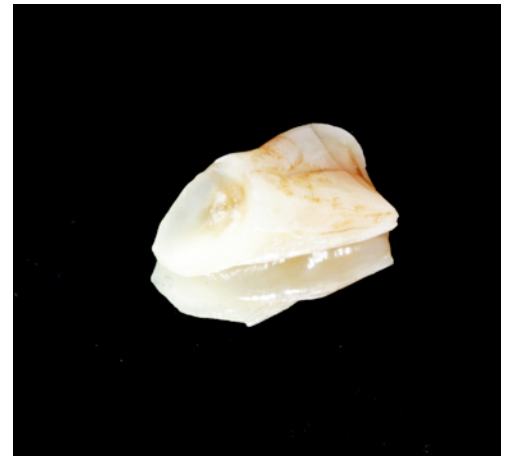

Figure 5

In this detailed view the shape of the fracture can be seen: on the buccal aspect there is a bevel which is at least 3 mm more apical than the palatal aspect.

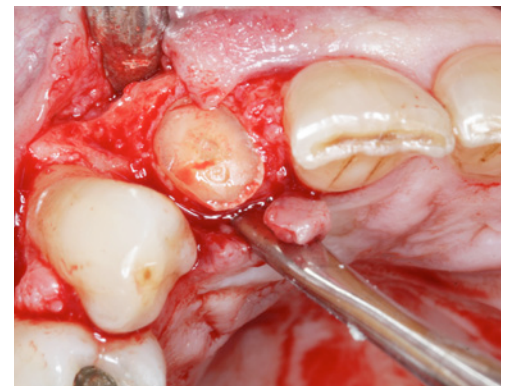

Figure 6

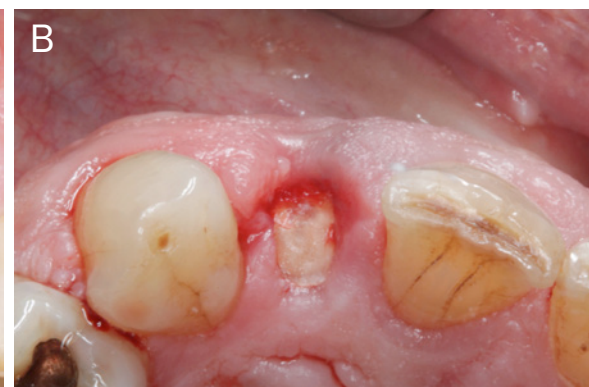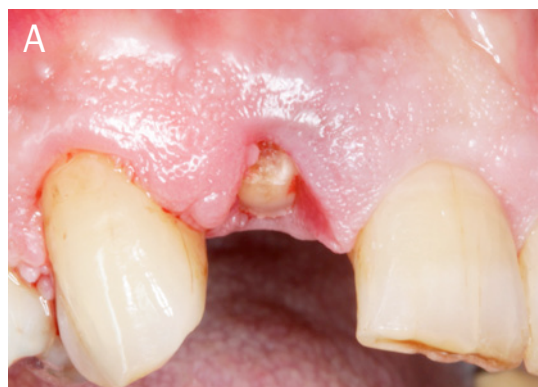In this detailed view the surgical flap has been raised.

Figure 4A

Only after a correct diagnosis and local anesthesia it is possible to start to remove the fractured portion of the tooth.

Figure 4B

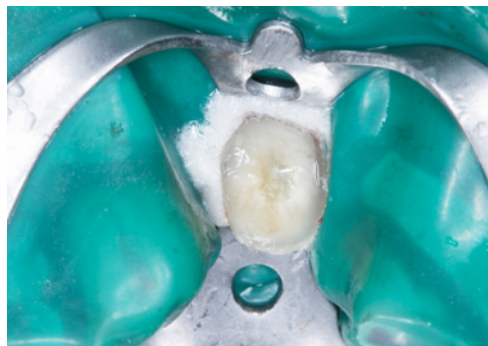Occlusal view of the root: it is possible to notice a more significant bleeding on the buccal aspect due to the bigger extension of the lesion apico-coronally. The exposure of the pulp is also noticeable.



- Coltene - Cuyahoga Falls - USA) was placed.

The rubber dam was chemically treated in order to reduce the possibility of bac-

Figure 7
Rubber dam placed.



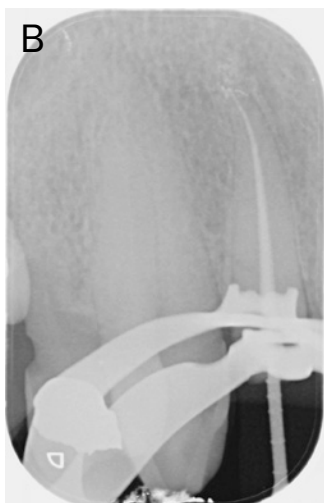
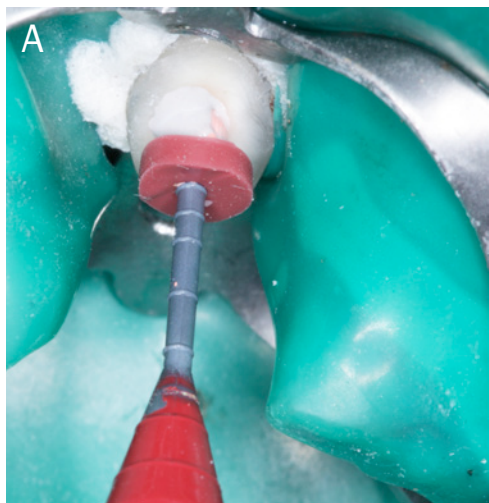
terial contamination: the tooth was isolated, without suturing the underlying flap, with a rubber sheet which has been treated with a mouth-wash containing 0,2% chlorexidine (Curaden - Curasept 0,20% + Ialuronic Acid) (Fig. 7).

Once the rubber dam had been positioned with a 9s clamp (Hu-friedy - Chicago - USA) the root canal treatment was performed and the post space was prepared (M-Two NiTi Instruments - Sweden and Martina - Padova - Italy).

The root canal treatment has been performed using Ni-Ti instruments with the following tapers and fashion: Pre-flaring was performed by 10 (diameter)/4% (taper) and 15/05 M-Two Instruments. Working length (WL) was reached with the previous two instruments for shaping in order to continue with 20/06 followed by 25/06 (M-Two NiTi Instruments - Sweden and Martina - Padova - Italy).

For finishing the following two Pro-

Figure 8A
Canal obturation with
thermafil system.
Figure 8B
Periapical Radiography.



Taper instruments were used: F2 35/08, F3 30/09 (DentSply - Maillefer Instruments - Ballaigues - Switzarland).

A 5% sodium hypochlorite solution was used and activated for cleaning, with Irri-safe ultrasonic tips (Irri-Safe 20-25 - Acteon Satelec -Merignac - France).

A 3d obturation was achieved using ThermoFil system (DentSply - Maillefer Instruments - Ballaigues - Switzarland) (Fig. 8A, 8B).

2/3 of the canal were empty and were cleaned with ultrasonic tip (ET18D - Acteon Satelec -Merignac - France) and a specific brush. It is extremely important to evaluate the size of the post by taking into account the depth of the empty canal and the intra-coronal space.

In this case a post 055/06 taper (Sweden and Martina - Padova - Italy) was selected and then reduced with a diamond disk outside the mouth.

Afterward the tooth crown has to be prepared by removing both mechanically (Burr FG D18 CB Intensive - Montagnola - Switzerland) and chemically (5% Sodium hypochlorite) the remains of the pulpal chamber in order to receive the coronal part of post and to avoid future discolorations.

It is necessary to try the perfect juxtaposition of the crown with the post before cementation: the post does not have to create any sort of obstacle neither in height or in width (Fig. 9A, 9B).

The post was prepared with alcohol and bonding as suggested by the producer of the sealer. In this case we used the Dentsply Core&post System (DentSply - Maillefer Instruments - Ballaigues - Switzarland): we started by cleaning the post with alcohol. Then we applied the Prime and Bond XP/SCA (DentSply - Maillefer Instruments - Ballaigues - Switzarland) mixture on the entire post for at least 5 seconds and after we removed the solvent by blowing gently with air being careful to protect the post from light.

In the meantime both the root canal and the crown has been etched with 37% ortho-phosphoric acid (Ultradent Products - Utah - USA) for 15 seconds

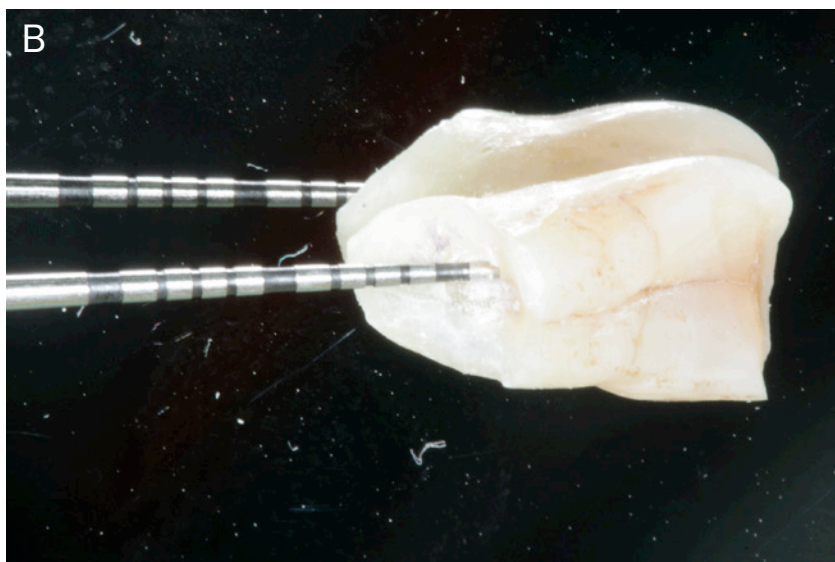



Figure 9A
Evaluation of the post size's.

Figure 9B
Crown preparation.

(each) and then we gently removed the water used for rinsing with air and paper point: it's important not to desiccate dentine (Fig. 10A, 10B).

Afterwards we applied Prime&Bond XP/SCA into the canal and inside the crown cavity and we left it undisturbed for 20 seconds. Then, the excess of primer and bonding solutions was removed and the solvent was evaporated by blowing gently with air.

At this point we applied Core-x flow (DentSply - Maillefer Instruments - Ballaigues - Switzzarland) directly in the canal and then placed the post in its final position and we stabilized it.

We had to position at once (post must be

fully seated in maximum 40 seconds) core-x flow (DentSply - Maillefer Instruments - Ballaigues - Switzzarland) in the coronal cavity with the post and then place the crown in its natural position. Once removed the excess material, the sealer must be photo-polymerized as if it were a composite inlay (11).

In the end we had to light cure for at least 20 seconds each side of the crown or wait 3 and 1/2 minutes (Fig. 11A, 11B), Right after removing the rubber dam we did not have to worry about the colour difference: it will be evaluated after the rehydration of the tooth.

At this point the tooth must be polished and we must be careful not to leave excess sealer on the junction line of the fracture (Fig. 12).

A monofilament non absorbable surgical suture, 5/0 PTFE (high-density polytetrafluoroethylene polymer) was used in order to avoid plaque accumulation in the days following the procedure (12).

In the post-operative radiograph the correct root canal obturation, the insertion of the fiber post and the perfect juxtaposition of the fractured segment was evaluated (Fig. 13A, 13B).

Sutures were removed 14 days after the procedure.

Follow-up visits confirmed the success of treatment based on clinical (probing depth, bleeding on probing, mobility, dyschromia) and radiographic evaluations (absence of apical radiolucency, thickening of the periodontal ligament).

The patient remained pain-free with good function and aesthetics during a follow-up period of 5 years (Fig. 14A, 14B).

Discussion

Management of complicated crown fragments has undergone major changes in recent years. Regarding crown-root fracture, several treatment options were described, such as mucogingival flaps, procedures involving ORS surgery or surgical extrusion followed by reattachment of the original fragment (12).

The remarkable advances in adhesive systems and resin-based composites

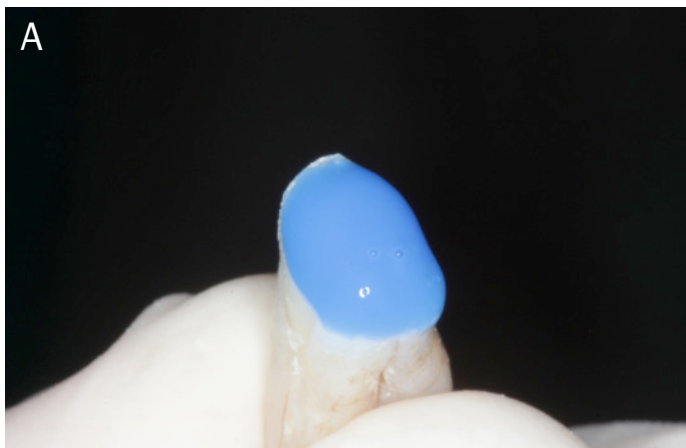


Figure 10A Etching phases on the root and the fractured crown.

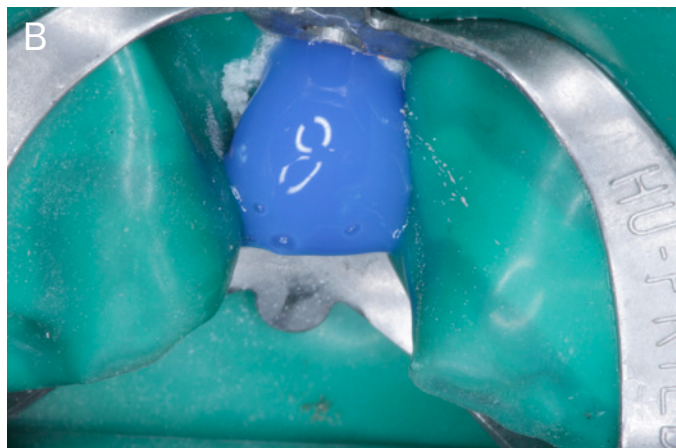

Figure 10B Cementation phases.

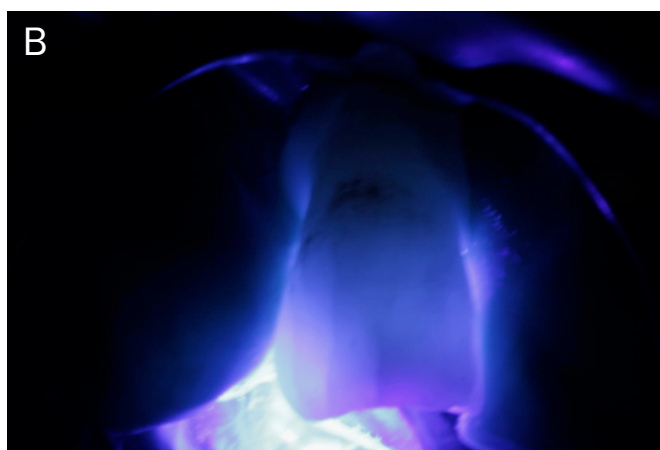
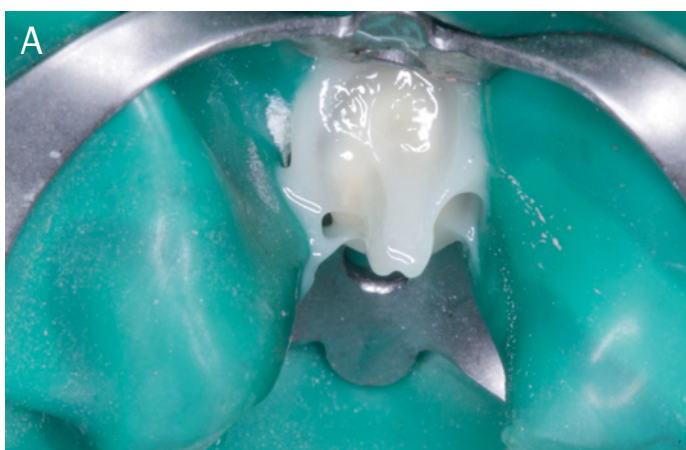
Figure 11
Cementation phases.

made reattachment procedures more achievable (7).

Because of this, other option includes the restoration of the tooth crown with a restorative material or prosthetic rehabilitation of the tooth depending on the location of the fracture line (13).

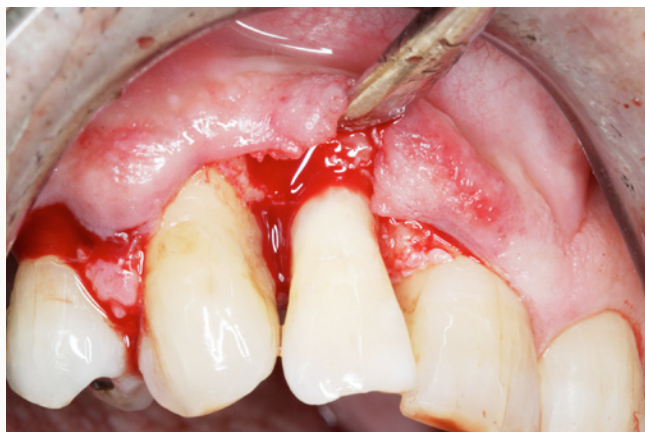In the cases where the fractured segment is available, reattachment should always be attempted. As described in previous studies, such as Chosack and Eidelman in 1964, the adhesive reattachment of the original fragment offers a conservative, esthetic, and cost-effective restorative option to reinstate the natural shape, contour, surface texture, occlusal alignment, and colour of the tooth (12-14).

Previous studies indicated that the reattachment of the fractured fragment without any preparation of the coronal or root fragments results in lower bonding values (15, 16).

In this case, an internal dentinal groove was prepared on the coronal fragment to provide a higher mechanical strength and longevity.

To reinforce the cervical level of the reattached tooth, it is recommended to

Figure 12
It is possible to see the perfect juxtaposition of the fracture which enables us to remove all excess material.



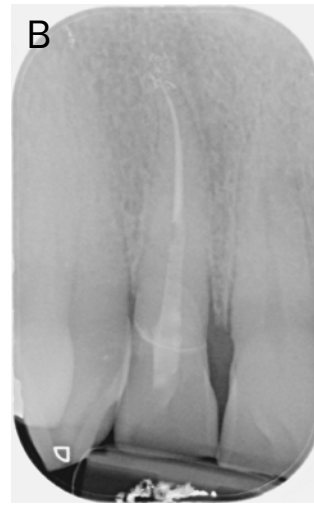
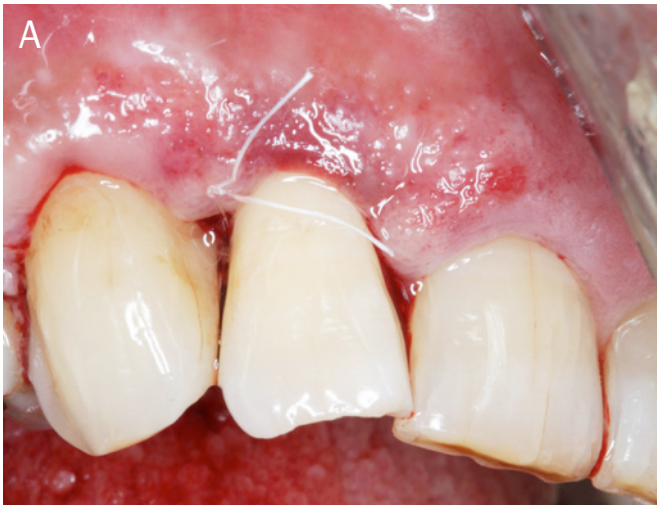
Figure 13A
Two single stitches have been placed on the mesial and distal papilla.

Figure 13B
Post-operative radiography.

use an intra-canal post because of the potential of the post to interlock the coronal and the root portion and to minimize the stress on the reattached tooth fragment (17).

Recently, different types of post materials have been introduced into the dental practice such as carbon fiber, quartz, and glass fiber (18).

The use of fiber post with composite core is recommended as it can create a monoblocco which is a multilayered structure with no weak interlayer interfaces (19).

Conclusions

In case of complex fractures, where the fractured segment is available and there is close approximation of the segment to the remaining tooth, root canal treatment followed by reattachment of the fractured segment with fiber post reinforcement is a feasible option.

This minimally invasive approach seems to be predictable, allowing to reduce costs and the number of interventions for the patient as compared to many other procedures methods.

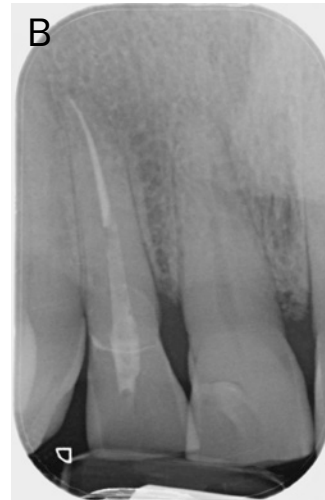
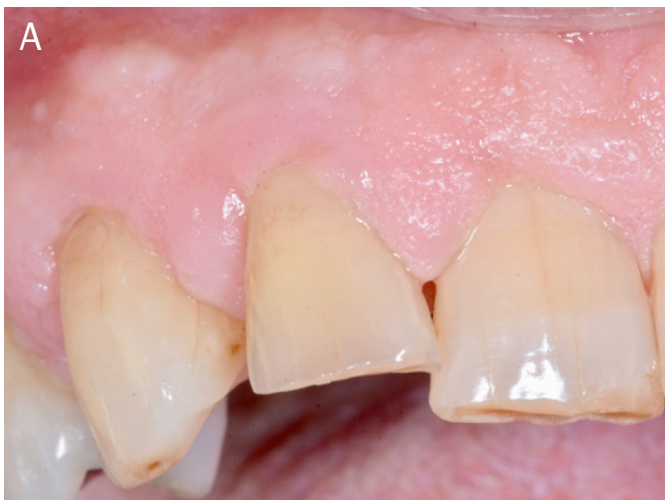
Figure 14A
5 years follow up photo.

Figure 14B
5 years follow-up periapical radiography.

In addition, satisfying function of the treated elements the procedure provides good and long-lasting esthetics, because the original morphology, color, and surface texture are maintained.

Clinical Relevance

Reattachment of fractured tooth fragments offers a viable restorative option

for the clinician because it restores tooth function and esthetics with the use of a very conservative and cost-effective approach.

Conflict of Interest

The authors declare that there is no conflict of interests regarding the publication of this paper.

References

1. Glendor U, Marcenes W, Andreasen JO. Classification, epidemiology and etiology. In: *Textbook and color atlas of traumatic injuries to the teeth*. 4th ed, Andreasen JO, Andreasen FM, Andersson Leds, Blackwell, Oxford. 2007. 217-254.
2. Diangelis AJ, Andreasen JO, Ebeleseder KA, et al. International Association of Dental Traumatology guidelines for the management of traumatic dental injuries: 1. Fractures and luxations of permanent teeth. *Dent Traumatol*. 2012; 28:2-12.
3. Ojeda-Gutierrez F, Martinez-Marquez B, Arteaga-Larios S, et al. Management and follow-up of complicated crown fractures in young patients treated with partial pulpotomy. *Case Rep Dent*. 2013. 59:63-75.
4. Petti S, Glendor U, Andersson L. World traumatic dental injury prevalence and incidence, a meta-analysis - One billion living people have had traumatic dental injuries *Dent Traumatol*. 2018 Apr; 34(2):71-86.
5. Guidelines for the Management of Traumatic Dental Injuries: 1. Fractures and Luxations of Permanent Teeth. *Pediatr Dent*. 2017. Sep 15;39(6):401-411.
6. Sapna, CM, Priya R, Sreedevi NB, Rajan, RR, Kumar R (2014). Reattachment of fractured tooth fragment with fiber post: a case series with 1-year followup. *Case Reports in Dentistry*, 2014(2), 376267-5.
7. Tonini R. An Innovative Method for Fragment Reattachment after Complicated Crown Fracture. *J Esthet Restor Dent*. 2017 May 6;29(3):172-1
8. De Sanctis M, Clementini M. Flap approaches in plastic periodontal and implant surgery: critical elements in design and execution. (2014). *Journal of Clinical Periodontology*. 2014. 41(s15), S108-S122.
9. Schmidt JC, Sahrman P, Weiger R, Schmidlin PR, Walter C. Biologic width dimensions—a systematic review. *J Clin Periodontol*. 2013 May; 40 (5):493-504.
10. Mangani , Putignano A, Cerutti R. Guidelines for Adhesive Dentistry: The key to success. Quintessence Pub. 2009
11. Burkhardt R, Preiss A, Joss A, Lang N. P. Influence of suture tension to the tearing characteristics of the soft tissues: an in vitro experiment. *Clinical Oral Implants Research*. 2008. 19, 314-319.
12. Mese M, Akcay M, Yasa B, Akcay H. Case Report Multidisciplinary Management of Complicated Crown-Root Fracture of an Anterior Tooth Undergoing Apexification. *Case Reports in Dentistry*, 2015. 1-5.
13. Nandlal B, Daneswari V. Restoring biological width in crown-root fracture: a periodontal concern. *Journal of Indian Society of Pedodontics and Preventive Dentistry*. 2007 vol. 25, supplement, pp. S20-S24.
14. El-Askary FS, Ghalab OH, Eldemerdash FH, Ahmed OIR, Fouad SA, Nagy MM, Reattachment of a severely traumatized maxillary central incisor, one-year clinical evaluation: a case report, *The Journal of Adhesive Dentistry*. 2006 vol. 8, no. 5, pp. 343-349.
15. Reis A, Loguercio AD, Kraul A, Matson E. Reattachment of fractured teeth: a review of literature regarding techniques and materials. *Operative Dentistry*. 2004 vol. 29, no. 2, pp. 226-233.
16. Demarco FF, Fay RM, Pinzon LM, Powers JM. Fracture resistance of re-attached coronal fragments—influence of different adhesive materials and bevel preparation. *Dental Traumatology*. 2004. vol. 20, no. 3, pp. 157-163.
17. Kumar A, Jyothi KN, Reattachment of fractured tooth using self etching adhesive and esthetic fiber post. *Journal of Dental Sciences and Research*. 2010 vol. 1, pp. 75-83.
18. Asmussen E. et al. Stiffness, elastic limit, and strength of newer types of endodontic posts. *Journal of Dentistry*. 1999 27: 275-278.
19. Hayashi M. et al. Fracture resistance of pulpless teeth restored with post-cores and crowns. *Dental Materials* 2006. 22.5: 477-485.