


# ENDODONZIA

GIORNALE ITALIANO DI



## ► Original Articles

### **THE BEST POSTER SIE AWARD**

*Root canal morphology of lower lateral incisors: a CBCT in vivo study*

### **RICCARDO GERBEROGLIO AWARD**

*Antibacterial effects of two synthetic peptides against Enterococcus faecalis biofilms: a preliminary in vitro study*

### **FRANCESCO RIITANO AWARD**

*Evaluation of the root canal tridimensional filling with warm vertical condensation, carrier-based technique and single cone with bioceramic sealer: a micro-CT study*

## ► Mini Review Article

*COVID-19 and dental practice: overview and protocols during pandemic*

## ► Position Statement

*Asepsis in Endodontics*

## ► Winners of 36° SIE National Congress

### ► Case Series

#### **GIORGIO LAVAGNOLI AWARD**

*Treatment of obliterated root canals using various guided endodontic techniques: a case series*



Società Italiana  
di Endodonzia



# CICLO DI DECONTAMINAZIONE

Simit Dental offre una soluzione completa per la disinfezione e sterilizzazione nello Studio Odontoiatrico





Diversi livelli di umidità.  
Stessa forza adesiva.

## Prime&Bond active™ Adesivo universale

PART OF THE **CLASS II**  SOLUTION™

Grazie alla nuova tecnologia brevettata Active-Guard™  
assicura:

- Prestazioni adesive affidabili sia su dentina eccessivamente bagnata che asciutta
- Versatilità di utilizzo: con tutti i metodi di mordenzatura (total-etch, self-etch e mordenzatura selettiva) e per tutti i restauri diretti e indiretti
- Basso spessore del film
- Nessuna sensibilità post-operatoria
- Formulazione brevettata priva di HEMA, TEGDMA o bisfenolo
- Tempi di lavorabilità lunghi e riduzione degli sprechi

Per saperne di più visita il sito [www.dentsplysirona.com](http://www.dentsplysirona.com) o contatta Simit Next al numero 0376.267811

THE DENTAL  
SOLUTIONS  
COMPANY™

 Dentsply  
Sirona

 Simit® NEXT  
Endodonzia & Conservativa

## EDITORIAL BOARD

### Editor in chief

Prof. RENGO SANDRO  
Professor and Chair of Endodontics,  
Federico II University of Naples  
Former President of SIE

### Associate Editors

Prof. DOTT. PLOTINO GIANLUCA  
Private practice in Rome

Prof. PRATI CARLO  
Full Professor of Endodontics and  
Operative Dentistry, Dean Master  
in Clinical Endodontology  
Head Endodontic Clinical Section  
Dental School, University of Bologna

### Assistant Editors

Prof. BERUTTI ELIO  
Professor and Chair of Endodontics  
University of Turin Dental School  
Former President of SIE

Prof. CERUTTI ANTONIO  
Professor and Chair of Restorative  
Dentistry University of Brescia  
Dental School  
Active member of SIE

Prof. COTTI ELISABETTA  
Professor and Chair of Endodontics  
University of Cagliari Dental School  
Active member of SIE

Prof. DI LENARDA ROBERTO  
Professor and Chair of Endodontics  
Dean of University of Trieste Dental  
School

Prof. GAGLIANI MASSIMO  
Professor and Chair of Endodontics  
University of Milan Dental School

Prof. GAMBARINI GIANLUCA  
Full Professor and Chair  
of Endodontics Sapienza  
University of Rome

Prof. PIATTELLI ADRIANO  
Professor and Chair of Oral Pathology  
University of Chieti Dental School

### Editorial Committee

Prof. AMATO MASSIMO  
Associate Professor  
University of Salerno  
Department of Medicine and Surgery  
Active member of SIE

Dr. BADINO MARIO  
Private practice in Milan  
Active member of SIE

Dr. CASTRO DAVIDE FABIO  
Private practice in Varese  
Active member of SIE

Dr. CORAINI CRISTIAN  
Private practice in Milan  
Active member of SIE

Dr. FABIANI CRISTIANO  
Private practice in Rome  
Active member of SIE

Dr. FORNARA ROBERTO  
Private practice in Magenta, Milan  
Certified Member of ESE  
Active member of SIE

Dr. PISACANE CLAUDIO  
Private practice in Rome  
Active member of SIE

Prof. RE DINO  
Professor and Chair of Prosthodontics  
University of Milan Dental School  
Active member of SIE

Dr. SPAGNUOLO GIANRICO  
Associate Professor Federico II  
University of Naples  
Member of SIE

Dr. TASCHIERI SILVIO  
Private practice in Milan  
Active member of SIE

Dr. TOSCO EUGENIO  
Private practice in Fermo  
Active member of SIE

### Editorial Board

Dr. BARBONI MARIA GIOVANNA  
Private practice in Bologna  
Active member of SIE

Dr. BATE ANNA LOUISE  
Private practice in Cuneo  
Active member of SIE

Dr. BERTANI PIO  
Private practice in Parma  
Former President of SIE

Prof. CANTATORE GIUSEPPE  
Professor of Endodontics  
University of Verona Dental School  
Former President of SIE

Dr. CASTELLUCCI ARNALDO  
Private practice in Florence  
Former President of SIE  
Former President of ESE

Prof. CAVALLERI GIACOMO  
Professor and Chair of Endodontics  
University of Verona Dental School  
Former President of SIE

Dr. COLLA MARCO  
Private practice in Bolzano  
Active member of SIE

Prof. GALLOTTINI LIVIO  
Professor and Chair of Endodontics II  
University of Rome La Sapienza  
Dental School  
Active member of SIE

Prof. GEROSA ROBERTO  
Professor and Chair of Endodontics  
University of Verona Dental School

Dr. GIARDINO LUCIANO  
Private practice in Crotona  
Member of SIE

Dr. GORNI FABIO  
Private practice in Milan  
Former President of SIE

Dr. GRECO KATIA  
Lecturer in Endodontology  
University of Catanzaro  
Active member of SIE

Prof. KAITAS VASSILIOS  
Professor of Endodontics  
University of Thessaloniki (Greece)  
Active member of SIE

Dr. LENDINI MARIO  
Private practice in Turin  
Active member of SIE

Prof. MALAGNINO VITO ANTONIO  
Professor and Chair of Endodontics  
University of Chieti Dental School  
Former President of SIE

Dr. MALENTACCA AUGUSTO  
Private practice in Rome  
Former President of SIE

Dr. MANFRINI FRANCESCA  
Private practice in Riva del Garda  
Active member of SIE

Dr. MARCOLI PIERO ALESSANDRO  
Private practice in Brescia

Dr. MARTIGNONI MARCO  
Private practice in Rome  
Former President of SIE

Prof. PECORA GABRIELE  
Former Professor of Microscopic  
Endodontics Post-graduate courses  
University of Pennsylvania (USA)  
Honorary Member of SIE

Dr. PONGIONE GIANCARLO  
Private practice in Naples  
Active member of SIE

Prof. RICCITIELLO FRANCESCO  
Professor of Restorative Dentistry  
University of Naples Dental School  
Former President of SIE

Dr. SBERNA MARIA TERESA  
Private practice in Milan  
Active member of SIE

Dr. SCAGNOLI LUIGI  
Private practice in Rome  
Active member of SIE

Prof. TESTORI TIZIANO  
Private practice in Como  
Former Editor of Giornale Italiano  
di Endodonzia

### International Editorial Board

ANG LESLIE  
Clinical assistant professor of  
Endodontics Division of Graduate  
Dental Studies National University  
of Singapore

BOVEDA CARLOS  
Professor Post-graduate Courses  
University of Caracas (Venezuela)

CANCELLIER PETER  
Clinical instructor at the University  
of Southern California (USA)  
School of Dentistry Graduate  
Endodontic Program President  
of the California State Association  
of Endodontists

CHO YONGBUM  
International lecturer and researcher  
Private practice in Seoul (Korea)

DEBELIAN GILBERTO  
Adjunct Associate Professor  
Department of Endodontics  
University of North Carolina,  
Chapel Hill University of  
Pennsylvania, Philadelphia (USA)

FIGUEIREDO JOSE ANTONIO  
Clinical lecturer in Endodontology  
Eastman Dental Institute, London (UK)

GLASSMAN GARY  
International lecturer and researcher  
Private practice in Ontario (Canada)  
Editor in Chief of Dental Health

GLICKMAN N. GERARD  
Professor and Chairman of  
Endodontics School of Dentistry  
University of Washington (USA)

HIMEL T. VAN  
Professor of Endodontics School  
of Dentistry University  
of Tennessee (USA)

HUTTER W. JEFFREY  
Professor and Chairman of  
Endodontics Goldman School of Dental  
Medicine Boston University (USA)

JEERAPHAT JANTARAT  
Professor of Endodontics  
Dental School Mahidol University  
of Bangkok (Thailand)

KARTAL NEVIN  
Professor of Endodontics  
Marmara University Istanbul  
School of Dentistry (Turkey)

KHAYAT BERTRAND  
International lecturer and researcher  
Private practice in Paris (France)

MOUNCE RICHARD  
International lecturer and researcher  
Private practice in Portland  
(Oregon, USA)

NERVO GARY  
International lecturer and researcher  
Private practice in Melbourne  
(Australia)

PUENTE CARLOS GARCIA  
Professor of Endodontics  
University of Buenos Aires  
School of Dentistry (Argentina)

ROIG MIGUEL  
Professor and Head Department of  
Restorative Dentistry and Endodontics  
Universitat Internacional de Catalunya,  
Barcelona (Spain)

RUDDLE J. CLIFFORD  
Assistant Professor  
Dept. of Graduate Endodontics  
Loma Linda University (USA)

TROPE MARTIN  
Professor and Chairman of  
Endodontics School of Dentistry  
University of North Carolina (USA)

VERA JORGE  
Professor of Endodontics  
University of Tlaxcala (Mexico)





**F22ALIGNER**  
BIOLOGIC TEETH ALIGNER

**TALMENTE INVISIBILE  
CHE VE LO POSSIAMO  
SOLO SPIEGARE.**

I risultati si vedono,  
**F22 Aligner** no.

  
**sweden & martina**





Semplice, veloce, efficace.



  
**sweden & martina**  
[www.sweden-martina.com](http://www.sweden-martina.com)

## SIE BOARD 2020

**Editor in Chief**  
Sandro Rengo

**Associate Editors**  
Gianluca Plotino, Carlo Prati

**Assistant Editors**  
Elio Berutti, Antonio Cerutti, Elisabetta Cotti,  
Roberto Di Lenarda, Massimo Gagliani,  
Gianluca Gambarini, Adriano Piattellii

**Editorial Committee**  
Massimo Amato, Mario Badino, Davide Fabio Castro,  
Cristian Coraini, Cristiano Fabiani, Roberto Fornara,  
Claudio Pisacane, Dino Re, Gianrico Spagnuolo,  
Silvio Taschieri, Eugenio Tosco

## SIE - BOARD OF DIRECTORS

**Past President**  
Prof. Francesco Riccitiello

**President**  
Dott.ssa Maria Teresa Sberna

**Elected President**  
Dott. Roberto Fornara

**Vice President**  
Dott. Claudio Pisacane

**Secretary**  
Prof. Massimo Gagliani

**Treasurer**  
Dott. Cristian Coraini

**Cultural Coordinator**  
Dott. Andrea Polese

**Communication Coordinator**  
Dott.ssa Denise Irene Karin Pontoriero

**Advisers**  
Dott.ssa Katia Greco, Dott. Franco Ongaro

### SIE - Società Italiana di Endodonzia

**Legal Head Office:**  
Piazza degli Ulivi 27/4  
16011 Arenzano (GE)

**Headquarters:**  
Via Pietro Custodi, 3  
20136 Milano (MI)

**Contacts:**  
**Tel.** 02.8376799 | **Fax.** 02.89424876  
[segreteria.sie@me.com](mailto:segreteria.sie@me.com)  
[info@endodonzia.it](mailto:info@endodonzia.it)  
**PEC:** [segreteria.sie@pec.segreteriasie.it](mailto:segreteria.sie@pec.segreteriasie.it)  
**Site:** [www.endodonzia.it](http://www.endodonzia.it)  
[www.giornaleitalianoendodonzia.it](http://www.giornaleitalianoendodonzia.it)

## EDITORIAL OFFICE

Gaia Garlaschè  
[editor.giornale@endodonzia.it](mailto:editor.giornale@endodonzia.it)

**Editorial Director**  
Filippo Cardinali

## PUBLISHING ARIESDUE

**Managing Director**  
Sergio Porro

**Publishing Support**  
Stefania Garancini  
[stefania.garancini@ariesdue.it](mailto:stefania.garancini@ariesdue.it)

**Giornale Italiano di Endodonzia** was founded in 1987 and is the official journal of the Italian Society of Endodontics (SIE). It is a peer-reviewed journal publishing original articles on clinical research and/or clinical methodology, case reports related to Endodontics. The Journal evaluates also contributes in restorative dentistry, dental traumatology, experimental pathophysiology, pharmacology and microbiology dealing with Endodontics. *Giornale Italiano di Endodonzia* is indexed in Scopus and Embase and published online on ScienceDirect and [www.giornaleitalianoendodonzia.it](http://www.giornaleitalianoendodonzia.it). *Giornale Italiano di Endodonzia* is an Open Access Journal.

Copyright © 2019 Società Italiana di Endodonzia.  
Production and hosting by Ariesdue. All rights reserved.

REGISTRATION Court of Milan n° 89, 3 March 2009

# Table OF CONTENTS

## Editorial/Editoriale

9 Sandro Rengo

## Mini Review Article/Mini Review della Letteratura

13 COVID-19 and dental practice: overview and protocols during pandemic  
*Roberto Careddu\*, Manuela Ciaschetti, Greg Creavin, Flvio Molina, Gianluca Plotino*

## Position Statement

20 Position Statement on Asepsis in Endodontics  
*Filippo Cardinali, Cristiano Fabiani, Massimo Giovarrusco, Alberto Rieppi (SIE members)*

## Case Series/Casi Clinici

### Winner of Giorgio Lavagnoli Award 36° SIE National Congress 2019

23 Treatment of obliterated root canals using various guided endodontic techniques: a case series  
*Antonietta Bordone\*, Cauris Cauvrechel*

## Case Report/Caso Clinico

35 Regenerative endodontic treatment options for immature permanent teeth: a case report with 21-month follow-up  
*Mariana Carvalho Furtado Leite, Claudio Maniglia Ferreira, Fabio de Almeida Gomes\*, Fernanda Geraldo Pappen, Tamara Kerber Tedesco, Ana Flávia Bissoto Calvo, José Carlos Pettorossi Imparato*

## Original Articles/Articoli Originali

### Winner of The Best Poster SIE Award 36° SIE National Congress 2019

41 Root canal morphology of lower lateral incisors: a CBCT in vivo study  
*Linda Quero\*, Giovanni Schianchi, Federico Valenti Obino, Massimo Galli, Luca Testarelli, Gianluca Gambarini*

### Winner of Riccardo Gerberoglio Award 36° SIE National Congress 2019

47 Antibacterial effects of two synthetic peptides against *Enterococcus faecalis* biofilms: a preliminary in vitro study  
*Giovanni Mergoni\*, Maddalena Manfredi, Pio Bertani, Tecla Ciociola, Stefania Conti, Laura Giovati*

### Winner of Francesco Riitano Award 36° SIE National Congress 2019

55 Evaluation of the root canal tridimensional filling with warm vertical condensation, carrier-based technique and single cone with bioceramic sealer: a micro-CT study  
*Edoardo Moccia\*, Giorgia Carpegna, Alessandro Dell'Acqua, Mario Alovisi, Allegra Comba, Damiano Pasqualini, Elio Berutti*

# Table OF CONTENTS

- 63 Diagnostic accuracy of two cone-beam computed tomography systems for detection of strip perforation in the mesial root of mandibular molars  
*Vida Maserat, Heshmatallah Shahraki Ebrahimi, Eshagh Ali Saberi\*, Arezoo Pirhaji*
- 69 Comparison of effectiveness of Reciproc, Wave One, Protaper, and One Shape rotary instruments in reduction of bacterial load in root canals  
*Ali Azizi, Reza Hatam, Parisa Soltani, Shimasadat Miri\*, Ramin Abiri*
- 75 Effect of composite thickness over the fiber post on fracture resistance of endodontically treated teeth  
*Kasra Rahimipour, Narges Panahandeh, Seyedeh Mahsa Sheikh-Al-Eslamian\*, Reza Mousavi, Hassan Torabzadeh*
- 82 Use of dynamic navigation for a minimal invasive finding of root canals: a technical note  
*Chiara Pirani, Andrea Spinelli, Claudio Marchetti, Maria Giovanna Gandolfi, Fausto Zamparini, Carlo Prati\*, Gerardo Pellegrino*
- 90 Sonic vs Ultrasonic activation of sodium hypochlorite for root canal treatments. In vitro assessment of debris removal from main and lateral canals.  
*Gianluca Gambarini, Gabriele Miccoli, Stefano Di Carlo, Giulia Iannarilli, Greta Lauria, Dario Di Nardo\*, Marco Seracchiani, Tatyana Khrenova, Maurizio Bossù, Luca Testarelli*
- 97 Accuracy, sensitivity and specificity of three imaging modalities in detection of separated intracanal instruments  
*Tarek Elsewify\*, Sara Alemam, Shaimaa Abuelsadat, Shehabeldin Saber*
- 104 Post removal techniques: a systematic review and meta-analysis  
*Lais Dornelles Bianchini, Bruna Muhlberg Vetromilla\*, Jovito Adiel Skupien, Carlos José Soares, Tatiana Pereira-Cenci*

## Lettera del Presidente


115 *Maria Teresa Sberna*

## Vita Societaria

124 Resoconto del 36° Congresso SIE Novembre 2019





**Sandro Rengo**  
 Editor-in-Chief  
 Giornale Italiano  
 di Endodonzia  
 E-mail address  
[editor.giornale@endodonzia.it](mailto:editor.giornale@endodonzia.it)

## Editorial Editoriale

**I**n the present issue we collected the most interesting and recent themes focused on the macro-topic of prevention and treatment of infections. The editorial choice is focused on the SIE (Italian Society of Endodontics) position statement about asepsis that suggests the main guidelines that should be adopted during the different phases of endodontic treatments, aiming at minimizing the risk of contamination of the root canal system.

The discussed topic is strongly influenced by the event that, dramatically, is affecting our private practice, social as well as relational life. Indeed, in the last months of 2019, the Severe acute respiratory syndrome (SARS-CoV2), better known as COVID-19, had been developed first in China then worldwide. This syndrome, characterized by a high infection and lack of resolved treatments, had been defined as “pandemic” on March 11th, 2020 by World Health Organization (WHO), becoming the second pandemic of this century.

This dramatic event has deeply influenced our professional field, critically changing our protocols in the management of patient-clinician and in the prevention of infections as well as cross-contaminations. Indeed, virus transmission is particularly devious: it basically takes place through interaction (i.e. inhalation, direct contact, or ingestion) between the host and the virus contained in the epithelium of the respiratory system and exposed mucosae, typically by flügge or other particles that possess persistence in the surrounding environment. Finally, the virus shows an unusual resistance even on surfaces not commonly involved in the viral survival, as hands, steel instruments, and also walls of the dental office. Moreover, clinicians involved in the dental practice may treat asymptomatic although COVID-19 positive patients, demonstrating how our category is one of the mostly exposed to COVID-19 infective risk.

National and International dental associations have tried to promptly provide univocal guidelines to correctly manage the patients and to preserve the dental practitioners from both direct and indirect infection.

According to this background, the present issue of GIE, as already done by other scientific Journals, publishes a highly significant and detailed paper concerning COVID-19 concern, aiming at suggesting recommendations in the field of prevention and control of SARS-CoV-2 infection within the dental office.

It should be also noticed that, although the current emergency, maximum attention to the microbial as well ergonomic control of operative area, use of Individual Protection Devices (DPI), sterilization of the instruments and guarantee of an aseptic flow work are daily adopted during the dental practice to significantly reduce the infective risk related to patients and to dental staff.

The right risk management, from both a clinical and microbiological point of view, belongs to the permanent practice of Evidence-Based Medicine that is based on the deep knowledge of therapeutic protocols and international guidelines.

Italian dentistry has always been internationally distinguished due to high quality and ability in a wide range of dental topics; unfortunately, our features, as well as those of Italian medical doctors, have usually been disregarded, unappreciated and mortified. Even in this pandemic outbreak, it may happen that few patients have unrealistic demands concerning the sureness of results and time. It is well known that during the sharing-knowledge phase the treatment protocol changes very fast, and the “today” gold-standard could not be valid for tomorrow. However, the dental practitioners are always involved in primary care and first assistance of the emergency and act to minimize the clinical as well as social risks.

In conclusion, I hope that, once this editorial is published, all of us may read it just remembering a passed crisis thanks to the efficacy of the infection prevention and the modern scientific research concerning pharmacology and biotechnology.

Peer review under responsibility of Società Italiana di Endodonzia.

[10.32067/GIE.2020.34.01.13](https://doi.org/10.32067/GIE.2020.34.01.13)

Società Italiana di Endodonzia. Production and hosting by Ariesdue. This is an open access article under the CC BY-NC-ND license (<http://creativecommons.org/licenses/by-nc-nd/4.0/>).

## Editorial Editoriale

**I**n questo numero abbiamo voluto creare un contenitore capace di raccogliere le più interessanti e attuali tematiche incentrate sul macro-tema della prevenzione e del trattamento delle infezioni.

La scelta editoriale è focalizzata indubbiamente sulla posizione della SIE (Società Italiana di Endodonzia) riguardo l'asepsi: nel Position Statement sono indicati i principali accorgimenti che l'operatore dovrebbe seguire durante le diverse fasi del trattamento endodontico, nell'ottica di minimizzare il rischio di contaminazione del sistema canalare.

La tematica di questo numero è fortemente influenzata dall'evento che, drammaticamente, sta toccando la nostra professione, e la nostra stessa vita sociale e relazionale.

Infatti, negli ultimi mesi del 2019 si è sviluppata e diffusa dapprima in Cina, e successivamente in molte altre parti del mondo, la sindrome respiratoria acuta grave (SARS-CoV2), nota anche come COVID-19. Questa sindrome, caratterizzata da un'alta contagiosità e da un'assenza di presidi terapeutici particolarmente risolutivi, è stata dichiarata "pandemia" in data 11 marzo 2020, divenendo la seconda pandemia di questo secolo, secondo l'Organizzazione Mondiale della Sanità (OMS).

Questo drammatico evento ha condizionato profondamente il nostro settore professionale, modificandone criticamente i protocolli nella gestione paziente-operatore e nella prevenzione delle infezioni e delle cross-contaminazioni.

La trasmissione del virus è particolarmente subdola: essa avviene principalmente attraverso l'interazione (tramite inalazione, ingestione o contatto diretto) tra il virus contenuto negli epiteli delle vie respiratorie alte e le mucose esposte, tipicamente attraverso flügge o altre particelle che mostrino persistenza nell'ambiente circostante. Infine, il virus mostra un'insolita resistenza anche su superfici tipicamente poco avvezze alla sopravvivenza di forme virali usualmente termolabili e cronolabili, come le mani, lo strumentario in acciaio e, addirittura, le pareti dello studio odontoiatrico.

Quindi, la nostra categoria inconsapevolmente può eseguire cure su pazienti infetti, ma non ancora diagnosticati per la patologia del COVID-19. Da questo si intuisce facilmente come i dentisti siano tra i professionisti maggiormente esposti al rischio infettivo da COVID-19. Le nostre associazioni di categoria nazionali e internazionali hanno cercato di fornire tempestivamente linee guida chiare e semplici per la gestione dei pazienti odontoiatrici, e per preservare i dentisti da qualsiasi rischio di contagio diretto e indiretto.

Fatta tale premessa, non potevamo esimerci dal proporre in questo numero del GIE, così come già accaduto per molte altre riviste scientifiche, la pubblicazione di un articolo molto significativo e dettagliato riguardante la problematica del COVID19, al fine di poter suggerire delle raccomandazioni nel campo della prevenzione e del controllo dell'infezione da SARS-CoV-2 all'interno dello studio odontoiatrico. È d'obbligo, tuttavia, sottolineare che alla base della nostra professione quotidiana, e indipendentemente dall'attuale periodo critico e di emergenza, vi è sempre stata la massima attenzione alla gestione microbiologica ed ergonomica dell'area operatoria, all'utilizzo dei dispositivi di protezione personale (DPI), alla sterilità delle attrezzature e alla gestione asettica del flusso di lavoro, al fine di ridurre il rischio infettivo relativo ai pazienti e al personale di studio.

La corretta gestione del rischio, sia da un punto di vista clinico sia da un profilo meramente infettivo e microbiologico, attiene alla costante pratica della *Evidence Based Medicine* che non può prescindere da una profonda conoscenza dei protocolli e delle linee-guida internazionali. L'odontoiatria italiana si è sempre distinta a livello internazionale per qualità e per capacità di saper essere leader su moltissimi settori delle scienze odontoiatriche: purtroppo, la qualità degli odontoiatri, come quella dei medici italiani, che pure oggi vengono decantati e sublimati come professionisti simili a forme chimeriche tra il "santo" e l'"eroe", viene spesso deprezzata, incompresa e umiliata.

Anche in questo outbreak pandemico si sono visti percorsi quantomeno "attenzionabili" in cui il paziente intraprende fantasiose e capziose richieste risarcitorie per la pretesa irrealistica di dover ottenere certezza di modi, tempi e risultati. Durante la fase di sharing-knowledge, si sa, i protocolli variano al giro di lancette di un orologio: ciò che oggi è gold-standard domani sarà desueto o forse inefficace. Quello che non cambia e non può cambiare è la abnegazione della nostra categoria, sempre in prima linea, sempre pronta per essere un "settore sentinella" capace di intercettare e, spesso, disinnescare situazioni ad alto rischio clinico e sociale: non vogliamo applausi né sentirci dire *bravi!*, ma almeno non toglieteci la serenità in un momento tanto destabilizzante.

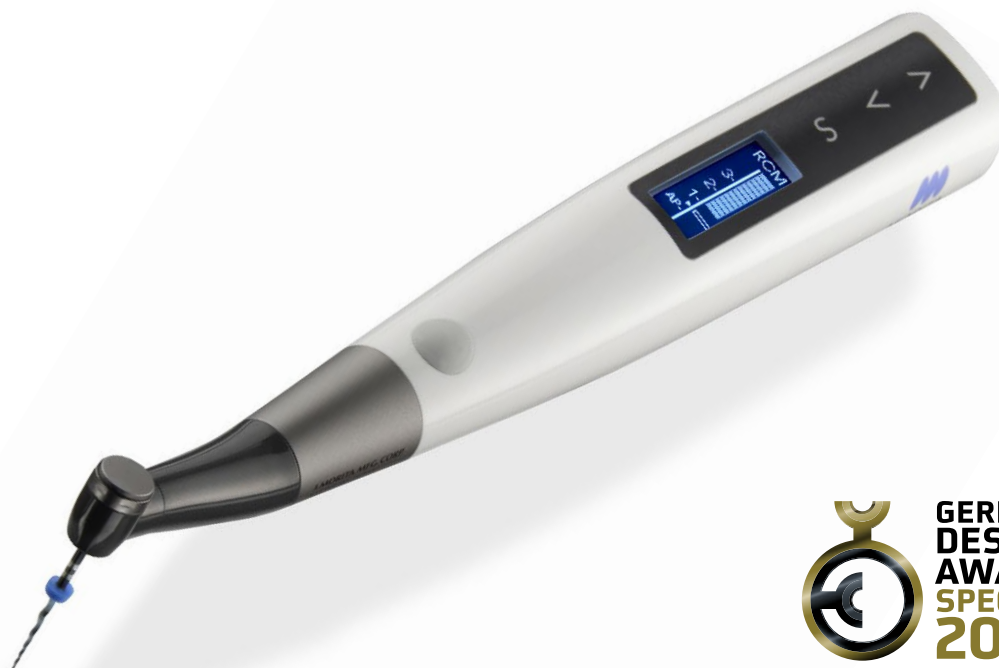In conclusione, auspico vivamente che allorquando questo editoriale sarà pubblicato, possiamo leggerlo ripensando a una crisi oramai passata e superata grazie a un efficace connubio tra una prevenzione attuata collegialmente e una ricerca farmacologica e biotecnologica innovativa.

Thinking ahead. Focused on life.

## Tri Auto ZX2: Semplice, geniale e assolutamente sicuro. Perfetto per qualsiasi canale radicolare.

Il nuovo Tri Auto ZX2 semplifica il trattamento canalare con la massima sicurezza – perfetto per tutti i tuoi pazienti.

Il manipolo con localizzatore apicale integrato è veramente sorprendente per la sua leggerezza: Senza cavo ed ergonomico si adatta perfettamente alla mano e garantisce massima libertà di movimento. Il trattamento è sicuro e facile grazie alle nuove funzioni di sicurezza, quali l' Optimum Glide Path (OGP) e l' Optimum Torque Reverse (OTR). L'OPG semplifica la realizzazione del glide path. L'OTR protegge dalla rottura del file e dalle microfratture invertendo automaticamente la direzione di rotazione quando viene superato il livello di torque. In questo modo, Tri Auto ZX2 preserva la sostanza del dente naturale e rende il trattamento ancora più efficiente. Per ulteriori informazioni, vedere [www.jmoritaitalia.com](http://www.jmoritaitalia.com)





EDGEENDO®

EDGEONE

FIRE™

File reciprocanti



When you want...

**PERFORMANCE,  
STRENGTH,  
FLEXIBILITY  
AND VALUE**

**FILE NITI TRATTATI TERMICAMENTE - TECNOLOGIA FIREWIRE™**

**La forza della tecnologia FireWire™**

Nuova tecnologia per la strumentazione rotante.

Rende il file più flessibile incrementandone la resistenza alla fatica.

Il trattamento FireWire™ elimina la memoria elastica preservando l'anatomia del canale e la dentina e permette allo strumento di seguire con precisione il percorso canale in modo semplice ed efficace.

I file EdgeEndo® garantiscono velocità e sicurezza nel trattamento endodontico.

Per ulteriori informazioni su EdgeEndo visita [www.edgeendo.com](http://www.edgeendo.com).

Made in the USA

 dental trey

Distributore esclusivo: Dental Trey srl Via Partisani, 3 - 47016 Fiumana - Predappio (FC), ITALIA  
T +39 0543 929111, F +39 0543 940659 - [www.dentaltrey.it](http://www.dentaltrey.it) - [commerciale@dentaltrey.it](mailto:commerciale@dentaltrey.it)



# COVID-19 and dental practice: overview and protocols during pandemic

COVID-19 e odontoiatria: generalità e protocolli durante la pandemia

## KEYWORDS

SARS-CoV-2, COVID-19, Dental Practice, Infection Control, Pandemic

## PAROLE CHIAVE

SARS-CoV-2, COVID-19, Odontoiatria, Controllo dell'infezione, Pandemia

**Roberto Careddu<sup>1\*</sup>**  
**Manuela Ciaschetti<sup>2</sup>**  
**Greg Creavin<sup>3</sup>**  
**Flavio Molina<sup>3</sup>**  
**Gianluca Plotino<sup>4</sup>**

<sup>1</sup>Division of Restorative Dentistry and Periodontology, Dublin Dental University Hospital, Lincoln Place, Dublin, Ireland

<sup>2</sup>Private Practice, Edinburgh, UK

<sup>3</sup>Private Practice, Dublin, Ireland

<sup>4</sup>Private Practice, Rome, Italy

Received 2020, March 28

Accepted 2020, April 2

## Abstract

In December 2019, in Wuhan (China), there were described the first cases of a Severe Acute Respiratory Syndrome caused by SARS-CoV-2 and named COVID-19. Since then the disease has spread in several countries and in March 2020 the WHO declared it pandemic.

COVID-19 is associated with a wide range of manifestations from no symptoms to temperature cough, dyspnea, need for artificial ventilation and eventually death. Mortality has been reported to be around 3%. Cases of spreading from asymptomatic infected individuals have been documented.

It has become clear that among healthcare professionals, dentists are the most exposed category to the risk of such infection as the routes of transmission are contact, droplets and aerosol, therefore the necessity of providing clear guidelines has suddenly arisen.

This article is aimed at analysing the available literature about "SARS-CoV-2" and "COVID-19", and comparing it with the guidelines for other coronavirus infections and dental practice with a view to providing clinical recommendations about prevention and infection control in the dental environment.

## Introduction

In December 2019, several cases of viral pneumonia were discovered in Wuhan, Hubei, China. A novel coronavirus was recognised as the pathogen responsible for the infection and named 2019 Novel Coronavirus

Nel dicembre 2019 sono stati descritti a Wuhan (Cina) i primi casi di Severe Acute Respiratory Syndrome causata dal virus SARS-CoV-2 e chiamata COVID-19. La patologia si è successivamente diffusa in diversi Stati fino a che nel marzo 2020 l'OMS ha dichiarato lo stato di pandemia. COVID-19 ha diverse possibili manifestazioni: può essere completamente asintomatica o presentarsi con febbre, tosse, dispnea e talvolta necessità di ventilazione assistita con rischio di morte. La mortalità si attesta attorno al 3%. Sono stati documentati casi di contagio avvenuto mediante portatori sani.

Dato che il virus si trasmette mediante contatto, droplet e aerosol, i dentisti risultano la categoria più a rischio di contrarre la malattia rispetto agli altri operatori sanitari. Per questo motivo delle linee guida sulla gestione della pratica odontoiatrica durante la pandemia sono quanto mai necessarie.

Lo scopo di questo articolo è di analizzare la letteratura disponibile riguardo "SARS-CoV-2" e "COVID-19", comparandola con le linee guida esistenti per gestire i coronavirus nell'ambiente odontoiatrico, al fine di poter dare delle raccomandazioni inerenti prevenzione e controllo dell'infezione da SARS-CoV-2 nello studio odontoiatrico.

(2019-nCoV), then changed in SARS-CoV-2 (1, 2). Since then the virus has spread in 177 countries.

On the 12th of February 2020, the World Health Organisation (WHO) named COVID-19 the disease caused by SARS-CoV-2 and in March 11th, declared it a pandemic (WHO Feb 2020; WHO Mar 2020).

## Corresponding author

Roberto Careddu | 37 North Strand Road D3, Dublin | Ireland  
drcareddu@hotmail.com

Peer review under responsibility of Società Italiana di Endodonzia

10.32067/GIE.2020.34.01.08

Società Italiana di Endodonzia. Production and hosting by Ariesdue. This is an open access article under the CC BY-NC-ND license (<http://creativecommons.org/licenses/by-nc-nd/4.0/>).

Healthcare professionals are exposed to this virus that can be spread through contact, droplets and airborne and indeed dentists are one of the most exposed category (Gamio 2020; Peng et al. 2020).

The aim of this article is to collect the available literature and provide guidelines based on literature and guidelines about SARS and MERS epidemic events and from the information so far available on SARS-CoV-2.

A comprehensive MEDLINE search up to 22th March 2020 was conducted using medical subject headings (MeSH) in combination with 'and' or 'or'. The MeSH terms searched were 'SARS-CoV-2', 'COVID-19', 'Dental' and 'Dental Practice'. In addition, the following terms were added, 'Dental Surgery', '2019 -nCoV'.

Because of the lack of scientific papers a comprehensive MEDLINE search up to 22th March 2020 using MeSH 'SARS-CoV-2', 'COVID-19', in combination with 'and' or 'or' was carried out. All the relevant papers regarding infection control and prevention were hand-searched in order to find all possible information that may apply to the dental field.

## Review

### *General features*

Coronavirus were isolated for the first time in 1966 from patients with common cold: they are a class of enveloped positive sense RNA viruses with diameter between 60 and 140 nm whose name come from the presence of spike-like projections that may resemble a crown (7, 8).

Coronaviruses are divided in four subfamilies a, b, g, d. SARS-CoV-2 belongs to the B lineage of the b-coronaviruses. It is most likely to have in bats its natural host and appears to have many similarities with the virus SARS-CoV (9, 10).

All ages and genders are potentially affected by COVID-19 even though males seem to be more susceptible to the infection. The range of symptoms goes from a completely asymptomatic state to Acute Respiratory Distress Syndrome (ARDS) and possible death (11). Common clinical features are quite not specific including

high temperature, cough, myalgia, dyspnea, sore throat and conjunctivitis but the virus can be carried by asymptomatic people that are able to infect others (Pan et al. 2020; Rodriguez-Morales; Rothe et al. 2020; Singhal 2020).

Individuals with underlying medical conditions are more susceptible to an unfavourable outcome. The risk of death of patients presenting comorbidities like cardiovascular disease, diabetes, chronic respiratory disease, cancer and COVID-19 is statistically higher (Coronavirus Outbreak 2020).

Intensive care is needed in 25-30% of the cases, with an average hospital stay of ten days. Fatality ranges between 2 and 3 % and it is more common in the elderly and people who suffer from co morbidities (15). Three routes of transmission have been found (table 1).

1) Contact transmission: when someone touches an infected object and subsequently touches his mouth, nose or eyes. 2) Droplets transmission: when the droplets generated by cough and sneezes are ingested or inhaled. 3) Airborne transmission: when droplets mix with the air creating aerosols that may cause infection if inhaled (11, 17). A feco-oral transmission is considered possible as well (18).

Human coronaviruses can stay active on certain surfaces from hours up to few days, but are inactivated within one minute after the disinfection with 0.1% sodium hypochlorite or 62-71% ethanol (19). On the other hand the virus has demonstrated to be viable in aerosols for at least 3 hours (20).

### **SARS-CoV-2 and dentistry**

#### *Possible transmission*

Due to the nature of SARS-Cov-2 and its routes of transmission, it is clear that dentists, dental staff and patients are at risk of infection when dental treatments are provided (6).

Contamination can happen directly between operators and patients due to droplets during pre-clinical assessment or discussion of the treatment plan but contamination of air and surfaces plays a strategic role in the diffusion of the virus.

**Table 1****Possible transmission of SARS-CoV2**

Transmission route	Method of transmission	References
Contact	Direct or Indirect contact with mucosae	Kampf 2020
Droplets	Droplets of infected saliva ejected with cough or sneezes	Peng 2020
Airborne	Mix of air and viruses that can be inhaled	Peng 2020
Feco-Oral	Possible transmission through digestive tract	Zhang 2020

It has been demonstrated that dental treatments and in particular dental hygiene procedures produce aerosol and splatters with presence of microorganisms, causing contamination of tools, equipment, gowns, surfaces and air (21, 22).

Contamination of surfaces is unavoidable when aerosol is produced and SARS-CoV-2 can resist several days on surfaces, putting the operators at risk of infection (19). Apparently the virus persists better at room's humidity 50% than 30% (6).

#### *Infection Control*

Standard precautions used in dental practices are able to prevent cross-infections originated by direct contacts with body fluids and contaminated surfaces. SARS-CoV-2 though, presenting three routes of transmission including the airborne needs to be dealt with Transmission-Based Precautions (17).

#### *Patient Screening*

During the outbreak of SARS-COVs it is not recommended to perform routine dental treatments as the risk of contributing to the spread of the virus is high. Dental care should be provided just for dental emergencies or urgent dental care (6).

Dental emergencies are considered potentially life threatening conditions such as uncontrolled bleeding, cellulitis with swelling that could compromise the airways, facial trauma with possible airways involvement. Hospital emergency departments are overloaded during a pandemic and urgent dental care service should be provided for those patients that otherwise would have to use hospital services. Severe dental pain and conditions like pericoronitis of third molars/surgical

post extractive osteitis should be considered urgent (23).

It is therefore important to perform a telephone triage in order to assess the risks and the severity of the condition. An interview over the phone is then necessary to prevent to bring infected patients into the surgery as much as possible.

The following questions should be asked (6, 24):

1. Have you experienced fever or symptoms like cough, shortness of breath or other respiratory problems in the past 14 days?
2. Have you been in contact with someone affected by COVID-19 in the past 14 days?
3. Have you been in contact with someone reporting fever or respiratory problems in the past 14 days?
4. Did you participate in gatherings, meetings or had contact with many unacquainted people in the past 14 days?
5. Did you travel from areas with Level 3 Travel Health Notice for COVID-19? (this question can be omitted when the virus is declared at community level)

If the patient answers *yes* to any of these questions the treatment should be postponed and the patient invited to contact his physician if the answer to questions number one or two is positive.

#### *Patient Management*

When emergency care must be provided, preventive measure should be taken in order to decrease the possible viral load (25). Chlorhexidine is often used in dental practice as an antiseptic, but this will not probably be effective against SARS-CoV2. The virus appears to be vulnerable to oxidation, thus a pre-operative rinse with

1% hydrogen peroxide should reduce the viral load in the oral cavity (6, 19, 23). Other than hydrogen peroxide, Povidone 0.2% has been recommended as rinse, as these two antiseptics have been demonstrated effective to reduce salivary viral load with low risk of causing secondary complications in the oral cavity (26).

*Personal Protective Equipment*

SARS-CoV-2 infection may occur through direct or indirect contact and aerosol, therefore when the outbreak is at community level Transmission-Based Precautions for contact, droplets and airborne must be taken for all patients. Standard surgical masks are effective against splashes and large-sized droplets but not effective against small airborne particles thus fit-tested N-95 respirators or superior ones are required, even more when aerosol-producing treatments are performed (28, 17, 29, 27).

Protective disposable impermeable gowns and caps are recommended as well as gloves and eye protection. These medical devices should be worn before coming in contact with the patient and discarded safely before leaving the room (28, 17). It is paramount that all the staff is adequately instructed on the use and doffing of Personal Protective Equipment (PPE) as deviation from standard procedures will increase the risk of infection (30).

*Air Supply*

Airborne Transmission Based Precautions treatments performing aerosol should be treated in Airborne Infection Isolation Room (AIIR) that is a single-patient room designed to maximise the infection control, equipped with special air handling and ventilation capacity compliant with AIIR standards (29). A COVID-19 positive or suspected patient should not be treated in a dental surgery

**Table 2**

**Dental Emergency and Urgent Dental Care (ADA 2020)**

	Description	Conditions
<b>Dental Emergency</b>	Potentially life threatening conditions that require immediate care	<ul style="list-style-type: none"> <li>• Uncontrolled bleeding</li> <li>• Diffuse bacterial infection with intra-oral or extra-oral swelling that potentially compromise the patient's airway</li> <li>• Trauma involving facial bones, potentially compromising the patient's airway</li> </ul>
<b>Urgent Dental Care</b>	Conditions that require immediate attention to relieve severe pain/infections and to avoid patients to seek for treatment in hospital emergency departments	<ul style="list-style-type: none"> <li>• Severe dental pain from pulpal inflammation</li> <li>• Pericoronitis or third-molar pain</li> <li>• Surgical post-operative osteitis, dry socket dressing changes</li> <li>• Abscess, or localized bacterial infection resulting in localized pain and swelling</li> <li>• Tooth fracture resulting in pain or causing soft tissue trauma</li> <li>• Dental trauma with avulsion/luxation</li> <li>• Dental treatment required prior to critical medical procedures</li> <li>• Final crown/bridge cementation if the temporary restoration is lost, broken or causing gingival irritation</li> <li>• Biopsy of abnormal tissue</li> </ul>



**Table 3****Recommended Precautions for SARS-CoV-2**

Transmission	PPE	Indications	Environment	Patient Management	References
<b>Contact</b>	<ul style="list-style-type: none"> <li>Gloves (Latex or Nitrile)</li> <li>Isolation Gowns</li> <li>Disposable cap</li> </ul>	Wear these PPE before any contact with the patient and dispose them safely at the room entrance. Doffing of gowns and gloves must be done following existing guidelines.	<ul style="list-style-type: none"> <li>Eliminate all unnecessary equipment from the room</li> <li>Be extremely careful in the disposal of contaminated equipment</li> </ul>	<ul style="list-style-type: none"> <li>Ask the patient to use hand sanitiser when arrives</li> <li>Ask the patient to wear a mask until his treatment</li> </ul>	6, 11, 12, 17, 29, 30, 31, 32, 33.
<b>Droplets</b>	<ul style="list-style-type: none"> <li>Goggles</li> <li>Face Shields</li> </ul>	<p>Goggles with antifog system have to be preferred.</p> <p>Face shields are more protective, especially if extended from chin to crown</p>	<ul style="list-style-type: none"> <li>Disposable covers help avoiding surface contamination</li> </ul>	<ul style="list-style-type: none"> <li>Ask the patient to follow respiratory hygiene and cough etiquette</li> <li>Use Rubber dam</li> </ul>	
<b>Airborne</b>	<ul style="list-style-type: none"> <li>N95 Respirators (FFP2)</li> </ul>	N95 Respirators are recommended to avoid airborne transmission. Face fitting is mandatory	<ul style="list-style-type: none"> <li>Avoid as much as possible to create aerosol</li> <li>Avoid the use of rotary handpieces and minimise the use of 3 in 1 syringe</li> <li>If available, patient should be treated in AIIR</li> </ul>	<ul style="list-style-type: none"> <li>Ask the patient to rinse his mouth with 1% hydrogen peroxide solution</li> </ul>	

that has not the above mentioned equipment as it would be impossible to use airborne precautions. Since infection from SARS-CoV-2 is proven to be possible from asymptomatic patients it is recommended not to treat patients unless it is a dental emergency and, even in case of asymptomatic patients, all PPE for airborne precaution should be used, all possible care has to be used to reduce the amount of aerosol produced and the single patient room has to have the door closed and adequate ventilation to dilute the infected air. Table 2 reports what is recognised as dental emergency and urgent dental care according to the American Dental Association (23). Recommended precautions are summarised in table 3. If the patient is symptomatic or at

high risk to be infected he should attend the practice and, if he does, be asked to wait in a closed room with a surgical mask covering nose and mouth, then the patient should be referred to the hospital or dealt with as regulated by the local health authority (17, 31).

#### *Disinfection*

Alcohol based or sodium hypochlorite based disinfectants are active against coronaviruses and they should be used to disinfect not only every component of the dental chair but the surfaces that can be in contact with aerosol spray as well. Removing from the room every not necessary equipment and covering all possible surfaces with disposable covers may help in improving the contact infection control.

## Conclusions

Sars-CoV-2 is a very infective virus that causes COVID-19, a disease with a very broad range of manifestations, from lack of symptoms to ARDS and eventually death. Because of the routes of transmission of this pathogen dentists are among the health professionals who are exposed to high risk of infection.

When the disease is at community level, it is paramount that dental care professionals protect themselves, their staff and patients, avoiding any risk of spreading the virus. It is important to remember that completely asymptomatic patients are carriers of the infection.

In this view it is mandatory to postpone any elective treatments and dentists should treat only emergencies or provide care for those whom, if not treated, would need hospital care (table 2). In any case risk assessment over the phone is important to avoid high risk patients to attend the surgery if this is not equipped for proper airborne infection control.

In the dental environment infection may occur because of direct or indirect con-

tacts with body fluids of an infected person or touching contaminated surfaces and then touching eyes or face. Droplets are a possible route of transmission as well as aerosol generated from dental treatments (table 1).

When treating a dental emergency during the outbreak of an airborne transmitted pathogen, Standard Precautions for infection control are not sufficient and Transmission Based Precautions must be applied.

Ideally treatments should be provided in AIIR when treating patients that have possibly come in contact with the virus. Because dental practices are not usually equipped with an AIIR, if an emergency arises it is important to use a single patient room with closed door, ensure adequate ventilation to the room, remove all unnecessary equipment and cover all surfaces that can be contaminated.

Because of the aerosol produced, operator and assistant must wear face fitting N95 respirators, goggles/face shields, isolation gowns, gloves and disposable caps. These PPE must be worn before any contact with the patient and dis-

## References

- Gorbalenya AE. Severe acute respiratory syndrome-related coronavirus – The species and its viruses, a statement of the Coronavirus Study Group. *BioRxiv*. 2020; Preprint doi: <https://doi.org/10.1101/2020.02.07.937862>.
- Huang C, Wang Y, Li X, et al. Clinical features of patients infected with 2019 novel coronavirus in Wuhan, China. *Lancet*. 2020;395:497-506.
- World Health Organization. WHO Director-General's remarks at the media briefing on 2019-nCoV on 11 February 2020. Available from <https://www.who.int/dg/speeches/detail/who-director-general-remarks-at-the-media-briefing-on-2019-ncov-on-11-february-2020>. Published 11th February 2020.
- World Health Organization. WHO Director-General's remarks at the media briefing on 2019-nCoV on 13 March 2020. Available from <https://www.who.int/dg/speeches/detail/who-director-general-opening-remarks-at-the-mission-briefing-on-covid-19-13-march-2020>. Published 13th March 2020.
- Gamio L. Workers Who Face the Greatest Coronavirus Risk. *The New York Times*. 2020.
- Peng X, Xu X, Li Y, et al. Transmission routes of 2019-nCoV and controls in dental practice. *Int J Oral Sci*. 2020;12:1.6.
- Tyrrell DA, Bynoe LM. Cultivation of viruses from a high proportion of patients with colds. *Lancet*. 1966;1:76-7.
- Richman DD, Whitley RJ HF. *Clinical Virology*. 4th ed. Washington: ASM Press, 2016.
- Zhou P, Yang X-L, Wang X-G, et al. A pneumonia outbreak associated with a new coronavirus of probable bat origin. *Nature*. 2020; 579:270-73.
- Velavan TP, Meyer CG. The COVID-19 epidemic. *Trop Med Int Heal*. 2020;25:278-80.
- Adhikari SP, Meng S, Wu Y, et al. A literature review of 2019 Novel Coronavirus during the early outbreak period: Epidemiology, causes, clinical manifestation and diagnosis, prevention and control. *Infect Dis Poverty* 2020;9:29.
- Pan X, Chen D, Xia Y, et al. Asymptomatic cases in a family cluster with SARS-CoV-2 infection. *Lancet Infect Dis*. 2020; Epub ahead of print. doi: [http://dx.doi.org/10.1016/S1473-3099\(20\)30114-6](http://dx.doi.org/10.1016/S1473-3099(20)30114-6).
- Rodríguez-Morales AJ, Cardona-Ospina JA, Gutiérrez-Ocampo Estefanía, et al. Clinical, laboratory and imaging features of COVID-19: A systematic review and meta-analysis. *Travel Med Infect Dis*. 2020; Epub ahead of print. doi: 10.1016/j.tmaid.2020.101623.
- Rothe C, Schunk M, Sothmann P, et al. Transmission of 2019-nCoV Infection from an Asymptomatic Contact in Germany. *N Engl J Med*. 2020; 382:970-71.
- Singhal T. A Review of coronavirus disease-2019 (COVID-19). *Indian J Pediatr*. 2020; 87:281-86.
- Phua K, Yeo J, Tan S et al. Coronavirus outbreak. 2020. *Asia Pacific Biotech News Suppl* 1.
- Harte JA. Standard and transmission-based precautions: An update for dentistry. *J Am Dent Assoc*. 2010;141:572-81.



posed safely before leaving the room. It is important that dental staff is correctly instructed on the correct use and disposal of protective equipment as incorrect doffing has been linked with increased risk of infection.

Patients should be requested to disinfect their hands on the arrival with an alcohol based hand sanitiser, to follow respiratory hygiene and cough etiquette and to wear a surgical mask until the treatment commences. A rinse with 1% hydrogen peroxide may be helpful to reduce the amount of SARS-CoV-2 in the saliva.

Dental aerosol should be avoided: use of ultrasonic scaler or high speed handpieces is not recommended and the use of the 3 in 1 syringe should be reduced. Rubber dam must be used when possible and should cover mouth and nose.

Dental surgery decontamination has to be carefully performed. The virus is rapidly inactivated by disinfectant containing 0.1% sodium hypochlorite or 62-71% ethanol. Because of the aerosols the room has to be adequately ventilated to reduce the amount of virus present in the air.

SARS-CoV-2 is a challenge for healthcare professionals. During the outbreak of the disease only emergency treatments are recommended and special precautions and PPE must be used when providing dental care. Training and correct information about prevention and control of airborne infections should be provided to healthcare workers.

### Clinical Relevance

COVID-19 is a major concern for public health and dentists are among the healthcare professionals facing the greatest risks of infection.

This article provides an overview on the disease and its routes of transmissions and gives indications for prevention and infection control in the dental environment.

### Conflict of Interest

The Authors deny any conflict of interest.

### Acknowledgements

No acknowledgements are needed.

18. Zhang H, Kang Z, Gong H, et al. The digestive system is a potential route of 2019-nCoV infection: a bioinformatics analysis based on single-cell transcriptomes. *BioRxiv*. 2020; Epub ahead of print. doi: <https://doi.org/10.1101/2020.01.30.927806>.
19. Kampf G, Todt D, Pfaender S, Steinmann E. Persistence of coronaviruses on inanimate surfaces and their inactivation with biocidal agents. *J Hosp Infect*. 2020; 104:246-51.
20. van Doremalen N, Bushmaker T, Morris DH, et al. Aerosol and surface stability of SARS-CoV-2 as compared with SARS-CoV-1. *N Engl J Med*. 2020; Epub ahead of print. doi: 10.1056/NEJMc2004973.
21. Watanabe A, Tamaki N, Yokota K, et al. Use of ATP bioluminescence to survey the spread of aerosol and splatter during dental treatments. *J Hosp Infect*. 2018;99:303-5.
22. Szymańska J. Dental bioaerosol as an occupational hazard in a dentist's workplace. *Ann Agric Environ Med*. 2007;14(2):203-7.
23. ADA. What Constitutes a Dental Emergency? 2020. Available from: [https://success.ada.org/~media/CPS/Files/OpenFiles/ADA\\_COVID19\\_Dental\\_Emergency\\_DDS.pdf?utm\\_source=adaorg&utm\\_medium=covid-resources-lp&utm\\_content=cv-pm-emerg-def&utm\\_campaign=covid-19&\\_ga=2.252249162.2105371876.1584981961-1354013729.584981960](https://success.ada.org/~/media/CPS/Files/OpenFiles/ADA_COVID19_Dental_Emergency_DDS.pdf?utm_source=adaorg&utm_medium=covid-resources-lp&utm_content=cv-pm-emerg-def&utm_campaign=covid-19&_ga=2.252249162.2105371876.1584981961-1354013729.584981960).
24. California Dental Association. COVID-19 screening procedure flowchart. 2020. Available from [https://www.cda.org/Portals/0/pdfs/COVID-19\\_Pdfs/cda-covid19-pt-screening-flowchart.pdf](https://www.cda.org/Portals/0/pdfs/COVID-19_Pdfs/cda-covid19-pt-screening-flowchart.pdf).
25. Meng L, Hua F, Bian Z. Coronavirus disease 2019 (COVID-19): emerging and future challenges for dental and oral medicine. *J Dent Res*. 2020; Epub ahead of print. doi: 10.1177/0022034520914246.
26. Araya SC. Considerations for Urgent Care Dental and Preventive Measures for COVID-19. *Int. J. Odontostomat*. 2020;14 268-70.
27. Wang X, Pan Z, Cheng Z. Association between 2019-nCoV transmission and N95 respirator use. *J Hosp Infect*. 2020; Epub ahead of print. doi: 10.1016/j.jhin.2020.02.021.
28. Guideline Quick View: Transmission-Based Precautions. *AORN J*. 2019;109(4):529-36.
29. Siegel JD, Rhinehart E, Jackson M, Chiarello L. Guideline for Isolation Precautions: Preventing Transmission of Infectious Agents in Health Care Settings. *Am J Infect Control*. 2007;35(10 suppl. 2).
30. Phan LT, Maita D, Mortiz DC, et al. Personal protective equipment doffing practices of healthcare workers. *J Occup Environ Hyg*. 2019;16:575-81.
31. Li RWK, Leung KW, Sun FCS, Samaranyake LP. Severe Acute Respiratory Syndrome (SARS) and the GDP. Part II: Implications for GDPs. *Br Dent J*. 2004;197(3):130.
32. Kantor J. Behavioral considerations and impact on personal protective equipment (PPE) use: Early lessons from the coronavirus (COVID-19) outbreak. *J Am Acad Dermatol*. Epub ahead of print. doi: 10.1016/j.jaad.2020.03.013.
33. Spagnuolo G, De Vito D, Rengo S, Tatullo M. An overview on dentistry. *Int. J. Environ. Res. Public Health*. 2020;17(6):2094.

# Position Statement on Asepsis in Endodontics

## Position Statement: l'Asepsi in Endodonzia

The purpose of Italian Society of Endodontics (SIE) is to promote and show excellence in endodontic knowledge, and to help all members to improve their endodontic treatment for the benefit of patient safety and increase the success of their treatment.

Endodontic success depends on many factors, the most important of which is prevention and management of problems that could lead to unfavourable results during orthograde endodontic treatment.

Asepsis is one of the most important factors faced during endodontic treatment: the operator needs to follow some precautions to minimize the risk of infection (or reinfection) of the root canal system.

SIE suggests the procedures that the operator should follow during the endodontic treatment to minimize risks of contamination of the root canal system.

These suggestions are made on the base of scientific evidence that show how endodontic failures are caused by microorganisms from the oral cavity.

### Preparing the Operative Field

- To eliminate or decrease the bacterial concentration, the patient should rinse the mouth with clorexidine 0.2% for 1 minute. Calculus and plaque present on the tooth should be removed with a scaler or an ultrasonic device.
- All the instruments and tools should be sterile and should be discarded in case of contamination. The gloves should be also be changed if contaminated by touching non sterile objects or surfaces.

### Access Cavity and Endodontic Treatment

- The access to the endodontic cavity should be performed after isolating the tooth with rubber dam. All the carious tissues should be removed completely.
- After removing the carious tissues it is recommended to disinfect the tooth and the operative field with sodium hypochlorite 5%, Ethanol 80% for 2 minutes.
- Single use gloves and aspirator tips should be changed before accessing the endodontic space.
- The tip of any Endodontic files (hand or rotary) should not come into contact with any surface potentially contaminated by external bacteria (Gloves or Rubber Dam).

### Root Canal Obturation

- Root canals should be dried using sterile paper points.
- Gutta percha used for obturation of root canal system should be disinfected (leaving it in sodium hypochlorite 5% for at least 1 minute).
- Spatula, flat plastic and any mixing pad should be sterile.

#### Authors

Filippo Cardinali, Cristiano Fabiani,  
Massimo Giovarruscio,  
Alberto Rieppi (SIE members)

#### Coordinator

Domenico Ricucci

DOI 10.32067/GIE.2020.34.01.04

**L**a Società Italiana di Endodonzia (SIE) ha lo scopo di promuovere e divulgare conoscenze endodontiche che tendono all'eccellenza e che permettano ai soci di innalzare il livello qualitativo delle cure endodontiche nell'interesse della salute del paziente.

Il successo della terapia endodontica dipende da molti fattori e dalla prevenzione e gestione di situazioni che possano influire negativamente sull'outcome del trattamento endodontico ortograde. Tra queste è sicuramente importante il problema relativo all'asepsi, cioè agli accorgimenti che l'operatore dovrebbe seguire per minimizzare il rischio di contaminazione del sistema canalare durante il trattamento endodontico ortograde.

Sulla base di un'evidenza scientifica sul ruolo dei microorganismi nei fallimenti endodontici e sulla presenza di batteri provenienti dal cavo orale all'interno del sistema canalare nei casi di fallimento dei trattamenti canalari ortogradi, la Società Italiana di Endodonzia indica delle norme procedurali che l'operatore dovrebbe seguire durante le diverse fasi del trattamento nell'ottica di minimizzare il rischio di contaminazione del sistema canalare durante il trattamento endodontico ortograde.

#### Preparazione al trattamento

- Nell'ottica di ridurre il numero globale di batteri prima della procedura clinica è consigliato uno sciacquo con clorexidina allo 0,2% per un minuto ed è consigliata la rimozione di placca/tartaro dalla superficie dell'elemento che deve essere trattato.
- Tutto lo strumentario utilizzato deve essere sterile e dovrebbe essere sostituito in caso di contaminazione, così come i guanti devono essere cambiati ogni qualvolta tocchino oggetti e superfici fuori dal tray con gli strumenti sterili.



## Coronal Seal

To prevent reinfection of the root canal system, after endodontic the filling it is strongly recommended to seal the orifice using adhesive restorative materials or glass ionomer cements.

### What a Position Statement is

The Position Statement is a guide to help all members of the SIE to better understand their role in dealing with problems that could arise during endodontic treatment in daily practice.

The position statement is produced by Expert members which study clinical problems and review the international scientific literature in order to reach their conclusion. The Position Statement is a view of the Society and can be discussed, modified and revised at any point. These statements are not guidelines in the strict sense but only recommendations, to help those clinicians who want to improve their clinical results and follow some protocols suggested by the Italian Endodontic Society.

### Cos'è un Position Statement

*Il Position Statement è una nota informativa che viene data ai soci sulla considerazione e posizione, appunto, che la Società ha relativamente a una problematica che i soci si possono trovare ad affrontare durante la pratica clinica quotidiana (oppure relativamente a una problematica di interesse endodontico.)*

*Sebbene sia frutto di un lavoro di soci esperti che analizzano il problema sia dal punto di vista clinico sia dal punto di vista scientifico previa analisi della letteratura scientifica internazionale, il Position Statement rimane comunque un punto di vista della Società e come tale è discutibile, opinabile e modificabile alla luce di future acquisizioni scientifiche relative all'argomento di cui è oggetto, e comunque non ambisce a essere una linea guida nel senso stretto del termine, né tantomeno una raccomandazione clinica e come tale non può essere utilizzata; il Position Statement è uno strumento informativo che aiuta il professionista che voglia seguire dei percorsi decisionali e degli approcci terapeutici condivisi dalla Società Italiana di Endodonzia, percorsi sostenibili sia clinicamente che scientificamente.*

### Accesso e trattamento dello spazio endodontico

- L'accesso allo spazio endodontico deve essere eseguito solo dopo aver isolato correttamente il dente con la diga di gomma e aver rimosso il tessuto carioso.
- Una volta eliminato tutto il tessuto carioso è consigliabile disinfettare il campo operatorio con una soluzione disinfettante (ipoclorito di sodio 5%, etanolo 80% per 2 minuti).
- Guanti monouso e cannula aspiratrice dovrebbero essere cambiati prima di accedere allo spazio endodontico.
- La parte lavorante degli strumenti canalari non deve mai entrare in contatto con superfici potenzialmente contaminate con batteri esterni come guanti o diga di gomma.

### Otturazione del canale

- Il canale deve essere asciugato mediante l'utilizzo di coni di carta sterili.
- La guttaperca utilizzata per la chiusura canalare deve essere disinfettata (bagno con ipoclorito di sodio al 5% per un minuto).
- Spatola e vetro per la miscelazione del cemento devono essere sterili.

### Sigillo coronale

- Per prevenire la reinfezione dello spazio endodontico dopo l'otturazione è fortemente consigliato il sigillo degli orifizi coronali utilizzando materiali da restauro su base adesiva o cementi vetroionomerici.

### KEYWORDS

Orthograde Endodontic Treatment, Contamination Of The Root Canal System, Asepsis, Procedures, Root Canal Obturation, Coronal Seal.

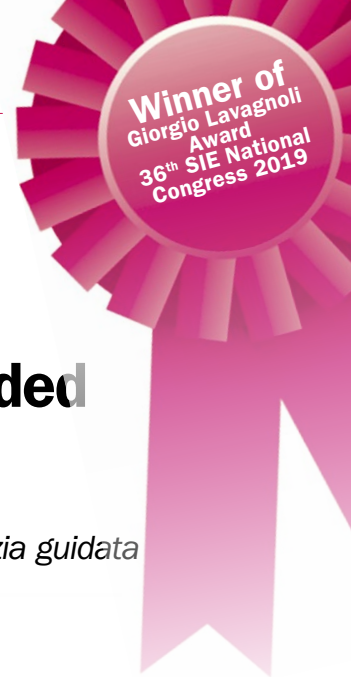### PAROLE CHIAVE

Outcome trattamento endodontico ortograde, contaminazione del sistema canalare, asepsi, norme procedurali, otturazione del canale, sigillo coronale.



## References

1. Azim AA, Griggs JA, Huang GT. The Tennessee study: Factors affecting treatment outcome and healing time following nonsurgical root canal treatment. *Int Endod J* 2016; 49:6-16.
2. Buckley M, Spångberg LS. The prevalence and technical quality of endodontic treatment in an American subpopulation. *Oral Surg Oral Med Oral Pathol Oral Radiol Endod* 1995;79:92-100.
3. Byström A, Happonen RP, Sjögren U, Sundqvist G. Healing of periapical lesions of pulpless teeth after endodontic treatment with controlled asepsis. *Endod Dent Traumatol* 1987;3:58-63.
4. Cotti E, Mercurio G. Apical periodontitis and cardiovascular diseases: previous findings and ongoing research. *Int Endod J* 2015;48:926-932.
5. Chan HW, Tan KH, Dashper SG, Reynolds EC, Parashos P. Sterilization of rotary NiTi instruments within endodontic sponges. *Int Endod J* 2015; doi: 10.1111/iej.1252, epub ahead of print.
6. DePaola LG, Minah GE, Overholser CD, Meiller TF, Charles CH, Harper DS, McAlary M. Effect of an antiseptic mouthrinse on salivary microbiota. *Am J Dent* 1996;9:93-5.
7. European Society of Endodontology. Quality guidelines for endodontic treatment: consensus report of the European Society of Endodontology. *Int Endod J* 2006; 39:921-930.
8. Goldfein J, Speirs C, Finkelman M, Amato R. Rubber dam use during post placement influences the success of root canal-treated teeth. *J Endod* 2013;39:1481-4.
9. Gomes BPF de A, Vianna ME, Matsumoto CU, Rossi V de PES, Zaia AA, Ferraz CCR, et al. Disinfection of gutta-percha cones with chlorhexidine and sodium hypochlorite. *Oral Surgery, Oral Medicine, Oral Pathology, Oral Radiology, and Endodontics*. 2005;100:512-7.
10. Fine DH, Yip J, Furgang D, Barnett ML, Olshan AM, Vincent J. Reducing bacteria in dental aerosols: preprocedural use of an antiseptic mouthrinse. *J Am Dent Assoc* 1993;124:56-8.
11. Friedman S, Abitdol S, Lawrence HP. Treatment outcome in Endodontics: The Toronto study. Phase 1: Initial treatment. *J Endod* 2003; 29:787-93.
12. Kvist T, Van der Sluis L. Report of the first ESE research meeting - 17th October 2014, Amsterdam, the Netherlands - The relationship between endodontic infections and their treatment with systemic diseases. *Int Endod J* 2015;48:913-915.
13. Langeland K. Management of the inflamed pulp associated with deep carious lesion. *J Endod* 1981;7:169-181.
14. Logothetis DD, Martinez-Welles JM. Reducing bacterial aerosol contamination with a chlorhexidine gluconate pre-rinse. *J Am Dent Assoc* 1995;126:1634-9.
15. Möller AJR. Microbial examination of root canals and periapical tissues of human teeth. *Odontol Tidskr* 1966; 74(Suppl):1-380.
16. Molven O, Halse A, Fristad I, MacDonalds-Jancowsky D. Periapical changes following root-canal treatment observed 20-27 years postoperatively. *Int Endod J* 2002; 35:784-90.
17. Molven O, Halse A. Success rates for gutta-percha and Kloroperka NØ root fillings made by undergraduate students: radiographic findings after 10-17 years. *Int Endod J* 1988; 21:243-50.
18. Nair PN, Sjögren U, Krey G, Kahnberg KE, Sundqvist G. Intraradicular bacteria and fungi in root-filled, asymptomatic human teeth with therapy-resistant periapical lesions: a long-term light and electron microscopic follow-up study. *J Endod* 1990;16:580-8.
19. Nair PNR. On the causes of persistent apical periodontitis: a review. *Int Endod J* 2006;39:249-81.
20. Niazi SA, Clarke D, Do T, Gilbert SC, Mannocci F, Beighton D. *Propionibacterium acnes* and *Staphylococcus epidermidis* isolated from refractory endodontic lesions are opportunistic pathogens. *J Clin Microbiol* 2010; 48:3859-69.
21. Ödesjö B, Helldén L, Salonen L, Langeland K. Prevalence of previous endodontic treatment, technical standard and occurrence of periapical lesions in a randomly selected adult, general population. *Endod Dent Traumatol* 1990;6:265-272.
22. Olsen RJ, Lynch P, Coyle MB, Cummings J, Bokete T, Stamm WE. Examination gloves as barriers to hand contamination in clinical practice. *JAMA* 1993;270:350-3.
23. Pang N-S, Jung I-Y, Bae K-S, Baek S-H, Lee W-C, Kum K-Y. Effects of short-term chemical disinfection of gutta-percha cones: identification of affected microbes and alterations in surface texture and physical properties. *Journal of Endodontics* 2007;33:594-8
24. Peters LB, van Winkelhoff AJ, Buijs JF, Wesselink PR. Effects of instrumentation, irrigation and dressing with calcium hydroxide on infection in pulpless teeth with periapical bone lesions. *Int Endod J* 2002;35:13-21.
25. Po-Yen L, Shi-Hao H, Hong-Ji C, Lin-Yang C. The effect of rubber dam usage on the survival rate of teeth receiving initial root canal treatment: a national population based study. *J Endod* 2014;40:1733-7.
26. Prado M, Gusman H, Gomes BPF, Simão RA. The importance of final rinse after disinfection of gutta-percha and Resilon cones. *Oral Surgery, Oral Medicine, Oral Pathology, Oral Radiology, and Endodontics* 2011;111:e21-4.
27. Ricucci D, Russo J, Rutberg M, Burleson JA, Spångberg LSW. A prospective outcome study of endodontic treatments of 1,369 root canals: results after 5 years. *Oral Surg Oral Med Oral Pathol Oral Radiol Endod* 2011; 112:825-42.
28. Ricucci D, Siqueira JF Jr, Bate AL, Pitt Ford TR. Histologic investigation of root canal-treated teeth with apical periodontitis: a retrospective study from 24 patients. *J Endod* 2009; 35:493-502.
29. Ricucci D, Siqueira JF Jr. *Endodontology. An integrated biological and clinical view*. Quintessence International, Berlin, 2013.
30. Rôças IN, Siqueira JF Jr. In vivo antimicrobial effects of endodontic treatment procedures as assessed by molecular microbiologic techniques *J Endod* 2011;37:304-10.
31. Segura-Egea JJ et al. You have full text access to this content. *Endodontic medicine: connections between apical periodontitis and systemic diseases*. *Int Endod J* 2015;48:933-951.
32. Siqueira JF Jr, Rôças IN, Alves FR, Campos LC. Periradicular status related to the quality of coronal restorations and root canal fillings in a Brazilian population. *Oral Surg Oral Med Oral Pathol Oral Radiol Endod* 2005;100:369-374.
33. Siqueira JF Jr. Aetiology of root canal treatment failure: why well-treated teeth can fail. *Int Endod J* 2001;34:1-10.
34. Siqueira JF Jr. *Treatment of endodontic infections*. London: Quintessence Publishing, 2011.
35. Sivakumar JS, Suresh Kumar BN, Shyamala PV. Role of provisional restorations in endodontic therapy. *J Pharm Bioallied Sci*. 2013 Jun; 5(Suppl 1): S120-S124.
36. Sjögren U, Figdor D, Persson S, Sundqvist G. Influence of infection at the time of root filling on the outcome of endodontic treatment of teeth with apical periodontitis. *Int Endod J* 1997; 30:297-306.
37. Sjögren U, Hägglund B, Sundqvist G, Wing K. Factors affecting the long term results of endodontic treatment. *J Endod* 1990; 16:498-504.
38. Sjögren U. *Success and failure in endodontics (Odontological Dissertation no.60)*. Umea, Sweden: University of Umea; 1996.
39. Tavares PB, Bonte E, Boukpepsi T, Siqueira JF Jr, Lasfargues JJ. Prevalence of apical periodontitis in root canal-treated teeth from an urban French population: influence of the quality of root canal fillings and coronal restorations. *J Endod* 2009;35:810-813.
40. *The Dental Cosmos; a monthly record of dental science*. Little things. 1864; Vol. VI: 13.
41. Weiger R, Hitzler S, Hermle G, Löst C. Periapical status, quality of root canal fillings and estimated endodontic treatment needs in an urban German population. *Endod Dent Traumatol* 1997;13:69-74.



## CASE SERIES/CASI CLINICI

# Treatment of obliterated root canals using various guided endodontic techniques

*Trattamento di canali obliterati con tecnica di endodonzia guidata*

**KEYWORDS**

Endodontic access, Guided endodontics, Minimally-invasive, Calcified canal, CBCT, Intraoral scanning

**PAROLE CHIAVE**

Cavità di accesso, Endodonzia guidata, Minima-invasività, Canali calcificati, CBCT, impronta digitale

**Abstract**

**Objective:** This article reports on four endodontic treatments of obliterated teeth using a static guided endodontic (GE) technique. The aim is to demonstrate the benefits and limits of static guided endodontics.

**Cases:** The four patients were referred for endodontic treatment of an obliterated tooth. The teeth did not respond to pulp vitality test. Periapical X-rays and cone-beam computed tomography (CBCT) revealed the presence of a periapical lesion and root canal obliteration. Patients' consent was obtained to perform GE orthograde treatment. The clinical cases were treated by GE using different static fixed guides depending on the case: a closed guide and a metal sleeve and an open guide with a system guiding the head of the contra-angle.

Treatment planning and guide manufacture were achieved by means of software programs initially designed for implantology, but which can also be used by endodontists. Root canal patency was obtained in all patients. In each of the four cases, drilling was done using a small diameter (0.75 mm) cylindrical drill (FFDM Pneumat Tivoly; Bourges; France). Once canal patency was obtained using a manual file, classic endodontic treatment could be performed.

**Conclusions:** Static GE assists endodontists in the management of complex cases by enabling centered drilling of the canal with minimum risk of deviating from the virtually planned path. The novel choice of a small-diameter drill (0.75 mm) helps maximize the preservation of the dental tissues.

**Obiettivo:** questo articolo riporta quattro trattamenti endodontici di denti obliterati con una tecnica di endodonzia guidata (EG) statica. L'obiettivo è di mettere in evidenza l'interesse e i limiti dell'endodonzia guidata statica.

**Casi:** i quattro pazienti si sono presentati in appuntamento per il trattamento endodontico di un dente obliterato. I denti non rispondevano ai test di vitalità. Le radiografie periapicali e la CBCT mostrano la presenza di una lesione periapicale e di un'obliterazione canalare. Con l'accordo dei pazienti, è stato deciso di realizzare un trattamento endodontico ortograde con EG. Questi casi sono stati trattati con EG con diversi tipi di dime statiche: una dima "chiusa" e una boccia metallica, una dima "chiusa" senza boccia metallica, una dima "aperta", utilizzando un sistema che guida la testa del contrangolo.

Le pianificazioni e la creazione delle dime sono state realizzate con dei programmi inizialmente dedicati all'implantologia ma che sono trasferibili all'endodonzia. La pervietà canalare è stata ritrovata in ciascuno dei casi. In ognuno dei casi l'apertura è stata realizzata con una fresa cilindrica di piccolo diametro (0.75 mm) (FFDM Pneumat Tivoly; Bourges; France). Una volta ritrovata la percorribilità del canale con una lima manuale, il trattamento endodontico è stato eseguito in maniera classica.

**Conclusione:** l'EG aiuta l'endodontista nella gestione dei casi complessi. Permette una apertura centrata sul canale con minimo rischio di deviazione significativa della traiettoria rispetto al progetto virtuale. La scelta di una fresa di piccolo diametro (0.75 mm) è innovativa in termini di conservazione dei tessuti dentali.

**Antonietta Bordone<sup>1\*</sup>  
Cauris Couvrechel<sup>2</sup>**

<sup>1</sup>Dental surgeon in private practice, Marseille, France

<sup>2</sup>Dental surgeon in private practice, Paris, France

Received 2020, February 13

Accepted 2020, March 3

**Corresponding author**

Antonietta Bordone | 3, bd Onfroy, 13008 Marseille, France  
dr.antonietta.bordone@gmail.com

Peer review under responsibility of Società Italiana di Endodonzia

10.32067/GIE.2020.34.01.06

Società Italiana di Endodonzia. Production and hosting by Ariesdue. This is an open access article under the CC BY-NC-ND license (<http://creativecommons.org/licenses/by-nc-nd/4.0/>).

## Introduction

The process of canal obliteration (CO) is characterized by the apposition of secondary or tertiary dentin, resulting in loss of volume in the pulpal space.

CO can result from various causes (1):

- Pathological: trauma, decays, iatrogenic factors (bulky restorations or orthodontic movements) or occlusal overload.
- Physiological: age-related.

According to the study by Holcomb and Gregory, 4% of the population is affected by CO (2). In the event of trauma, the incidence reaches 22% (3). Root canal obliteration is considered to be a defence mechanism of the pulp, the vitality of which is often preserved. Esthetically, this usually leads to yellowish discoloration, which can be treated by external whitening and/or by placing a veneer (4). Endodontic treatment is only indicated when the canal obliteration is associated with radiological signs revealing a periapical lesion or clinical signs of irreversible pulpitis. This clinical situation poses a challenge for the practitioner. Even using a microscope, the risk of intra-operative error is very high (5).

Traditional cavity access has a design that has been the standard for a long time (6). Recently, Clark and Khademi introduced a novel access cavity model which highlights preservation of dental structures (7, 8). A new approach to access cavity preparation was described for the first time in 2013 by Kfir et al. for the treatment of a type 3 dens invaginatus using an endodontic guide (9). For this purpose, they segmented the dental structure by means of CBCT to achieve a resin 3D model of the tooth. The model served to plan and manufacture a resin guide. As a result, a drill could be guided towards the invagination to be treated while preserving pulpal vitality of the tooth. Byun et al. (10) reproduced this technique to treat two teeth with complex endodontic anatomies. Shortly afterwards, Van der Meer

et al. (11) suggested a digital planning protocol for endodontic use inspired by implantology protocols. They merged a DICOM file obtained by CBCT with a Standard Tessellation Language (STL) file obtained from an intraoral optical impression. They calculated the drilling axis with the aid of an implant planning software and created a virtual guide. The virtual guide was then downloaded as an STL file to print a resin guide by means of a 3D printer. The guide enabled the drill to be centred towards the canal of an obliterated tooth. Such planning of the access cavity made it possible to preserve the dental structure and avoid deviations that may jeopardize tooth prognosis (12).

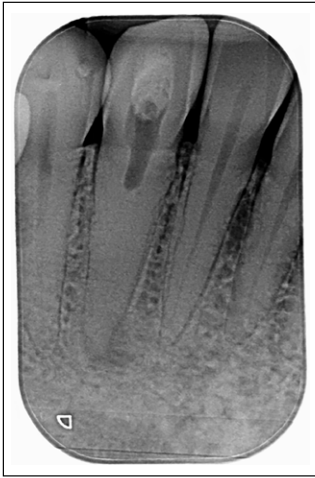Static Guided Endodontics (GE) was then made simpler by using a single software program combining all the stages of the planning process, from visualization of the STL and DICOM files, to design the static guide and then printing the guide in resin materials. Some authors have applied this technique in cases involving maxillary (13) and mandibular incisor (14) and molar (15) root canal obliteration, as well as for removal of fiber-reinforced posts (16). In this article, four clinical cases were described involving the use of an endodontic static guide to perform endodontic treatment in a calcified root canal.

## Report

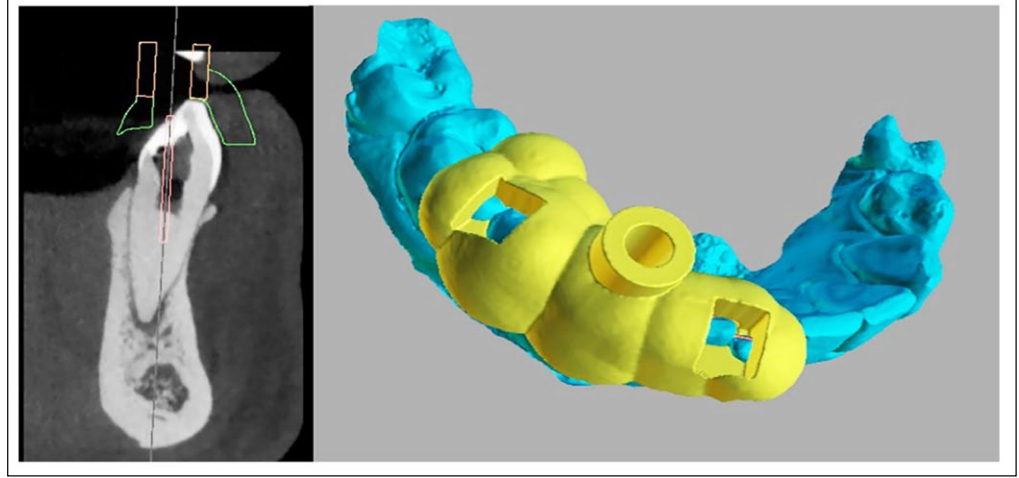
### Case 1

A 50-year-old female patient was referred following unsuccessful endodontic treatment on the mandibular right canine (tooth 43). She reported a trauma which had occurred 15 years before. The tooth presented with yellowish discoloration, was painful to percussion and reported a negative response to electric and thermal sensitivity tests (figure 1). This finding was confirmed by CBCT (VGI, Evo NewTom) with a 55 mm scan field of view and 100-micron resolution. The patient's informed consent was obtained to perform orthograde treatment by GE. The STL file of the arch





**Figure 1**  
Preoperative X-ray. The patient was referred for treatment of tooth 43 displaying calcification and symptomatic periapical periodontitis.

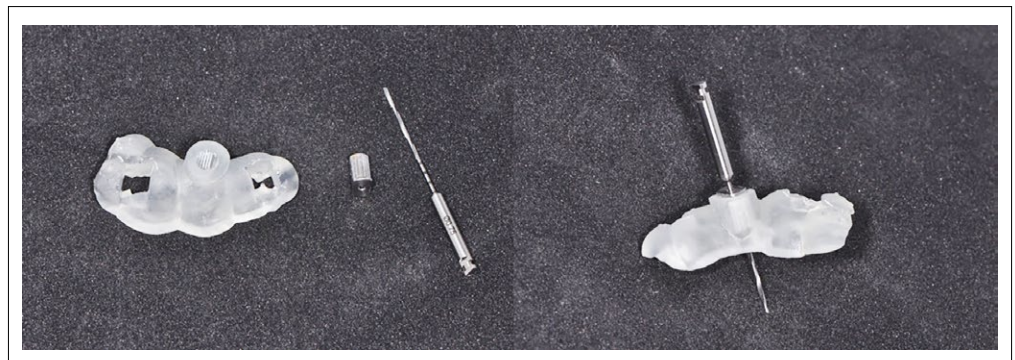

**Figure 2**  
Planning the guide. The guide was designed using BlueSkyPlan freeware. The bur was designed and planned on the dicom file and oriented to ensure correct endodontic access to the calcified canal.

was obtained by optical impression and uploaded to the BlueSky Plan software (BlueSkyBio; LLC; Grayslake; IL; USA). The aim was to superimpose the digital image of the arch on the CBCT views. Merging of the two files was achieved by means of fixed reference points on the crown surface of all the teeth of the full arch. In this way, the inner surface of the guide can be modelled depending on the digital impression (figure 2). The sleeve slot was realised according to the position of the drill simulated on the DICOM images. Finally, two occlusal windows were virtually created on the guide to check proper clinical fit. The STL file for the guide was then downloaded and dispatched for 3D printing. The guide was printed in resin using a


Formlabs 2 printer (Formlabs Inc; Somerville; MA; USA). In fact, the metal sleeve was then inserted under friction into the resin guide to orient a drill 0.75 mm in diameter and 23 mm in length (FFDM Pneumat Tivoly; Bourges; France) (figure 3). During the clinical appointment the operative field was isolated using a rubber dam placed on several teeth to avoid interference between the guide and the clamp. The guide was tested to ensure a proper fit and stability on the teeth. The drill, mounted on a low-speed contra-angle, was inserted into the sleeve, then rotated at 20,000 RPM. The guide was kept very stable by the clinician during drilling. At every millimeter of progress along the canal, the guide was withdrawn to allow the access cavity to

**Figure 3**  
3D impression of the guide. The resin guide was printed; the bur used was cylindrical (0.75 mm in diameter and 23 mm in length) (FFDM Pneumat Tivoly) (made by Asselin Bonichon lab).





**Figure 4**  
Drilling path. A staggered drilling pattern was performed. At every millimeter of progress along the canal, the guide was withdrawn to allow irrigation of the access cavity and avoid overheating of the dentin and accumulation of dentin debris.



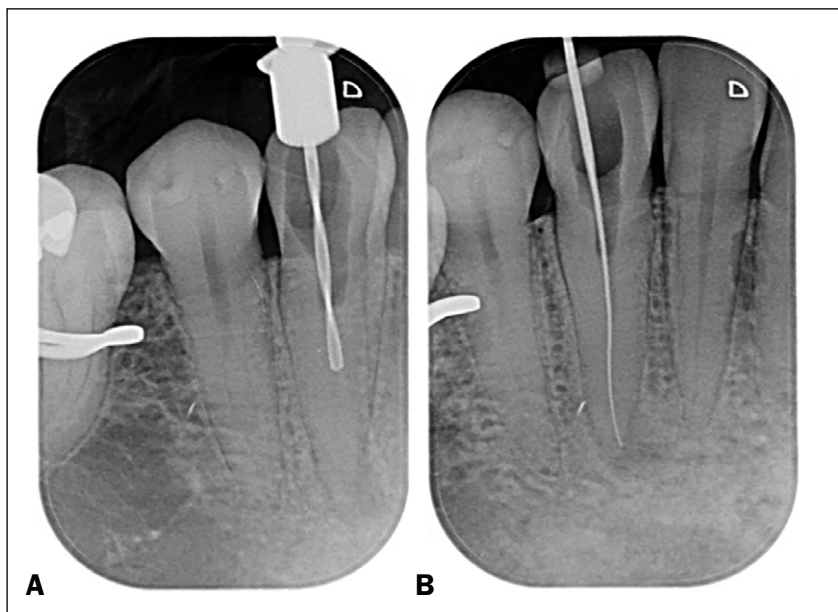
be irrigated. The irrigation avoids overheating of the dentine and accumulation of dentine debris (figure 4). An intraoperative radiograph was taken to confirm the correct trajectory during the treatment (figure 5A). Once the drill was fully inserted into the sleeve, patency was checked by means of a C+ .06 file (Dentsply Sirona Endodontics, Ballaigues, Switzerland) and endodontic treatment was normally completed (figure 5B). Shaping was performed using the ProTaper Gold System (Dentsply Sirona Endodontics, Ballaigues, Switzerland). The irrigation consisted of a sodium hypochlorite 3% solution (Vistadental, Racine, Wisconsin, USA) and EDTA 17% solution (Vistadental, Racine, Wisconsin, USA) The canal was then filled us-

ing a warm vertical compaction technique (figure 6). Lastly, the tooth was obturated at crown level using an occlusal composite.

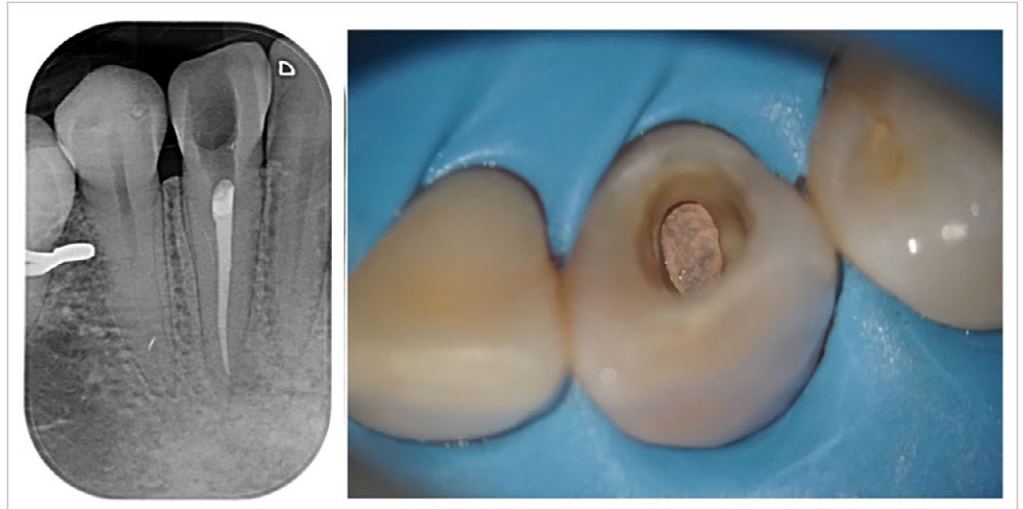
*Case 2*

A 46-year-old male patient was referred for esthetic reasons regarding the upper right central incisor (tooth 11). The tooth showed no response to electric and thermal vitality tests and was asymptomatic when subjected to percussion and palpation. The patient reported a trauma falling from his bicycle 15 years before. An emergency treatment was initially performed by his first dentist at the time of the trauma, but unsuccessfully. The tooth had been restored with composite. No symptoms had appeared over the years. Radiological examination by periapical x-ray and CBCT revealed a periapical lesion and the almost complete obliteration of the root canal of tooth 11 (figure 7A, C). GE treatment was scheduled in agreement with the patient. The treatment was performed using the same protocol as for case #1 (figure 8). The resin guide and the metal sleeve helped to obtain root canal patency 3 mm from the apex, following a 17 mm of coronal drilling through the guide. Once root canal patency was obtained, shaping was performed using the ProTaper Gold system (Dentsply Sirona Endodontics) and filling of the root canal was performed using a cold obturation technique combining Totalfill bioceramic sealer (FKJ, La ChauxdeFonds, Switzerland) and a single gutta-percha cone (PD, Vevey, Switzerland). The tooth was

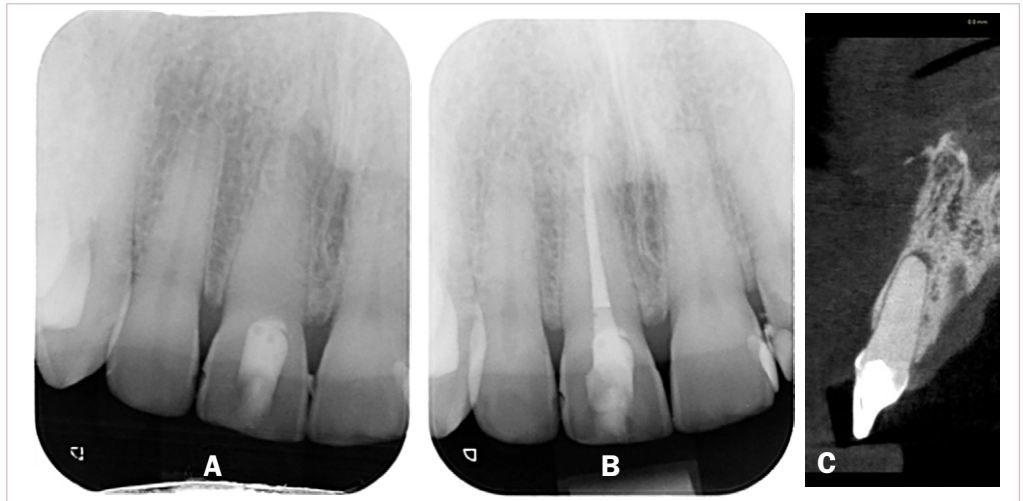
**Figure 5**  
Intraoperative X-rays to confirm the axes (A) and restore patency (B).



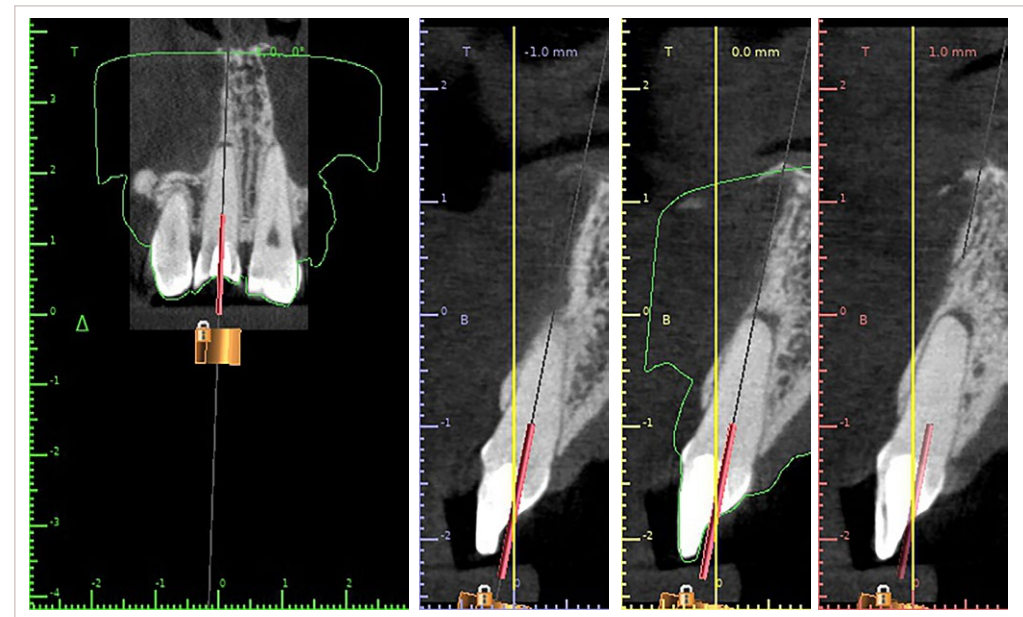
**Figure 6**  
The endodontic treatment was performed using classical endodontic techniques.



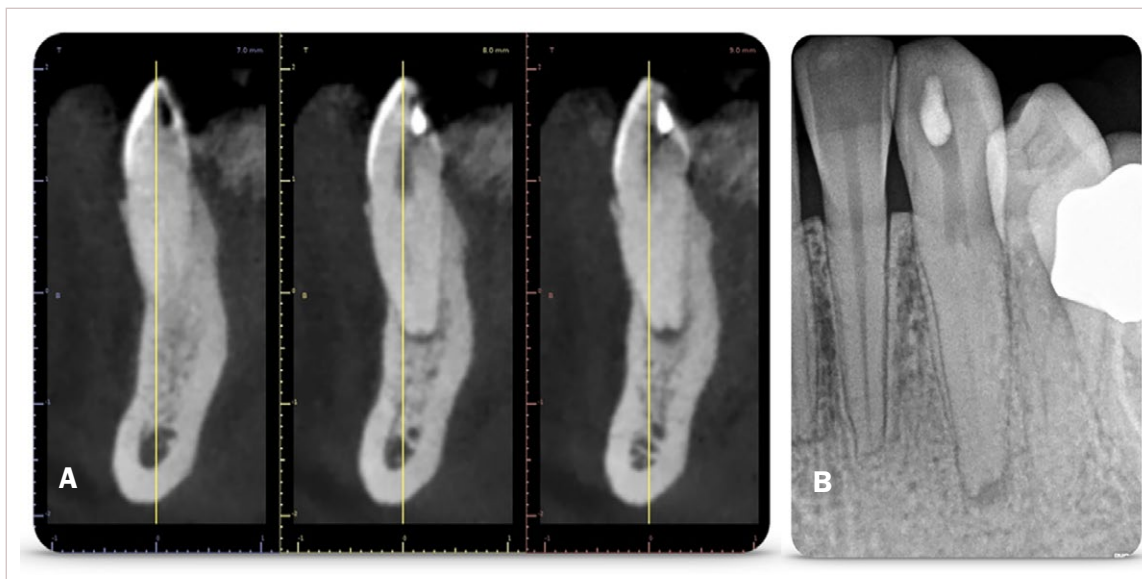
**Figure 7**  
(A) Pre- and (B) post-operative X-ray and CBCT slice (C) of tooth 11 of case 2. Tooth 11 was calcified.



**Figure 8**  
Planning endodontic access with BlueSkyPlan.



**Figure 9**  
Pre-operative cbct (A) and X-ray (B) of tooth 33 of case 3. The patient was referred for treatment of tooth 33 displaying calcification and symptomatic periapical periodontitis (courtesy Dr Virginie Touboul).



restored with glass ionomer cement (Fuji II, GC Corporation, Tokyo, Japan) and a resin composite resin.

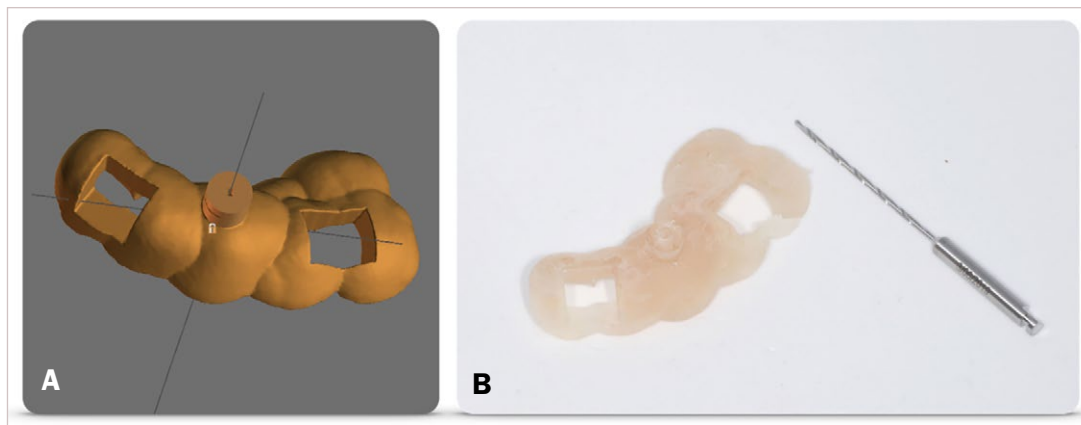
*Case 3*

This 43-year-old female patient was referred by her dentist for orthodontic treatment on the mandibular left canine (tooth 33). She had a trauma on the left side of her mandible 8 years previously. The tooth became yellow in the recent years and symptomatic over the past few months. The patient complained of pain on percussion and described an episode of spontaneous pain which receded after antibiotic treatment. Following this episode of pain, her dentist attempted a first endodontic treatment, but unsuccessfully. The in-

tra-oral radiograph showed a periapical lesion and root canal obliteration, confirmed by CBCT (figure 9A, B). The diagnosis was symptomatic apical periodontitis.

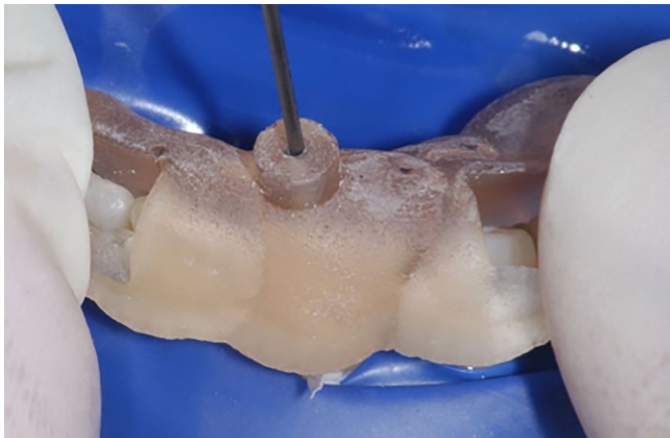With the patient consent, GE treatment was planned. In this case it was decided not to place a sleeve. The static resin guide was fabricated with a guide hole 7 mm in length adapted to the drill diameter (figure 10)

The initial access achieved by the previous intervention was incorrect. Consequently, in order to make the access cavity along the axis of the root canal that was previously identified by the CBCT, it was essential to mark a reference point on the enamel through the guidance hole using a graphite pencil

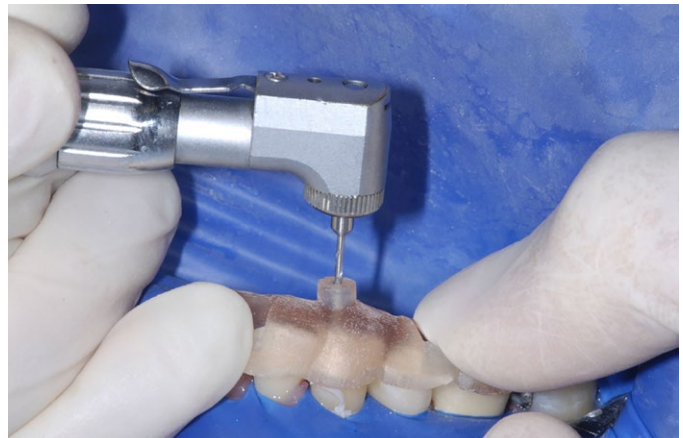

**Figure 10**  
Planning (A) and Printing (B) the guide. The resin guide is sleeveless and was fabricated with a 7 mm in length guidance orifice and adapted to the drill diameter.



**Figure 11**

Marking a reference point for the first access. It is essential to mark a reference point on the enamel through the guidance hole using a graphite pencil lead.

**Figure 12**

Drilling path. Drilling was then performed following the protocol step-by-step used in Case 1.

**Figure 13**

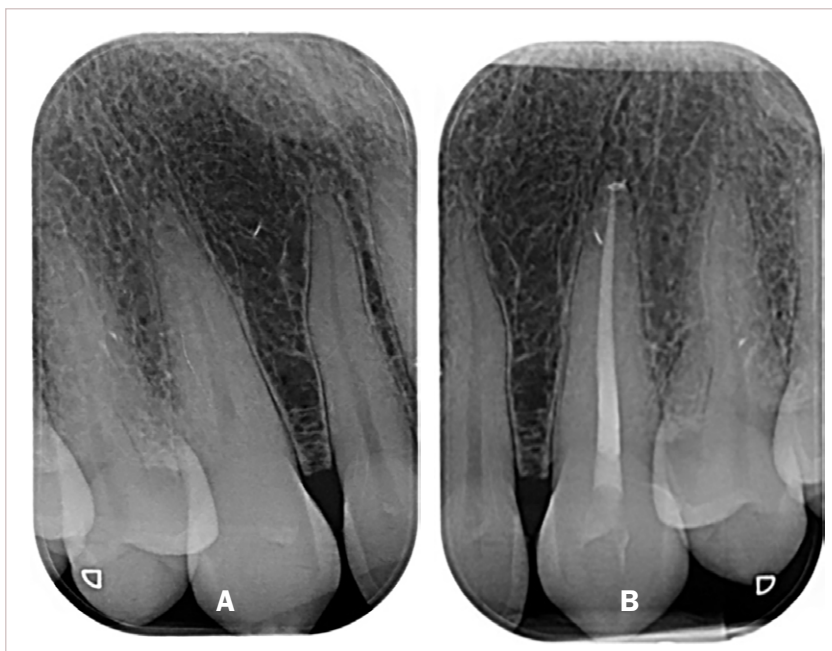Pre- and postoperative X-ray case 4. This system enabled us to quickly locate the endodontic canal without excessive damage. Classic end of treatment was achieved (courtesy Dr Cyril Perez).

lead (figure 11). A diamond bur was used to open the access cavity into enamel and to achieve a flat dentine surface perpendicular to the drill axis. Drilling was then performed following the protocol step-by-step used in Case #1 (figure 12). Once the apical root canal patency was obtained using a manual file, shaping was performed using ProTaper Gold (Dentsply Sirona Endodontics, Ballaigues, Switzerland) and filling was car-

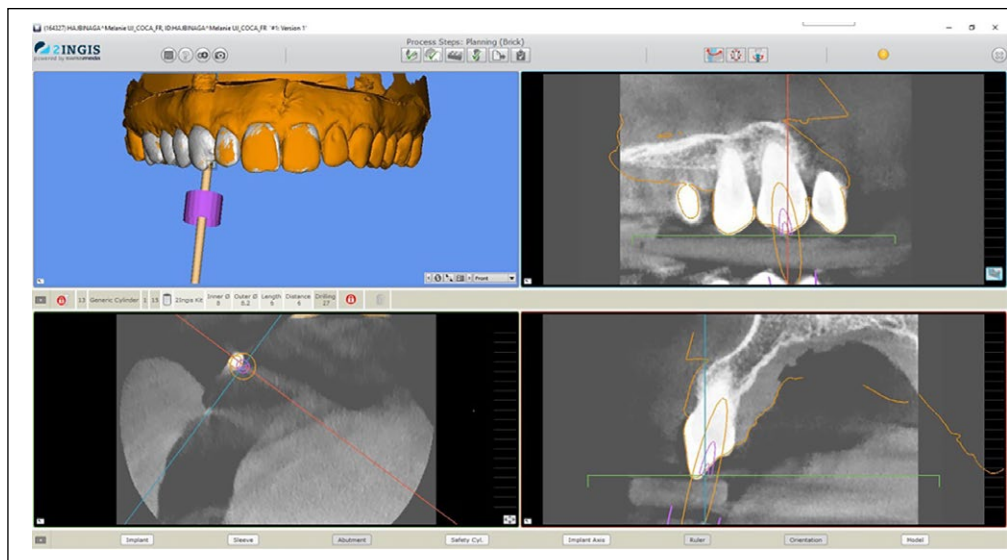
ried out using a warm vertical compaction technique. The tooth was then restored with resin composite.

#### Case 4

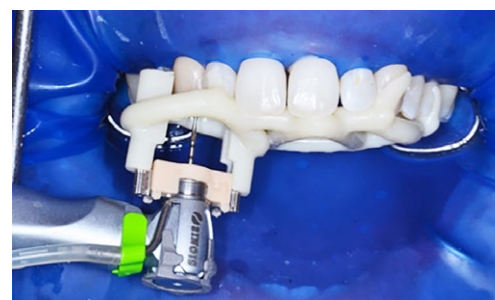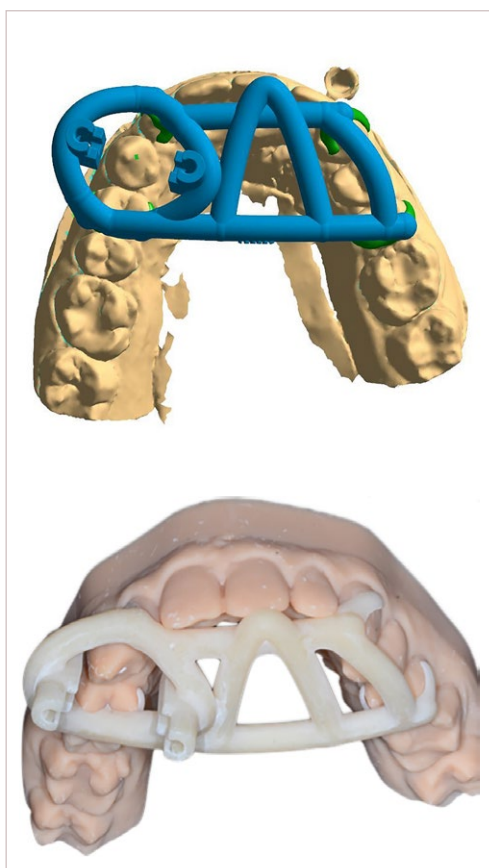
A 35-year-old female patient was referred complaining of pain involving the maxillary right canine (tooth 13) over the previous 6 months. Clinical examination showed that the tooth was sensitive to axial percussion and buccal palpation. Electric and thermal sensitivity tests were negative. The tooth also displayed yellow discoloration. The patient could not remember having undergone a trauma in the past. Pulpal necrosis was diagnosed and canal obliteration was observed on radiograph (figure 13A). The CBCT provided by the patient confirmed the presence of canal obliteration up to the middle third. With the patient consent, orthograde endodontic treatment was planned using the 2Ingis guided endodontics system. 2Ingis is a system of surgical guides originally designed for the placement of dental implants. The drilling guidance is obtained by a linear movement of the contra-angle sliding through two rails incorporated in the drilling template printed. A silicon impression was taken during the initial visit. The impression was then scanned by the dental laboratory, which produced a STL



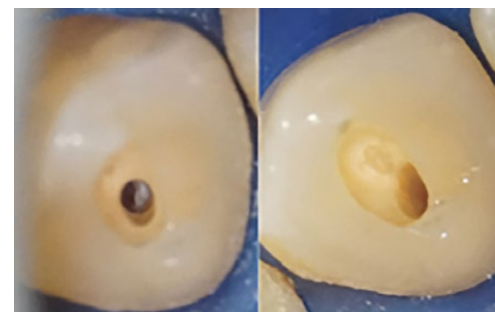
**Figure 14**  
Planning the guide with SMOP software (2ingis).



**Figure 14A**  
The digital design of the 2ingis guide and his 3D impression. The guide is digitally designed using certain teeth for support.



**Figure 15**  
Clinical view. The 2ingis guide designed to direct the head of the contra-angle.



**Figure 16**  
Cavity access with 2ingis technique: a diamond bur mounted on the contra-angle and guided by the 2ingis system was used to prepare the cavity access.

file of the model. The drilling plan was drawn up by the 2ingis company using SMOP software (Swissmeda; Baar; Switzerland) (figure 14). The plan was verified and validated by the operator and an endodontic guide was digitally designed

using four teeth as support (figure 15) and printed. A diamond bur mounted on the contra-angle at a speed of 40,000 RPM and guided by the 2ingis system was used to prepare the access cavity into the enamel. Then, a 0.75 drill with



a guided low-speed contra-angle head at a speed of 20,000 RPM was used to penetrate into the dentine.

The irrigation is achieved by the water spray of the contrangle. This system enables to quickly locate the endodontic canal without excessive sacrifice of the tooth structure. A standard endodontic treatment was then performed in one visit once the canal orifice was located followed by the placement of a coronal resin composite restoration (figure 16).

## Discussion

In 2005, the American Association of Endodontists published a form for the assessment of endodontic treatment difficulty. Management of root-canal obliteration is included in the high level of difficulty (17). Different techniques have been reported for the management of obliterated canals. Some authors suggested orientating the axis of the access cavity along the axis of the tooth in order to improve visibility of the dentine (18). The use of dental microscope in conjunction with long-necked burs or ultrasound inserts was also recommended (18). It has also been suggested to take numerous intraoperative X-rays to control and reorientate the drilling axis to gain access to the canal (8). The new concept of guided endodontic access (GE) is based on the use of protocols from guided implantology to perform a safe cavity access in difficult cases as calcified canals. This technique consists of planning the drilling path using a software merging the STL and DICOM data. The digital guide exported by the digital project is printed with a 3D printer in a resin material.

The four clinical cases presented in this article demonstrated that conservative maintenance of sound dental tissues is one of the main advantages of GE. Less invasive than the classic techniques, GE also limits the risk of deviation and reduces operative time (19, 20, 21). Endodontic surgery also offers an alternative solution although, with this technique, the endodontic canal cannot always be cleaned along its entire length (22).

On the other hand, in situations involving

obliterated canals after the curve, endodontic surgery is the most appropriate treatment approach. Studies on obliterated teeth are still needed to compare the respective success rates of endodontic surgery and GE orthograde treatment. Meanwhile, the two techniques remain complementary. Guided implantology supplies the know-how to enable its application to endodontics. It has been demonstrated that the guided technique can position an implant more accurately compared with a free-hand technique (23). As a result, the guided approach can be considered more predictable. Nonetheless, deviations ranging from 2.29° to 5.2° are considered tolerable in implantology (24, 25). In GE, such deviations can be considered significant in cases of very apical canal obliteration. Recently, several studies have attempted to validate this endodontic treatment technique for obliterated pulp canals. Buchgreitz et al. reported a linear drill deviation of 0.46 mm at the apical target (21). Two other studies have shown the presence of angle deviations ranging from 1.59° to 1.81° using drills with a diameter of 0.85 mm and 1.5 mm, respectively (19, 20). The authors judged these margins of error to be minimal.

The clinical protocol proposed in the present report include 3 main features:

1. The use of a static guide over only 3-4 teeth. Generally, the static guides presented in case reports involved the entire arch and are even stabilized in some cases with miniscrews inserted in the bone (26). A less extensive guide makes easier the isolation and the peri-apical radiography. Conversely, stability is diminished, although this had no great impact on the successful outcome of the presented clinical cases.
2. The use of a small-diameter drill (0.75 mm) (FFDM-Pneumativoly; Bourges; France). The literature reports description of drill diameters between 0.85 mm and 1.5 mm (19, 20). A 0.75 mm drill permits a less invasive procedure, even to the apical third. On the downside, the smaller is the drill diameter, the more flexible is the drill and the greater is the risk of deviation during the



first steps of the access procedure. However, case 3 showed that even the apical region of the obliterated canal can be successfully reached. While the benefits of using less extensive guides and small diameter drills appear obvious, clinical studies are needed to confirm the reproducibility of the technique.

3. The planning and fabrication of the guide were done using the BlueSky Plan planning software program (BlueSkyBio; LLC; Grayslake; IL; USA). This software is free of charge and only the downloading of the STL file of the guide is subject to payment. A DICOM file taken from a CBCT and a STL file taken from a digital impression of the teeth may be merged in the system. CBCT scans can be performed in a radiology laboratory or in the dental office and digital impressions can be made in a laboratory from a silicon impression or directly in the mouth using an intra-oral scanner. The GE technique therefore may be also performed without any special equipment in the dental office.

The accuracy of GE drilling is linked to a series of errors to be avoided. Accuracy is dependent on the quality of both the CBCT and the digital impression, on the successful merging of the two files, on the drilling plan, on the printing of the guide and on the clinical step-by-step. During the planning stage, it may sometimes be difficult to locate the canal on the CBCT.

The literature reports that, in the event of pulpal canal calcification, the canal space of single-root teeth is always located in the center of the root in an axial view (18). Importantly, the drilling axis will sometimes be aligned with the main tooth axis, meaning the access cavity will be situated very close to the free edge of the tooth in the anterior region.

During the clinical procedures, the access cavity plays a crucial role. Its design must help avoid any interference between the drill and the cavity axial

walls. The floor of the cavity must be flat and perpendicular to the drilling axis. Failing in this objective may lead to the fact that the drill could be deviated as soon as the drilling action begins and the tip may slide across the sloping cavity floor. The access cavity must be prepared using a diamond bur to start access in the enamel. To locate the access cavity, the guide can be used to mark the first point of contact through the sleeve by means of a graphite pencil. This phase can be repeated several times in order to find a flat central access point with no lateral interference. This step is essential whether preparing a first-line access cavity or during retreatment where the access already exists.

The second possible error during the clinical step-by-step may be connected to a precise positioning of the guide. Proper insertion of the guide must be verified using the openings on its occlusal surface. The guide must be held firmly in place during the drilling procedures to avoid it vibrating and being dislodged. Lastly, the contra-angle must be held as close as possible to the head of the instrument and should be brought down passively to avoid rotating the assemblage formed by the contra-angle, the drill and the guide.

Thus, a microscope can still provide a useful service. The endodontic guide serves to drill millimetre by millimetre towards the apex. At each step, the guide must be removed to allow the canal to be probed manually and to help check the canal patency. At all stages, when the guide is removed, the canal can also be rinsed out to prevent dentine remnants from accumulating and forming a blockage. Rinsing also avoids overheating of the dentine during drilling. Clinicians should keep in mind that CBCT resolution may identify a canal more apically than what may happen clinically.

Thus, it is important to try if a manual file may be inserted in the canal even if drilling is not arrived to the apical point of the guide, as the further the drill is used towards the apex, the greater is the



risk of deviating from the canal path. In the event of deviation, CBCT can be used to relocate the canal intra-operatively with techniques not using an endodontic guide.

Further advances in GE will possibly lead to the metal sleeve being not used, thus avoiding positioning errors when inserting the sleeve in the guide. In fact, depending on the printer and its settings, as well as the resin used to build up the guide, the sleeve can be inserted in the guide with varying degrees of passivity. It may happen that the sleeve moves in the guide or that it could not be completely inserted. Note that, when not using a metal sleeve, it is important to use guides made from very hard materials.

Unlike the previous cases that used closed static endodontic guides, in the case 4 the 2ingis solution was adopted. This system uses an open endodontic guide system that guides not the drill but the head of the contra-angle.

The technique using a closed guide has the disadvantage of preventing irrigation during the drilling phase, thus increasing the risk of accumulated dentin remnants and, probably, of metal debris due to drilling through the metal sleeve. Lack of irrigation will also cause both the drill and the tooth to heat-up. For this reason, it is important to advance gradually with the drill, millimetre by millimetre, stopping and rinsing in between the steps.

The 2ingis system enables irrigation during drilling and allows the use of any kind of bur, including small-diameter, long-necked round burs as well as diamond burs, which can create the access directly into the enamel.

On the other hand, the absence of a sleeve increases the risk of oscillation of the bur, as it rotates free. A study using the 2ingis system in implantology reported a mean deviation angle of 2.85°. It also described more precise deviations than with implant guides using sleeves (27).

An alternative to obtain a guided access in endodontics is a new dynamic three-dimensional technology. This free-hand method works with an image-guid-

ed procedure merging CBCT data and a computer assisted software, guiding the high-speed handpiece and bur during the clinical procedures. This technique could be the future of guided endodontics even if up to date, this kind of technology presents some limits for a full application in the Endodontic field such as the accuracy declared by the manufacturer companies of about 0.5 mm and the radiographic artifacts due to the presence of metal crowns (28).

## Conclusions

Endodontic treatment of a calcified tooth is a challenge for the dentist, even if equipped with a microscope, as the risk of intra-operative errors is very high (2). The precision of the GE technique seems to provide a valid alternative to endodontic surgery for the treatment of calcified canals. GE helps gain canal permeability reducing operative time respect to a free-hand approach. The 2ingis system helps overcome the irrigation issue and leaves the clinician free to choose the bur to be used. This open endodontic concept appears to be better suited to endodontic interventions than closed guides.

## Clinical Relevance

This article describes several variations of the guided technique in the endodontic treatment of obliterated canals and highlights its advantages and limitations.

## Conflict of Interest

The authors declare they have no conflicts of interest.

## Acknowledgements

The authors wish to thank Dr Cyril Perez for his contribution to the development of the technique, Dr Virginie Touboul for support in treating one of the clinical cases, and Asselin Bonnichon for developing the Cad-Cam technique for use in GE.

## References

1. Goodis HE, Kahn A, Simon S. Aging and the pulp. In: Hargreaves K, Goodis HE, Tay F (eds). *Seltzer and Bender's dental pulp*, 2nd edition, Hanover Park: Quintessence Publishing 2012;421-446.
2. Amir FA, Gutmann JL, Witherspoon DE. Calcific metamorphosis: a challenge in endodontic diagnosis and treatment. *Quintessence Int* 2001;32:447-455.
3. McCabe P.S., Dummer P.M.H. Pulp canal obliteration: an endodontic diagnosis and treatment challenge. *Int Endod J* 2012;45:177-197.
4. Oginni AO, Adekoya-Sofowora CA, Kolawole KA. Evaluation of radiographs, clinical signs and symptoms associated with pulp canal obliteration: an aid to treatment decision. *Dent Traumatol*. 2009;25(6):620-5.
5. Cvek M, Granath L, Lundberg L. Failures and healing in endodontically treated non-vital anterior teeth with post traumatically reduced pulpal lumen. *Acta Odontol Scand* 1982;40:223-228.
6. Ingle JI. Endodontic cavity preparation. In: Ingle J, Tamber J, eds. *Endodontics*, 3rd ed. Philadelphia: Lea & Febiger 1985;102-67.
7. Clark D, Khademi J. Modern molar endodontic access and directed dentin conservation. *Dent Clin North Am* 2010;54:249-73.
8. Clark D, Khademi JA. Case studies in modern molar endodontic access and directed dentin conservation. *Dent Clin North Am* 2010;54:275-89.
9. Kfir A, Telishevsky-Strauss Y, Leitner A, Metzger Z. The diagnosis and conservative treatment of a complex type 3 dens invaginatus using cone beam computed tomography (CBCT) and 3D plastic models. *Int Endod J* 2013;46:275-88.
10. Byun C, Kim C, Cho S, Baek SH, Kim G, Kim SG. Endodontic treatment of an anomalous anterior tooth with the aid of a 3-dimensional printed physical tooth model. *J Endod* 2015;41:961-5.
11. Van der Meer WJ, Vissink A, Ng YL, Gulabivala K. 3D Computer-aided treatment planning in endodontics. *J Dent* 2016;45:67-72.
12. Krishan R, Paque F, Ossareh A, et al. Impacts of conservative endodontic cavity on root canal instrumentation efficacy and resistance to fracture assessed in incisors, premolars, and molars. *J Endod* 2014;40:1160-6.
13. Krastl G, Zehnder MS, Connert T, Weiger R, Kuhl S. Guided Endodontics: a novel treatment approach for teeth with pulp canal calcification and apical pathology. *Dent Traumatol* 2016;32:240-6.
14. Connert T, Zehnder MS, Amato M, Weiger R, Kuhl S, Krastl G. Microguided endodontics: a method to achieve minimally invasive access cavity preparation and root canal location in mandibular incisors using a novel computer-guided technique. *Int Endod J* 2018;51:247-55.
15. Shi X, Zhao S, Wang W, Jiang Q, Yang X. Novel navigation technique for the endodontic treatment of a molar with pulp canal calcification and apical pathology. *Aust Endod J* 2018;44:66-70.
16. Perez C, Finelle G, Couvrechel C. Optimisation of a guided endodontics protocol for removal of fibre-reinforced posts. *Aust Endod J* 2019 ; <https://doi.org/10.11/aej.12379> [epub ahead of print].
17. American Association of Endodontists. *Endodontic Case Difficulty Assessment and Referral*. Colleagues for Excellence, Newsletter of AAE. Spring/summer 2005.
18. Lovdahl PE, Gutmann JL. Problems in locating and negotiating fine and calcified canals. In: Gutmann JL, Dumsha TC, Lovdahl PE, Hovland EJ, eds. *Problems Solving in Endodontics: Prevention, Identification and Management*, 3rd edn. St. Louis, USA: Mosby Year Book 1997;69-89.
19. Connert T, Zehnder MS, Weiger R, Kuhl S, Krastl G. Microguided endodontics: accuracy of a miniaturized technique for apically extended access cavity preparation in anterior teeth. *J Endod* 2017;43:787-90.
20. Zehnder MS, Connert T, Weiger R, Krastl G, Kuhl S. Guided endodontics: accuracy of a novel method for guided access cavity preparation and root canal location. *Int Endod J* 2016;49:966-972.
21. Buchgreitz J, Buchgreitz M, Mortensen D, Bjørndal L. Guided access cavity preparation using cone-beam computed tomography and optical surface scans - an ex-vivo study. *Intl Endod J* 2016;49:790-5.
22. Carrotte P. Surgical endodontics. *Br Dent J* 2005;198(2):71-9.
23. Kuhl S, Payer M, Zitzmann NU, Lambrecht JT, Filippi A. Technical accuracy of printed surgical templates for guided implant surgery with the coDiagnostiX software. *Clin Implant Dent Relat Res* 2015;17(Suppl 1):177-82.
24. Rungcharassaeng K, Caruso JM, Kan JY, Schutyser F, Boumans T. Accuracy of computer-guided surgery: A comparison of operator experience. *J Prosthet Dent* 2015;114:407-413.
25. Deselmann C, Rudolph H, Luthardt RG. Retrospective study to determine the accuracy of template-guided implant placement using a novel non-radiologic evaluation method. *Oral Surg Med Oral Pathol Oral Radiol* 2016;121:e72-e79.
26. Lara-Mendes STO, Barbosa CFM, Machado VC, Santa-Rosa CC. Guided endodontics as an alternative for the treatment of severely calcified root canals. *Dental Press Endod*. 2019;9(1):15-20.
27. Schnutenhaus S, von Koenigsmarck V, Blender S, Ambrosius L, Luthardt RG. Precision of sleeveless 3D drill guides for insertion of one-piece ceramic implants: a prospective clinical trial. *Int J Comput Dent*. 2018;21(2):97-105.
28. Chong BS, Makdissi J. Computer-aided dynamic navigation: a novel method for guided endodontics. *Quintessence Int* 2019; 50: 196-202.



## CASE REPORT/CASO CLINICO

# Regenerative endodontic treatment options for immature permanent teeth: a case report with 21-month follow-up

Alternative terapeutiche per denti permanenti immaturi nel campo della rigenerazione endodontica: descrizione di un caso clinico con controlli fino a 21 mesi

**KEYWORDS**

Regenerative Endodontics, Incisor, Calcium Hydroxide

**PAROLE CHIAVE**

Endodonzia Rigenerativa, Incisivo, Idrossido di Calcio

**Mariana Carvalho  
Furtado Leite<sup>3</sup>**

**Claudio Maniglia Fereira<sup>1</sup>**

**Fabio de Almeida  
Gomes<sup>1,2\*</sup>**

**Fernanda Geraldo Pappen<sup>2</sup>**

**Tamara Kerber Tedesco<sup>3</sup>**

**Ana Flávia Bissoto Calvo<sup>3</sup>**

**José Carlos  
Pettorossi Imparato<sup>3</sup>**

<sup>1</sup>Department of Endodontics,  
University of Fortaleza, CE, Brazil

<sup>2</sup>Department of Endodontics,  
Federal University  
of Pelotas, RS, Brazil

<sup>3</sup>Department of Paediatric  
Dentistry, Faculty Sao  
Leopoldo Mandic, Brazil

Received 2020, January 30

Accepted 2020, March 16

**Abstract**

A treatment option for necrotic teeth with incompletely formed roots is apexification with calcium hydroxide, which induces the formation of a hard tissue barrier at the apex, however, in the long term, this medicament may increase the brittleness of dentin walls because of its hygroscopic and proteolytic properties, in addition to the disadvantage of requiring multiple appointments. An alternative to this is the mineral trioxide aggregate (MTA) artificial barrier technique, that unfortunately share with the previous one the disadvantage of preventing the complete root maturation. A new possible treatment for young permanent teeth with necrotic pulps is pulp regeneration, whose advantage lies in the stimulation of new tissue formation within the root canal. Pulp revascularization is based on the disinfection of the root canal system, often performed with irrigating solutions and intracanal medicaments, accompanied by induction of periapical bleeding and formation of a blood clot that will fill the root canal.

The aim of this study was to present a case of avulsion of teeth 11 and 21, both with open apices, treated with replantation associated with regenerative endodontic therapy, but varying the intracanal medicaments used: calcium hydroxide in tooth 11 and double antibiotic paste in tooth 21. Pulp revascularization proved to be effective with both intracanal medicaments used, promoting symptom resolution and complete root development, including apical closure, even in the absence of a well-defined clinical.

Una opzione per il trattamento dei denti necrotici con radici non formate completamente è la apacificazione con l'idrossido di calcio, la quale induce la formazione di una barriera di tessuto duro a livello apicale, tuttavia, nel lungo termine, questa medicazione può aumentare la fragilità delle pareti dentinali per via delle sue proprietà igroscopiche e proteolitiche, inoltre questa tecnica ha lo svantaggio di richiedere molteplici sedute. Un'alternativa è la tecnica della barriera artificiale con l'utilizzo del Mineral Trioxide Aggregate (MTA) che, sfortunatamente, condivide con la tecnica precedente lo svantaggio di impedire il completo sviluppo radicolare. Una nuova possibilità di cura per i denti permanenti immaturi con la polpa necrotica è la rigenerazione, il cui vantaggio giace nella stimolazione della formazione di nuovo tessuto dentro al canale radicolare. La rivascularizzazione della polpa si basa nella disinfezione del sistema canale radicolare, spesso eseguita con l'utilizzo di soluzioni irriganti e medicazioni intra-canalari, accompagnata dall'induzione del sanguinamento peri-apicale e la formazione di un coagulo sanguigno che andrà a riempire il canale radicolare.

Lo scopo di questo studio è stato quello di presentare il caso di un paziente con i denti 1.1 e 2.1 immaturi con apici aperti, avulsi, trattati con il reimpianto e associato a terapie rigenerative endodontiche, variando le medicazioni intra-canalari utilizzate: idrossido di calcio sul dente 1.1 e una pasta bi-antibiotica (DAP) sul dente 2.1. La rivascularizzazione della polpa si è provata efficiente utilizzando le due medicazioni, promovendo la risoluzione dei sintomi e il completamento dello sviluppo radicolare, includendo la chiusura apicale, anche in assenza di un protocollo clinico ben stabilito.

**Corresponding author**

Address requests for reprints to Fabio de Almeida Gomes | Rua Paula Ney 925,ap 501, Aldeota, zip code 60140-200, Fortaleza, CE | Brazil  
fabiogomes@unifor.br

Peer review under responsibility of Società Italiana di Endodonzia

10.32067/GIE.2020.34.01.05

Società Italiana di Endodonzia. Production and hosting by Ariesdue. This is an open access article under the CC BY-NC-ND license (<http://creativecommons.org/licenses/by-nc-nd/4.0/>).

## Introduction

**E**ndodontic therapy for immature permanent teeth with necrotic pulps is a major challenge in dentistry. With pulp necrosis, the dentin walls of the root canal remain thin and susceptible to fracture, thus limiting biomechanical preparation (1, 2).

The treatment of choice for necrotic teeth with incompletely formed roots is apexification with calcium hydroxide, which induces the formation of a hard tissue barrier at the apex (3). However, in the long term, this medicament may increase the brittleness of dentin walls because of its hygroscopic and proteolytic properties, in addition to the disadvantage of requiring multiple appointments (4). An endodontic treatment alternative for necrotic teeth with open apices is the creation of an artificial root-end barrier with mineral trioxide aggregate (MTA) (5). This technique has the advantage of reducing the number of treatment appointments. Nevertheless, both methods (apexification with calcium hydroxide and artificial apical barrier technique with MTA) have the disadvantage of not allowing the continuation of root development (6, 7).

A treatment option for young permanent teeth with necrotic pulps is pulp regeneration, whose major advantage lies in the stimulation of new tissue formation within the root canal (8). Pulp revascularization is based on the disinfection of the root canal system, often performed with irrigating solutions and intracanal medicaments, accompanied by induction of periapical bleeding and formation of a blood clot that will fill the root canal. Undifferentiated cells originating from the apical papillae, associated with growth factors, will then initiate the formation of new tissue within the root canal.

Controlling intracanal infection is crucial to the success of regenerative endodontic procedures (9, 10). In conventional endodontic therapy, the reduction of bacterial loads along with adequate root canal sealing with filling material are often sufficient to control infection. The absence of substrate

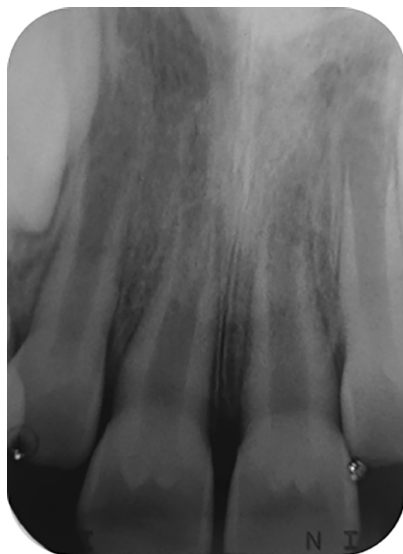to maintain the viability and proliferation of these microorganisms ultimately determines their death. However, in regenerative endodontic procedures, the apex is not sealed, since communication of the root canal with periapical tissues is an essential source of nutrition for the newly formed tissue. Conversely, this condition may also provide an access for bacterial substrate, negatively interfering with the success of the therapy (11,12). Therefore, creating and maintaining an aseptic environment is essential to allow the establishment of the new tissue in the root canal space.

In view of the foregoing, it is necessary to determine a strict disinfection protocol before a pulp regeneration approach. In the protocol for regenerative endodontic procedures proposed by the American Association of Endodontists (13), the placement of antibiotic or calcium hydroxide pastes as intracanal medicaments for 1 to 4 weeks is recommended for disinfection of the canal space.

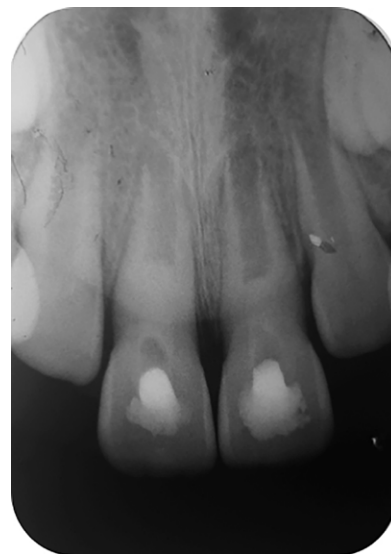
Calcium hydroxide paste is widely used in endodontics to disinfect the root canal system and to induce periapical tissue repair (14). As an alternative to this medicament, antibiotic pastes have also been used to control infection in endodontic therapy. The combination of antibiotics increases the spectrum of action of the medicament, potentially improving the level of canal disinfection. For this purpose, the triple antibiotic paste (TAP) (15), composed of ciprofloxacin, metronidazole, and minocycline, was proposed for use as an antimicrobial agent in endodontic therapy (16). However, depending on the concentration of the components, this medicament may have cytotoxic effects (17). In addition, several studies have reported color changes in the crown after the use of TAP, attributable to one of the components of the mixture, minocycline, a derivative of tetracycline (17, 18, 19) that is known to induce tooth staining. In this context, alternative medicaments to TAP have been studied, such as the double antibiotic paste (DAP) (20), which is composed of only ciprofloxacin and metronidazole.

The aim of this study was to present a case

**Figure 1**  
Initial periapical radiographic exam.



**Figure 2**  
Radiographic exam with intracanal medicament.



of avulsion of teeth #11 and #21, both with open apices, treated with replantation associated with regenerative endodontic therapy, varying the intracanal medicaments used.

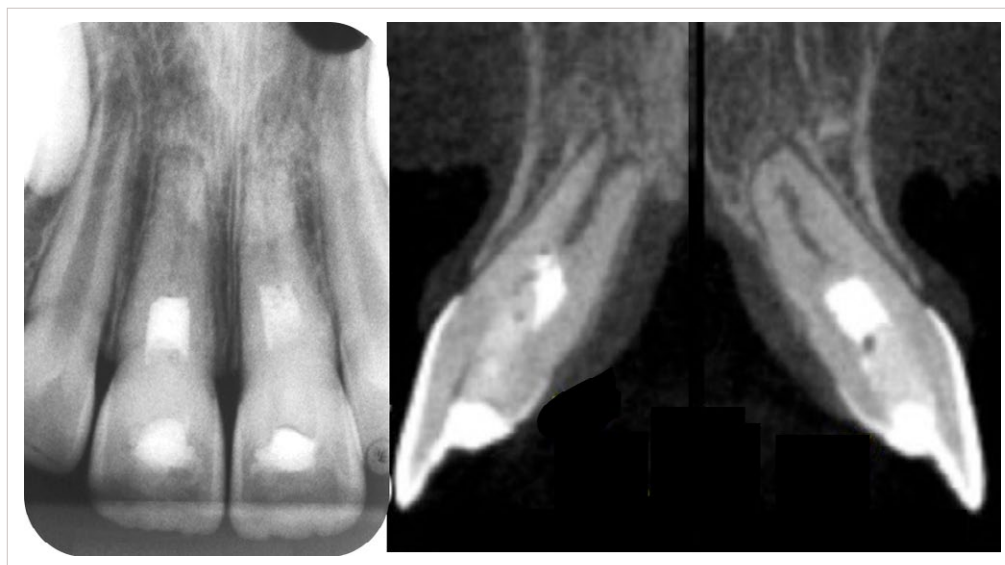### Case report

This study was approved by the Research Ethics Committee of São Leopoldo Mandic School of Dentistry, Brazil (approval number 3.404.274).

An 8-year-old girl was brought by her mother to the emergency department of Universidade de Fortaleza (UNIFOR) complaining that teeth #11 and #21 were sen-

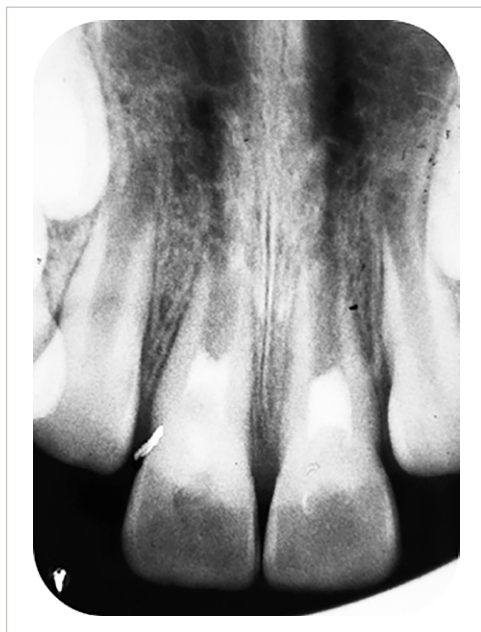
sitive to palpation and percussion and of a dark discoloration in one of them; both were buccally inclined. The patient had experienced a traumatic injury as a result of falling from a bicycle 30 days prior, with avulsion of teeth #11 and #21, which were replanted about 10 minutes after the accident by a dental surgeon at the local primary care unit. The mother's patient related that a flexible splint was used in both teeth for 14 days. Initial radiographic examination revealed that the 2 affected maxillary incisors had incompletely formed roots, with apical opening greater than 3 mm, leading to the indication of regenerative endodontic procedures in an

**Figure 3**  
Final periapical radiograph exam.





**Figure 4**  
14-month follow-up showing that apical closure of tooth #21 and that the apex of tooth #11 was still open.



attempt to induce the continuation of root development (figure 1).

At the first appointment, the root canals of both teeth were emptied and cleaned. Access cavities were prepared, and the root canals were irrigated with saline solution and debrided with a #100 K-file (Dentsply, Rio de Janeiro, Brazil). A solution of 2.5% sodium hypochlorite (Biodinâmica, Ibiporã, Brazil) was carefully dripped to avoid leakage to the periapical region, since root apices were open. The canals were flushed with EDTA (Biodinâmica, Ibiporã, Brazil) for 3 minutes to remove the smear layer, followed by final irrigation with saline solution. As an intracanal medicament, a calcium hydroxide paste (Biodinâmica, Ibiporã, Brazil) associated with 2% chlorhexidine gel (Bi-

odinâmica, Ibiporã, Brazil) was used in tooth #11, and DAP consisting of metronidazole and ciprofloxacin was used in tooth #21 (figure 2).

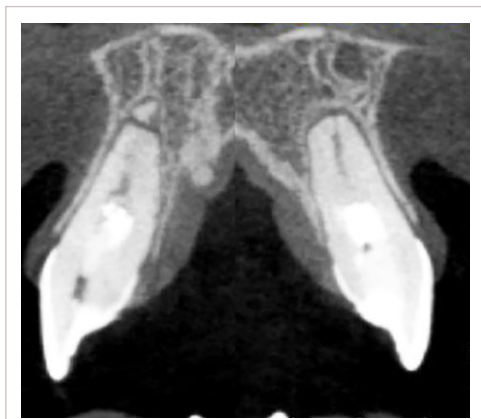The patient returned 20 days later. At this appointment, the paste was removed, and bleeding was induced into the canal space of both teeth by irritating the apical tissues with a #100 K-file until a blood clot was achieved. A sterile collagen sponge (Hemospon; Maquira, Maringá, Brazil) was used to promote hemostasis, also providing a basis for the placement and stabilization of MTA (Angelus, Londrina, Brazil) performed afterwards. The teeth were then restored with resin-modified glass ionomer cement (Vitremmer; 3M, São Paulo, Brazil), and a final periapical radiograph was taken (figure 3). A 14-month follow-up radiograph suggested root development in both teeth. Tomographic image showed that apical closure of tooth #21 began to take place and that the apex of tooth #11 was still open (figure 4). A second tomographic image, 21 months after the trauma, showed the 2 incisors with completely formed roots and complete apical closure (figure 5).

## Discussion

Regenerative endodontic therapy aims to biologically direct the growth of injured structures or even repair damaged tissues of the dentin-pulp complex, forming viable structures that, preferably, originate from similar primary tissues (21). Despite the high success rates of this therapy described in the literature, no consensus has been reached on a clinical protocol, particularly regarding irrigating solutions and intracanal medicaments (22). Maniglia-Ferreira et al. (23) concluded that, despite the lack of an established treatment protocol, it is extremely important to combine effective disinfection with the use of a series of pastes to create an environment conducive to pulp revascularization and root formation.

Decontamination of the root canal system is a critical step for further pulp regeneration. However, in immature permanent teeth, the mechanical removal of microorganisms is limited due to the thin dentin wall; therefore, it seems more prudent to promote root canal

**Figure 5**  
21-month follow-up showing completely formed roots and complete apical closure.





cleaning by using copious irrigation and intracanal medicament (8).

Sodium hypochlorite and chlorhexidine digluconate are the chemical substances most commonly used as irrigants in regenerative therapy. Both have good antimicrobial potential, but chlorhexidine, different from sodium hypochlorite, is ineffective in dissolving organic debris (24). In the case reported here, sodium hypochlorite was used with great caution by slowly dripping to prevent leakage of the solution into the periapex, since root apices were open. Subsequently, EDTA irrigation was used to remove the smear layer, followed by final irrigation with saline solution to neutralize the environment. According to Reynolds et al. (25) and Shin et al. (26), the use of saline solution as a final irrigant is of utmost importance to reduce cytotoxicity for stem cells. Galler et al. (27) stated that the success of regenerative therapy is dependent on the use of chelating agents, such as EDTA. Trevino et al. (28) confirmed that EDTA contributes to the survival of apical stem cells. Regarding intracanal medicament, a calcium hydroxide P.A. paste associated with 2% chlorhexidine gel was used in tooth #11(24,29), while DAP consisting of metronidazole and ciprofloxacin was used in tooth #21 following a similar protocol employed by Maniglia-Ferreira et al. (2017) (23) in a similar case of an avulsed immature permanent tooth with necrotic pulp.

Dhillon et al. (30) recommended that the patient should return 30 days after the first appointment for induction of apical bleeding so that blood would fill the root canal up to the cemento-enamel junction. After hemostasis, the blood clot formed in the region provided a basis for the placement of MTA. Ding et al. (31) added that MTA cervical barrier was necessary to prevent microorganisms from entering the canal. In the case reported here, the patient returned 20 days after the first appointment because she lived in another city. At this appointment, periapical bleeding was induced, followed by clot formation and MTA placement. Formation of a clot along with necrotic pulp tissue act as a scaffold for the ingrowth of new tissue, in which undifferentiated cells originating from the apical papillae and plate-

let-derived growth factors will direct cell differentiation (32). Souza Filho et al. (33) stated that, when in contact with the dentin wall, undifferentiated mesenchymal cells synthesize and secrete a cementoid tissue, promoting space closure and strengthening the root canal structure.

In cases of regenerative therapy, follow-up is essential to achieve successful clinical results. Chen et al. (34) suggested a minimum follow-up of 6 months. Chueh et al. (35) reported that, within a period of 10 to 13 months, complete root development was achieved in immature permanent teeth with necrotic pulps. In the case reported here, the patient was followed up at 14 months and at 21 months. In the last follow-up visit, completion of root development was observed, including apical closure of both teeth, in addition to resolution of symptoms and a positive response to pulp vitality test.

## Conclusion

Based on what has been reported here, in cases of necrotic immature permanent teeth treated with regenerative endodontic procedures, pulp revascularization proved to be effective with both intracanal medicaments used, promoting symptom resolution and the completion of root development, including apical closure, even in the absence of a well-defined clinical protocol.

## Clinical Relevance

This case report shows two regenerative endodontic therapy in the same patient with two different intracanal medicaments used.

## Conflict of Interest

The authors deny any conflicts of interest related to this study.

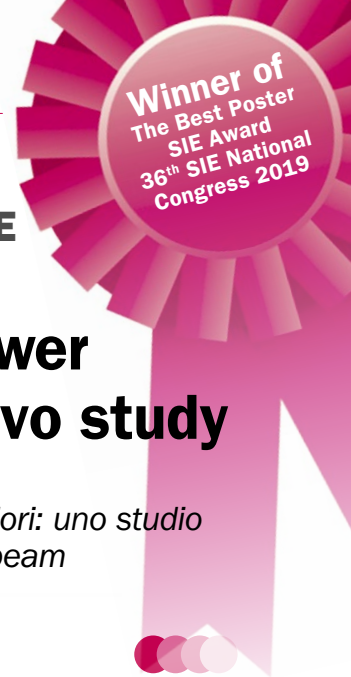## Acknowledgements

Special thanks to the University of Fortaleza and the Federal University of Pelotas for their continued support.

## References

- Hachmeister DR, Schindler W, Walker WA, Thomas DD. The sealing ability and retention characteristics of mineral trioxide aggregate in a model of apexification. *Journal of Endodontics*. 2002. 28(5):386-390.
- Pace R, Giuliani V, Pini Prato L, Bacetti T, Pagavino G. Apical plug technique using mineral trioxide aggregate: results from a case series. *Int Endod J*. 2007. 40(6):478-484.
- Rafter M. Apexification: a review. 2005 *Dental Traumatol*. 21(1):1-8.
- Andreasen J, Farik B, Munksgaards E. Long term calcium hydroxide as a root canal dressing may increase risk of root fracture. *Dental Traumatol*. 2002. 18(3):134-137.
- Wintherspoon D, Small J, Regan J, Numn M. Retrospective analysis of open apex teeth obturated with mineral trioxide aggregate. *Journal of Endodontics*. 2008. 34(10):1171-1176.
- Norsat A, Seifi A, Asgary, S. Regenerative endodontic treatment (revascularization) for necrotic immature permanent molars: a review and report of two cases with a new biomaterial. *Journal of Endodontics*. 2011. 37(4):562-567.
- Prirokh M, Torabinejad M. Mineral trioxide aggregate: a comprehensive literature review - Part III: Clinical applications, drawbacks, and mechanism of action. *Journal of Endodontics*. 2010. 36(3):400-13.
- Lovelace TW, Henry MA, Hargreaves KM, Diogenes A. Evaluation of the delivery of mesenchymal stem cells into the root canal space of necrotic immature teeth after clinical regenerative endodontic procedure. *J Endod*. 2011. 37(2):133-8.
- Fouad AF. The microbial challenge to pulp regeneration. *Advances in Dental Research*, v. 23, n. 3, p. 285-289, July 2011.
- Verma P et al. Effect of Residual Bacteria on the Outcome of Pulp Regeneration In Vivo. *Journal of Dental Research*. 2017, v. 96, n. 1, p. 100-106.
- Jacobs, JC et al. Antibacterial Effects of Antimicrobials Used in Regenerative Endodontics against Biofilm Bacteria Obtained from Mature and Immature Teeth with Necrotic Pulp. *Journal of Endodontics*. 2017, v. 43, n. 4, p. 575-579.
- Law AS. Consideration for Regenerative Procedures. *Journal of Endodontics*. 2016, v. 39, n. 3, p. 44-56.
- Bystrom A, Claesson R, Sundqvist G. The antibacterial effect of camphorated paramonochlorophenol, camphorated phenol and calcium hydroxide in the treatment of infected root canals. *Endodontics & Dental Traumatology*. 1985, v. 1. n. 5, p. 170-175.
- Kantaoutra PN. BCOR mutations and unstoppable root growth: a commentary on oculofaciocardiodental syndrome: novel BCOR mutations and expression in dental cells. *Journal of Human Genetics*. 2014, v. 59, n. 6, p. 297-299.
- Hoshino E. et al. In-vitro antibacterial susceptibility of bacteria taken from infected root dentine to a mixture of ciprofloxacin, metronidazole and minocycline. *International Endodontic Journal*. 1996, 29, n. 2, p. 125-130.
- Ruparel NB. et al. Direct effect of intracanal medicaments on survival of stem cells of the apical papilla. *Journal of Endodontics*. 2012, v. 38, n. 10, p. 1372-1375.
- Kim JH et al. Tooth discoloration of immature permanent incisor associated with triple antibiotic therapy: a case report. *Journal of Endodontics*. 2010, v. 36, n. 6, p. 1086-1091.
- Petrino JA et al. Challenges in regenerative endodontics: a case series. *Journal of Endodontics*. 2010, v. 36, n. 3, p. 536-541.
- Dabbagh B. et al. Clinical complications in the revascularization of immature necrotic permanent teeth. *Pediatric Dentistry*. 2012, v. 34, n. 5, p. 414-417.
- Grottkau BE, Purudappa PP, Lin YF. Multilineage differentiation of dental pulp stem cells from green fluorescent protein transgenic mice. *International Journal of Oral Science*. 2010, v. 2, n. 1, p. 21-27.
- Jung LY, Lee SJ, Hargreaves KM. Biologically base treatment of immature teeth with pulpal necrosis: a case series. *Journal of Endodontics*. 2008. 34(7):876-887.
- Alcade MP, Guimaraes BM, Fernandes SL, Silva PAA, Bramante CM, Vivian RR. et al. Revascularização pulpar: considerações técnicas e implicações clínicas. *Salusvita*. 2014. 33(3):415-432.
- Maniglia-Ferreira C, Gomes FA, Vitoriano MM. Intentional Replantation of an Avulsed Immature Permanent Incisor: A Case Report. *Journal of Endodontics*. 2017. 43(8):1383-1386.
- agata JY, Gomes BP, Rocha Lima TF, Murakami LS, De Farias DE, Campos GR. et al. Traumatized immature teeth treated with 2 protocols of pulp revascularization. *Journal of Endodontics*. 2014. 40(5):606-612.
- Reynolds K, Johnson J, Cohenca N. Pulp revascularization of necrotic bilateral bicuspids using a modified novel technique to eliminate potential coronal discoloration: a case report. *International Endodontic Journal*. 2009. 42(1):84-92.
- Shin SY, Albert JS, Mortan RE. One step pulp revascularization treatment of a immature permanent tooth with chronic apical abscess: a case report. *Int Endod J*. 2009. 42(12):1118-1126.
- Galler KM, D'Souza RN, Federlin M, Cavander A., Hartgerink JD, Hecker S. Dentin conditioning codetermines cell fate in regenerative endodontics. *Journal of Endodontics*. 2011. 37(11):1536-1541.
- Trevino EG, Patwarhand AN, Henry MA. Effect of irrigants on the survival of human stem cells of the apical papilla in a platelet-rich plasma scaffold in human roots tips. *Journal of Endodontics*. 2011. 37(8):1109-1115.
- Soares AJ, Lins FF, Nagat JY, Gomes BPFA, Zaia AA, Ferraz CC, Almeida JFA, DE Souza-Filho FJ. Pulp revascularization after root canal decontamination with calcium hydroxide and 2% chlorhexidine gel. *J Endod* 2013;39:417-420.
- Dhillon H, Kaushik M, Sharma R. Regenerative endodontics - Creating new horizons. *J Biomed Mater Res B Appl Biomater*. 2016. 104(4):676-685.
- Ding R, Cheung J, Yin X, Wang Q, Zhang C. Pulp revascularization of immature teeth with apical periodontitis: a clinical study. *Journal of Endodontics*. 2009. 35(5):745-749.
- Bansal R. Regenerative endodontics: a state of the art. *Indian J Dent Res*. 2011. 22(1):122-131.
- Souza-Filho FJ. Tratamento dos dentes com rizogênese incompleta: revitalização ou apicificação. *Endodontia passo a passo: evidências clínicas*. São Paulo Artes Médicas; 2015, p.166-175.
- Chen MY, Chen KL, Chen CA, Tayebaty F, Rosenberg PA, Lin LM. Responses of immature permanent teeth with infected necrotic pulp tissue and apical periodontitis/abscess to revascularization procedures. *Int Endod J*. 2012. 45(3):294-305.
- Chueh LH, Ho YC, Kuo TC, Lai WH, Chen YH, Chiang CP. Regenerative endodontic treatment for necrotic immature permanent teeth. *Journal of Endodontics*. 2009. 35(2):160-16.





## ORIGINAL ARTICLE/ARTICOLO ORIGINALE

# Root canal morphology of lower lateral incisors: a CBCT in vivo study

Morfologia del sistema endodontico negli incisivi inferiori: uno studio in vivo attraverso la tomografia computerizzata cone beam

**KEYWORDS**

CBCT, Lower Incisor, Endodontic Anatomy

**PAROLE CHIAVE**

CBCT, incisivi inferiori, morfologia endodontica

**Abstract**

**Aim:** The aim of this study was to analyze the root canal configuration in mandibular central and lateral incisors in vivo using cone-beam computed tomography (CBCT) imaging in a European population.

**Methodology:** A total of 500 mandibular lateral incisors from 250 patients were examined using CBCT imaging, previously taken for diagnosis and treatment. The number of roots, root canal system configuration, presence of apical confluences, distance between confluences and radiographic root end, symmetry between left and right elements were recorded and statistically analyzed.

**Results:** All the examined teeth presented only one root.

**Conclusions:** The percentage of Vertucci type II configuration was higher than expected, being more frequent than type III. Other configurations were present but rare.

**Obiettivo:** lo scopo del presente studio è analizzare la morfologia endodontica degli incisivi laterali inferiori utilizzando la tomografia computerizzata cone beam (CBCT).

**Metodologia:** sono stati presi in esame 500 incisivi inferiori provenienti dalle scansioni CBCT di 250 pazienti, precedentemente effettuate per motivazioni diagnostiche e di trattamento. Sono stati esaminati i seguenti parametri: numero di radici, configurazione del sistema endodontico, presenza di confluenze apicali, distanza tra le confluenze e apice radiografico, simmetria tra gli elementi sinistro e destro nello stesso individuo; i risultati così ottenuti sono stati analizzati statisticamente.

**Risultati:** tutti gli elementi dentari esaminati presentavano una sola radice, mentre la configurazione dei canali radicolari risultava variabile.

**Conclusioni:** la percentuale di riscontro di configurazioni endodontiche complesse è risultata maggiore del previsto, presentandosi più frequentemente come tipo II di Vertucci; sono inoltre presenti altre configurazioni complesse, quali tipo III e tipo VII di Vertucci.

Linda Quero<sup>1\*</sup>

Giovanni Schianchi<sup>1</sup>

Federico Valenti Obino<sup>1</sup>

Massimo Galli<sup>1</sup>

Luca Testarelli<sup>1</sup>

Gianluca Gambarini<sup>1</sup>

<sup>1</sup>La Sapienza University of Rome, Italy

Received 2019, December 28

Accepted, 2020, February 26

**Introduction**

The study of the anatomy is very important in endodontics, since most of the errors that occur during an endodontic treatment are related to failure to respect the canal anatomy (1); the existence of an untreated canal may be a reason to fail (2, 3). The study of endodontic anat-

omy can be divided into ex vivo methods, performed on extracted teeth, and in vivo methods, performed on patients (4).

Multiple methods having been used (6), including canal staining and clearing techniques (5, 6), dentin troughing under magnification (7), scanning electron microscope (8, 9), micro-computed tomography (micro CT) (10, 11), magnetic resonance (12), ultrasonics (13), serial cross-sectioning

**Corresponding author**

Linda Quero | Department of Oral and Maxillo-Facial Sciences, Sapienza University of Rome | Italy  
Tel. 0039 3279193209 | [lindaquero94@gmail.com](mailto:lindaquero94@gmail.com)

Peer review under responsibility of Società Italiana di Endodonzia

[10.32067/GIE.2020.34.01.14](https://doi.org/10.32067/GIE.2020.34.01.14)

Società Italiana di Endodonzia. Production and hosting by Ariesdue. This is an open access article under the CC BY-NC-ND license (<http://creativecommons.org/licenses/by-nc-nd/4.0/>).

(14, 15), radiographic examination (16, 17) and CBCT (cone beam computer tomography) (18-22).

In research studies CBCT is usually associated with a larger number of samples, because it does not need extractions; moreover it defines precisely the position of the tooth and allow studies about symmetry. In clinical practice the use of CBCT overcomes the limitations of conventional radiography, allowing visualization in 3D and reducing the superimposition of the surrounding structures (23-43).

Tooth configurations are usually classified according to Vertucci and the great majority of studies used this classification; more recently Ahmed and Dummer (44) proposed a new classification. It is a more accurate method, based on in vitro microCT (45) evaluations of extracted teeth. Therefore it requires higher resolution of images which is not always achievable by in vivo CBCT to avoid unnecessary high radiation doses to the patient.

## Materials and Methods

### Sample selection

A total of 500 mandibular lateral incisors selected from the CBCT examinations of 250 patients (130 males and 120 females) with an age ranging between 18 and 79 years were examined.

Images were obtained from CBCT examinations as part of diagnosis and treatment planning of patients who required large field of view for reasons including facial trauma or maxillary sinusitis, preoperative assessment for multiple implants, orthodontic treatment because of impacted teeth and for endodontic reasons. Ethical Committee was used for all the individual participants included in the study: the research was approved by the Ethics Committee of Sapienza, University of Rome (ref. 582/17).

The samples were selected according to the following criteria:

- available CBCT images of lower incisors with complete root formation;
- absence of root canal treatment;
- high-quality images of CBCT.

Teeth with immature apices and root resorption were excluded.

### Image acquisition

The CBCT images had been taken using the GXDP-500 system (Gendex Dental, Biberach, Germany), operating at 90 kVp and 7 mA, with an exposure time of 23 s and a voxel size of 0.2 mm<sup>3</sup>, with a field of view of 13, 9, 13 cm, with an estimated dose of about 50 mSv, allowing measurements to an accuracy of 0.2 mm.

### Image evaluation

Through the use of Horos™ software (The Horos Project, 64-bit medical image viewer, GNU Lesser General Public Licence, version 3.0) three-dimensional reconstructions were analyzed to evaluate the parameters of interest.

The images were reworked according to the axial, sagittal, and coronal planes.

CBCT images were viewed on reconstructions according to the axial plane, scrolling the cursor in the coronal-apical direction before, and then in the apical-coronal, to get a detailed view of the root canal system of examined teeth. This action was repeated three times, and when the images in the axial plane were not clear, the teeth were also inspected in three-dimensional.

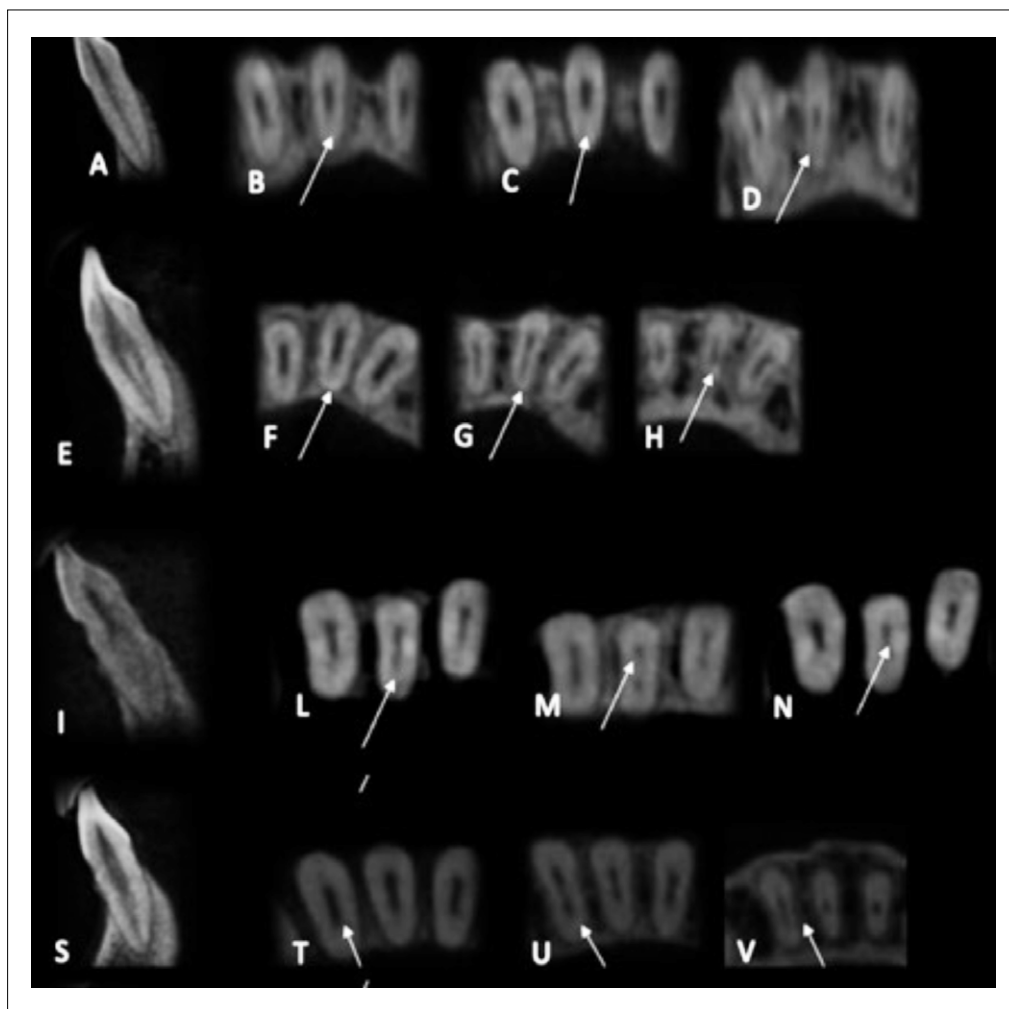
The following parameters were evaluated:

- number of roots;
- root canal system configuration (using as a reference Vertucci classification);
- presence of apical confluences;
- distance between confluences and radiographic root end;
- symmetry between left and right elements in the same individual.

The classification of the canal morphology was done according to the Vertucci's criteria:

- Type I: single canal from the pulp chamber to the apex;
- Type II: two different canals emerge from the pulp chamber but converge to the apex;
- Type III: a canal emerges from the pulp chamber, divides into two within the root and emerges into one at the apex;
- Type VII: one canal in the pulp chamber that divides and rejoins within the root, and redivides into two canals at the apex.

**Figure 1**  
Sagittal plane of CBCT scanning Type I (**A**), Type II (**E**), Type III (**I**), Type VII (**S**). Axial plane of CBCT scanning in the coronal, middle, and apical thirds of the root displayed variations in canal morphology: (**B-D**) Type I, (**F-H**) Type II, (**L-N**) Type III, (**T-V**) Type VII.



### Statistical Analysis

The results were analysed statistically using SPSS 20.0 (SPSS, Inc., Chicago, IL, USA) with the significance set at  $P < 0.05$ . One-way ANOVA was used for the association between the variables along with the post hoc tests, Tukey's HSD and Games-Howell. The t-test was used to compare the means of canal length and distance from confluence to apical foramen.

### Results

Number of roots and canal system configuration according to Vertucci:

- all examined teeth presented only one root,
- for mandibular lateral incisors type I Vertucci configuration was present in

53% of cases, type II Vertucci configuration in 30% of cases, type III Vertucci configuration in 15% of cases, type VII Vertucci configuration in 2% of cases.

Apical confluences were present in all the incisors with a type II, type III and type VII Vertucci configuration; overall were present in 47% of examined cases.

The average distance between confluences and radiographic root end was 3,102 mm in type II Vertucci configuration and 3,234 mm in type III Vertucci configuration, and 2,802 mm in type VII Vertucci configuration.

Symmetry of root canal morphology between left and right in the same individual was found in 86% of cases.



**Table 1**

**Prevalence of the Number of Root Canals in Mandibular Lateral Incisors**

Tooth	1 canal (%)	2 canals (%)	Total
Mandibular lateral incisors	265 (53,0)	235 (47,0)	500

**Table 2**

**Distribution of Root Canal Types according to Vertucci Classification in Mandibular Lateral Incisors**

Tooth	Type I	Type II	Type III	Type VII	Total
Mandibular lateral incisors, n (%)	265 (53,0)	150 (30,0)	75 (15,0)	10 (2,0)	500 (100)

### Discussion

Our results showed a high prevalence of type II configuration in mandibular lateral incisors. More precisely type II configuration was found in 30% of the teeth examined. This result was in agreement with the study by Benjamin and Dawson (23). On the contrary, the majority of studies (24-33, 40) performed on the mandibular lateral incisors, showed a significantly lower prevalence, ranging from 1% to 26,9%.

Type I Vertucci configuration was present in 53% of mandibular lateral incisors, lower when compared to the majority studies (23-28, 36-42), in accordance with Kartal et al (31), and superior to Sert et al (29). The total range was from 89,4% to 36,8%.

Type III Vertucci configuration was found 15% in mandibular lateral incisors. These findings were different from the majorities of previous researches (23-33), which showed an average percentage ranging from 0% to 27%.

Type VII Vertucci configuration was found in 2% of mandibular lateral incisors; interestingly, only the research by Han et al (32) ever showed this configuration (0,08% in mandibular lateral incisors).

The mean distance between confluences in type II mandibular lateral incisors was 3,102 mm (ranging from 1,442 mm to 6,432 mm). Similarly, in type III configuration in mandibular lateral incisors was 3,234 mm (ranging from 1,429 mm to 6,231 mm). These results were in accordance with a previous study (43) performed on confluences in molars, and significantly lower than the research of Han et al (32), performed on mandibular incisors, who reported that distribution was concentrated in the 6-12 mm range. The mean distance in type VII was 2,802 mm (ranging from 2,648 mm to 3,014 mm) in lateral incisors. Concerning with the symmetry between right and left in the same individual, we found the percentage of 86% in mandibular lateral incisors; our results were similar with the research by Kayaoglu et al (41) and lower than other studies performed on molars (43).

### Conclusions

Some of the findings from the present study can be clinically relevant. The percentage of mandibular incisors presenting a complex anatomy (two canals with different config-



urations) is higher than previously reported. Type VII Vertucci configuration was clearly found before only in a single study.

No study previously reported the localization of confluences in lower incisors. They are mostly found in the apical third, 3-4 mm shorter than radiographic root end.

The contralateral teeth usually showed a high percentage of similar anatomy: symmetry between right and left in the same individual was found in 86% of cases.

These results highlighted the need for accurate preoperative radiographic exams to identify canal configuration: multiple radiographs with different angles or CBCT.

### Clinical Relevance

Complex endodontic anatomies can be identified only with preoperative radiographic exam.

### Conflict of Interest

The authors declares that there is no conflict of interest.

### Acknowledgements

No acknowledgements.

## References

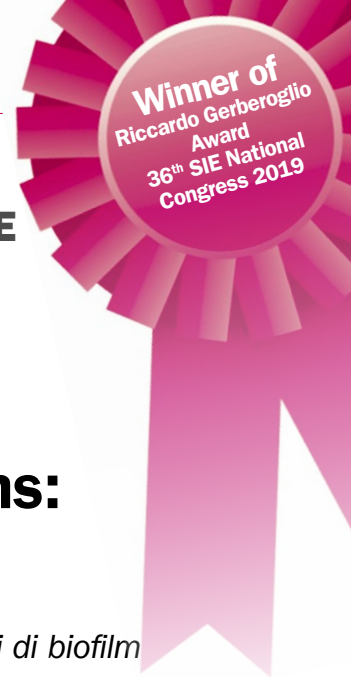1. Perlea P, Nistor CC, Toma C, Dimitriu B. Endodontic configuration of the lower incisors in a Romanian population: a radiological study. *Rom J Morphol Embryol*. 2013;54:775-8.
2. Vertucci FJ. Root canal morphology and its relationship to endodontic procedures. *Endod Top*. 2005;10:3-29.
3. Saati S, Shokri A, Forozaandeh M, et al. Root morphology and number of canals in mandibular central and lateral incisors using cone beam computed tomography. *Braz Dent J*. 2018;29:239-44.
4. Gambarini G, Ropini P, Piasecki L, et al. A preliminary assessment of a new dedicated endodontic software for use with CBCT images to evaluate the canal complexity of mandibular molars. *Int Endod J* 2018;51:259-68.
5. Vertucci FJ. Root canal anatomy of the human permanent teeth. *Oral Surg Oral Med Oral Pathol*. 1984;58: 589-99.
6. Weng XL, Shi-Bin Yu SB, Zhao SL, et al. Root canal morphology of permanent maxillary teeth in the Han nationality in Chinese Guanzhong area: a new modified root canal staining technique. *J Endod* 2009;35:651-6.
7. Yoshioka T, Kikuchi I, Fukumoto Y, et al. Detection of the second mesiobuccal canal in mesiobuccal roots of maxillary molar teeth ex vivo. *Int Endod J* 2005;38:124-8.
8. Schwarze T, Baethge C, Stecher T, Geurtsen W. Identification of second canals in the mesiobuccal root of maxillary first and second molars using magnifying loupes or an operating microscope. *Aust Endod J* 2002;28:57-60.
9. Gilles J, Reader A. An SEM investigation of the mesiolingual canal in human maxillary first and second molars. *Oral Surg Oral Med Oral Pathol* 1990;70:638-43.
10. Plotino G, Grande NM, Pecci R, et al. Three-dimensional imaging using microcomputed tomography for studying tooth macromorphology. *J Am Dent Assoc* 2006;137:1555-61.
11. Somma F, Leoni D, Plotino G, et al. Root canal morphology of the mesiobuccal root of maxillary first molars: a micro computed tomographic analysis. *Int Endod J* 2009; 42:165-74.
12. Arijji Y, Arijji E, Nakashima M, Iohara K. Magnetic resonance imaging in endodontics: a literature review. *Oral Radiol*. 2018;34:10-6.
13. Alacam T, Tinaz AC, Genç O, Kayaoglu G. Second mesiobuccal canal detection in maxillary first molars using microscopy and ultrasonics. *Aust Endod J* 2008;34:106-9.
14. Kulild JC, Peters DD. Incidence and configuration of canal systems in the mesiobuccal root of maxillary first and second molars. *J Endod* 1990;16:311-7.
15. Alqedairi A, Alfawaz H, Al-Dahman Y, et al. Cone-beam computed tomographic evaluation of root canal morphology of maxillary premolars in a Saudi population. *Biomed Res Int*. 2018;2018:8170620.
16. Thompson SA, al-Omari AO, Dummer PM. Assessing the shape of root canals: an in vitro method using microradiography. *Int Endod J* 1995;28:61-7.
17. Omer OE, Al Shalabi RM, Jennings M, et al. A comparison between clearing and radiographic techniques in the study of the root-canal anatomy of maxillary first and second molars. *Int Endod J* 2004;37:291-6.
18. Scarfe WC, Levin MD, Gane D, Farman AG. Use of cone beam computed tomography in endodontics. *Int J Dent* 2009;63:4567.
19. Ji Y, Wen S, Liu S, et al. Could cone-beam computed tomography demonstrate the lateral accessory canals? *BMC Oral Health*. 2017;17:142.
20. Monsarrat P, Arcaute B, Peters OA, et al. Interrelationships in the variability of root canal anatomy among the permanent teeth: a full-mouth approach by Cone-Beam CT. *PLoS One* 2016;11:e0165329.
21. Lo Giudice R, Nicita F, Puleio F, et al. Accuracy of periapical radiography and CBCT in endodontic evaluation. *Int J Dent*. 2018;2018:2514243.
22. Gurtu A, Aggarwal A, Mohan S, et al. CBCT: a revolutionary diagnostic aid for endodontic dilemmas. *Minerva Stomatol*. 2014 Sep;63:325-31.
23. Benjamin KA, Dowson J. Incidence of two root canals in human mandibular incisor teeth. *Oral Surg Oral Med Oral Pathol* 1974;38:122-6.
24. Madeira MC, Hetem S. Incidence of bifurcations in mandibular



## References

- incisors. *Oral Surg Oral Med Oral Pathol* 1973;36:589-91.
25. Vertucci FJ. Root canal anatomy of the mandibular anterior teeth. *J Am Dent Assoc* 1974;89:369-71.
  26. Caliskan MK, Pehlivan Y, Sepetcioglu F, et al. Root canal morphology of human permanent teeth in a Turkish population. *J Endod* 1995;21:200-4.
  27. Miyashita M, Kasahara E, Yasuda E, et al. Root canal system of the mandibular incisor. *J Endod* 1997;23:479-84.
  28. Al-Qudah AA, Awawdeh LA. Root canal morphology of mandibular incisors in a Jordanian population. *Int Endod J* 2006;39:837-7.
  29. Sert S, Aslanalp V, Tanalp J. Investigation of the root canal configurations of mandibular permanent teeth in the Turkish population. *Int Endod J* 2004;37:494-9.
  30. Rahimi S, Milani AS, Shahi S, et al. Prevalence of two root canals in human mandibular anterior teeth in an Iranian population. *Indian J Dent Res* 2013;24:234-6.
  31. Kartal N, Yanikoglu FC. Root canal morphology of mandibular incisors. *J Endod* 1992;18:562-4.
  32. Han T, Ma Y, Yang L, Chen X, Zhang X, Wang Y. A study of the root canal morphology of mandibular anterior teeth using CBCT in a Chinese subpopulation. *J Endod*. 2014;40: 1309-14.
  33. Liu J, Luo J, Dou L, et al. CBCT study of root and canal morphology of permanent mandibular incisors in a Chinese population. *Acta Odontol Scand* 2014;72:26-30.
  34. Kamtane S, Ghodke M. Morphology of mandibular incisors: a study on CBCT. *Pol J Radiol*. 2016 Jan 13;81:15-6.
  35. Lin Z, Hu Q, Wang T, et al. Use of CBCT to investigate the root canal morphology of mandibular incisors. *Surg Radiol Anat*. 2014;36:877-82.
  36. Altunsoy M, Ok E, Nur BG, et al. A cone-beam computed tomography study of the root canal morphology of anterior teeth in a Turkish population. *Eur J Dent*. 2014;8:302-6.
  37. Aminsobhani M, Sadegh M, Meraji N, et al. Evaluation of the root and canal morphology of mandibular permanent anterior teeth in an Iranian population by cone-beam computed tomography. *J Dent (Tehran)*. 2013 May;10:358-66.
  38. Verma GR, Bhadage C, Bhoosreddy AR, et al. Cone beam computed tomography study of root canal morphology of permanent mandibular incisors in Indian subpopulation. *Pol J Radiol*. 2017;82:371-75.
  39. Haghanifar S, Moudi E, Bijani A, Ghanbarabadi MK. Morphologic assessment of mandibular anterior teeth root canal using CBCT. *Acta Med Acad*. 2017;46:85-93.
  40. Zhengyan Y, Keke L, Fei W, et al. Cone-beam computed tomography study of the root and canal morphology of mandibular permanent anterior teeth in a Chongqing population. *Ther Clin Risk Manag*. 2015;12:19-25.
  41. Kayaoglu G, Peker I, Gumusok M, et al. Root and canal symmetry in the mandibular anterior teeth of patients attending a dental clinic: CBCT study. *Braz Oral Res*. 2015;29.
  42. Zhao Y, Dong YT, Wang XY, et al. Cone-beam computed tomography analysis of root canal configuration of 4 674 mandibular anterior teeth]. *Beijing Da Xue Xue Bao Yi Xue Ban*. 2014;46:95-9.
  43. Gambarini G, Piasecki L, Ropini P, et al. CBCT analysis on root and canal morphology of mandibular first permanent molar among multiracial population in Western European population. *Eur J Dent*. 2018;12:434-38.
  44. Ahmed HMA, Dummer PMH. A new system for classifying tooth, root and canal anomalies. *Int Endod J*. 2018; 51:389-404.
  45. Spagnuolo G, Ametrano G, D'Antò V, et al. Microcomputed tomography analysis of mesiobuccal orifices and major apical foramen in first maxillary molars. *Open Dent J*. 2012;6:118-25.





## ORIGINAL ARTICLE/ARTICOLO ORIGINALE

# Antibacterial effects of two synthetic peptides against *Enterococcus faecalis* biofilms: a preliminary *in vitro* study

**KEYWORDS**

Antimicrobial peptides, Biofilms, Confocal laser scanner microscopy, *Enterococcus faecalis*

**PAROLE CHIAVE**

Peptidi antimicrobici, Biofilm, Microscopia a scansione laser, *Enterococcus faecalis*

Giovanni Mergoni<sup>1\*</sup>  
Maddalena Manfredi<sup>1</sup>  
Pio Bertani<sup>1</sup>  
Tecla Ciociola<sup>2</sup>  
Stefania Conti<sup>2</sup>  
Laura Giovati<sup>2</sup>

<sup>1</sup>Department of Medicine & Surgery, Dentistry Center, University of Parma, Parma, Italy

<sup>2</sup>Department of Medicine & Surgery, Laboratory of Microbiology & Virology, University of Parma, Parma, Italy

Received 2020, January 31

Accepted 2020, February 25

*Effetti antibatterici di due peptidi sintetici nei confronti di biofilm di Enterococcus faecalis: studio preliminare in vitro*

**Abstract**

**Aim:** Current endodontic techniques are unable to fully eradicate intracanal bacteria. Thus, new agents that effectively eliminate endodontic pathogens are needed. The aim of this study was to assess the antibacterial properties of two synthetic peptides, namely KP and L18R, against planktonic cells and biofilms of the endodontic pathogen *Enterococcus faecalis*.

**Methodology:** KP and L18R bactericidal activity against *E. faecalis* ATCC 29212 was evaluated by colony forming unit assays and the half maximal effective concentration ( $EC_{50}$ ) was calculated. The effect of peptides on *E. faecalis* biofilm formation onto polystyrene plates was also assessed by the crystal violet assay. Confocal laser scanning microscopy (CLSM) analysis was carried out to compare the effects of KP, L18R and a  $Ca(OH)_2$  saturated solution in an *in vitro* model of dental infection consisting in 2-day-old *E. faecalis* biofilms grown on hydroxyapatite disks.

**Results:** Both KP and L18R showed strong bactericidal activity against planktonic *E. faecalis*. L18R proved to be 10-folds more effective than KP (KP and L18R  $EC_{50}$  values =  $4.520 \times 10^{-6}$  M and  $3.624 \times 10^{-7}$  M, respectively). Peptides inhibited *E. faecalis* biofilm formation in a dose-dependent manner and L18R resulted more effective

**Obiettivo:** le tecniche tradizionali di disinfezione endodontica non sono in grado di eliminare completamente i microrganismi del sistema canalare e, pertanto, si rende necessario lo sviluppo di nuovi agenti antimicrobici efficaci nei confronti dei microrganismi endodontici. Lo scopo di questo studio è la valutazione *in vitro* delle proprietà antibatteriche di due peptidi sintetici, denominati KP e L18R, nei confronti di cellule in sospensione e biofilm del patogeno endodontico *Enterococcus faecalis*.

**Materiali e metodi:** l'attività battericida di KP e L18R nei confronti di *E. faecalis* ATCC 29212 in forma planctonica è stata valutata mediante saggi convenzionali di determinazione di unità formanti colonia, stabilendo la concentrazione in grado di inibire il 50% della crescita batterica ( $EC_{50}$ ), mentre l'effetto dei peptidi sulla formazione di biofilm in piastre di polistirene è stato studiato mediante saggio con il cristal violetto. È stata condotta, inoltre, un'analisi al microscopio confocale a scansione laser (MCSL) per valutare l'azione di KP, L18R e di una soluzione satura di  $Ca(OH)_2$  in un modello *in vitro* di infezione endodontica rappresentato da biofilm di *E. faecalis* cresciuti per 2 giorni su dischetti di idrossiapatite.

**Risultati:** KP e L18R hanno mostrato un'efficace attività battericida nei confronti di *E. faecalis* allo stato planctonico e L18R si è mostrato 10 volte più efficace rispetto KP ( $EC_{50}$  =  $4,520 \times 10^{-6}$  M e  $3,624 \times 10^{-7}$  M, rispettivamente, per KP e L18R). Entrambi i peptidi hanno causato una riduzione dose-dipendente della

**Corresponding author**

Giovanni Mergoni | Department of Medicine & Surgery, Dentistry Center, University of Parma, Parma | Italy  
Tel. +39 0521 906718 | [giovanni.mergoni@unipr.it](mailto:giovanni.mergoni@unipr.it)

Peer review under responsibility of Società Italiana di Endodonzia

[10.32067/GIE.2020.34.01.15](https://doi.org/10.32067/GIE.2020.34.01.15)

Società Italiana di Endodonzia. Production and hosting by Ariesdue. This is an open access article under the CC BY-NC-ND license (<http://creativecommons.org/licenses/by-nc-nd/4.0/>).

# Abstract

than KP. CLSM images showed that  $\text{Ca}(\text{OH})_2$ , KP and L18R remarkably impaired *E. faecalis* biofilms pre-grown on hydroxyapatite.

**Conclusions:** KP and L18R effectively inhibited *E. faecalis*, both in planktonic and biofilm form. L18R demonstrated a more potent antibacterial activity than KP. These preliminary results suggest that antimicrobial peptides may represent a promising new strategy for endodontic infection control.

formazione del biofilm e L18R è risultato più efficace rispetto KP. Le immagini ottenute mediante analisi al MCSL hanno mostrato una alterazione della struttura di biofilm di *E. faecalis* pre-formato su dischetti di idrossiapatite in presenza di  $\text{Ca}(\text{OH})_2$ , KP e L18R.

**Conclusioni:** entrambi i peptidi analizzati sono in grado di inibire *E. faecalis*, sia in forma planctonica che di biofilm e L18R si è dimostrato più efficace rispetto a KP. Questi risultati preliminari suggeriscono che i peptidi antimicrobici possono rappresentare una promettente strategia per il controllo delle infezioni endodontiche.

## Introduction

Endodontic treatment aims to resolve or prevent apical periodontitis eliminating the microorganisms from the root canal system (1). Unfortunately, current antimicrobial chemo-mechanical techniques have shown several limitations in microbial eradication (2, 3) and inter-appointment intracanal medications are often necessary (4). Treatment with calcium hydroxide,  $\text{Ca}(\text{OH})_2$ , is the most widely used (5).  $\text{Ca}(\text{OH})_2$  antimicrobial properties depend on the release and diffusion of hydroxyl ions ( $\text{OH}^-$ ) that cause a strongly alkaline environment and inhibit the growth of many endodontic pathogens (6). In clinical conditions, the activity of  $\text{Ca}(\text{OH})_2$  is limited by the inherent buffering capacity of the dentine (7). *Enterococcus faecalis*, a Gram-positive facultative anaerobic species frequently found in endodontic treatment failures, showed a relative resistance to  $\text{Ca}(\text{OH})_2$  (8, 9). One of the strategies adopted by *E. faecalis* to resist to antimicrobials is the formation of biofilms on the canal surfaces, alone or in combination with other species (10). Biofilms are formed by bacterial cells grown on a solid surface and enveloped in a self-produced polysaccharide and protein extracellular matrix. Eradication of microorganisms in biofilms is much more difficult in comparison to planktonic cells. Given these considerations, the exploitation of new effective antibiofilm substances would be benefi-

cial to improve endodontic treatment success.

Antimicrobial peptides (AMPs) are a group of short, low-molecular-weight peptide sequences with a wide spectrum of antimicrobial activities (11). Their mechanism of action has not been fully elucidated, but for many of them seems to be mediated by a cell membrane damage finally leading to cell death (12). Other proposed mechanisms of killing are not related to membrane permeabilization. Some AMPs can cross the cell membrane through direct penetration or by a transporter mediated mechanism and interact with intracellular targets inducing several toxic effects, including enzyme inhibition, DNA degradation, formation of reactive oxygen species and ATP leakage (13).

AMPs could be distinguished in natural and synthetic ones. The former are produced by most living organisms, plants and animals, from mammals to insects, as a component of their innate immune system, and even bacteria and fungi. Examples of natural peptides are nisin synthesised by *Lactobacillus lactis* (14) or cathelicidin LL-37, expressed by human neutrophils and epithelial tissues (15). Beside natural AMPs, a wide library of synthetic peptides has been created in order to improve antimicrobial activities, to optimize pharmacological properties and to reduce production costs. Among synthetic peptides, two recently described AMPs, namely KP and L18R, have shown promising antimicrobial activities.



KP (killer peptide) is a decapeptide derived from a recombinant anti-idiotypic antibody, which is the internal image of a wide-spectrum antimicrobial yeast toxin (16). KP proved to be effective against protozoa, fungi, bacteria and viruses (17). L18R, derived from a gene (IGHJ2) encoding a human immunoglobulin heavy chain, displayed a strong fungicidal activity *in vitro* and *in vivo* (18). Both peptides did not show detectable toxicity to different human cells, including erythrocytes, epithelial cells and peripheral blood mononuclear cells (17-19).

The aim of this preliminary study was to assess the antibacterial properties of KP and L18R against planktonic cells and biofilms of the endodontic pathogen *E. faecalis*.

## Materials and Methods

### Peptides

KP (AKVTMTCSAS, molecular weight 998.2) and L18R (LLVLRSLGPWHPGH-CLLR, molecular weight 2068.1) were synthesised at the CRIBI Biotechnology Center (University of Padua, Italy) with the solid phase peptide synthesis method using a multiple peptide synthesiser (SyroII, MultiSynTech GmbH, Witten, Germany). Then, the peptides were solubilised in dimethylsulphoxide at a concentration of 20 mg/ml. For the experiments, KP and L18R were diluted in sterile distilled water to the suitable concentrations.

### Bactericidal activity against planktonic *E. faecalis* cells

The reference *E. faecalis* ATCC 29212 strain was grown in Brain Heart Infusion Agar (BHA; Sigma-Aldrich, St. Louis, USA) plates and maintained by bi-weekly passages. Peptide antibacterial activity was evaluated by colony forming unit (CFU) assay, as previously described (20). Briefly, 100 µl of a suspension of *E. faecalis* ATCC 29212 at a concentration of approximately 10<sup>4</sup> cells/ml were incubated in a 96-well microplate in the absence (control) or presence of each

peptide, at decreasing concentrations. After 5 h at 37 °C, bacterial suspensions were seeded on BHA plates and colonies were counted after 24 hours of incubation at 37 °C. Killing percentage was calculated in relation to the number of colonies in controls. Three independent experiments were performed. The half maximal effective concentration (EC<sub>50</sub>) was calculated by nonlinear regression analysis using Prism 4.01 (Graph Pad software, San Diego, USA).

### Inhibition of *E. faecalis* biofilm formation on polystyrene surfaces

KP and L18R effects on early stages of *E. faecalis* ATCC 29212 biofilm formation were investigated as follows. Overnight cultures in Brain Heart Infusion Broth (BHI; Sigma-Aldrich, St. Louis, USA) supplemented with 0.25% glucose (BHIg) were diluted to 7.5×10<sup>6</sup> cells/ml in fresh medium and 200 µl of the suspension were transferred into wells of polystyrene flat-bottom 96-well plates (Corning Incorporated, New York, USA). After 90 min at 37 °C, non-adherent bacterial cells were washed off. Decreasing concentrations of peptides in 200 µl of sterile distilled water were added to the wells while controls were incubated in 200 µl of water for 5 h at 37 °C. Subsequently, the wells were washed and 200 µl/well of BHIg were added and incubated at 37 °C for 24 h.

After 48 h, biofilm mass was assessed by the crystal violet assay. The medium was removed and the wells were dried at 80 °C for 15 minutes and then stained using 200 µl/well of 0.25% crystal violet (Sigma-Aldrich, St. Louis, USA) for 15 min. Then the wells were washed three times with phosphate-buffered saline (PBS) and dried for 12 hours in a dark room. Then, 200 µl/well of 85% ethanol was added and the absorbance at 540 nm was measured using a microplate reader (Multiskan Ascent Microplate Reader, Thermo Electron, Waltham, USA). The results were expressed as percentage of biofilm mass reduction in relation to untreated controls.



### *Inhibition of E. faecalis biofilm on hydroxyapatite disks*

In order to evaluate the antibiofilm properties, an *in vitro* model of root canal infection was employed using hydroxyapatite (HA) disks. HA disks were prepared according to Lagori et al. (21). Briefly, 0.15 g of HA powder (Sigma Aldrich, St. Louis, USA) were placed in a 12.891-mm diameter mould (Specac Inc., Fort Washington, USA). HA powder was compressed using a hydraulic press (Eurocem EPI 1, Settimo Milanese, Italy) at the pressure of 50 bars. Disks were heated under vacuum at 980 °C. Sterilized HA disks were incubated with 500 µl of a  $7.5 \times 10^6$  cells/ml *E. faecalis* ATCC 29212 suspension for 48 h at 37 °C in a flat-bottom 24-well plate. After incubation, the medium was washed off and the disks were treated (500 µl/well) with a saturated solution of  $\text{Ca(OH)}_2$  endodontic dressing, KP (100 µg/ml) or L18R (50 µg/ml) for 24 h. Control samples were incubated with sterile water. The saturated solution of  $\text{Ca(OH)}_2$  was previously prepared by mixing 38 mg of Calxyl (OCO, OCO Präparate GmbH, Dirmstein, Germany) with 10 mL of sterile distilled water. The preparation was centrifuged at 3000 g and aqueous supernatant was filtered aseptically using a sterile 25 mm diameter (0.22 µm) syringe filter (Millex®, Merck Millipore, Burlington, USA).

After treatment, the disks were processed for confocal laser scanning microscopy (CLSM) by washing with sterile water and staining with 500 µl/well of a fluorescent staining solution containing 0.3% SYTO9 and 0.3% propidium iodide (LIVE/DEAD FilmTracer™ LIVE/DEAD® Biofilm Viability Kit, Invitrogen, Paisley, UK). SYTO 9 and propidium iodide selectively stain alive cells in green and dead cells in red, respectively. A LSM 510 Meta scan head integrated with the Axiovert 200 M inverted microscope (Carl Zeiss, Jena, Germany) using a 40×NA1.3 oil immersion lens was employed for observation. The excitation/emission wavelengths were 480/500 nm for SYTO 9 and

490/635 nm for propidium iodide. A stack of 80-100 slices was captured along the Z-axis of the biofilm. CLSM images were acquired and 3D reconstructed with Imaris 9.5.0 software (Bitplane AG, Zurich, Switzerland). Each experiment was performed in duplicate.

## Results

### *KP and L18R bactericidal activity against planktonic cells*


CFU assays were carried out on planktonic *E. faecalis* ATCC 29212. Both peptides showed a significant activity against the endodontic pathogen (figure 1), with  $\text{EC}_{50}$  values in the micromolar range,  $4.520 \times 10^{-6}$  M and  $3.624 \times 10^{-7}$  M for KP and L18R, respectively. Notably,  $\text{EC}_{50}$  values for L18R were approximately 10-fold lower.

### *Inhibitory effects of KP and L18R on early stages of E. faecalis biofilm development*

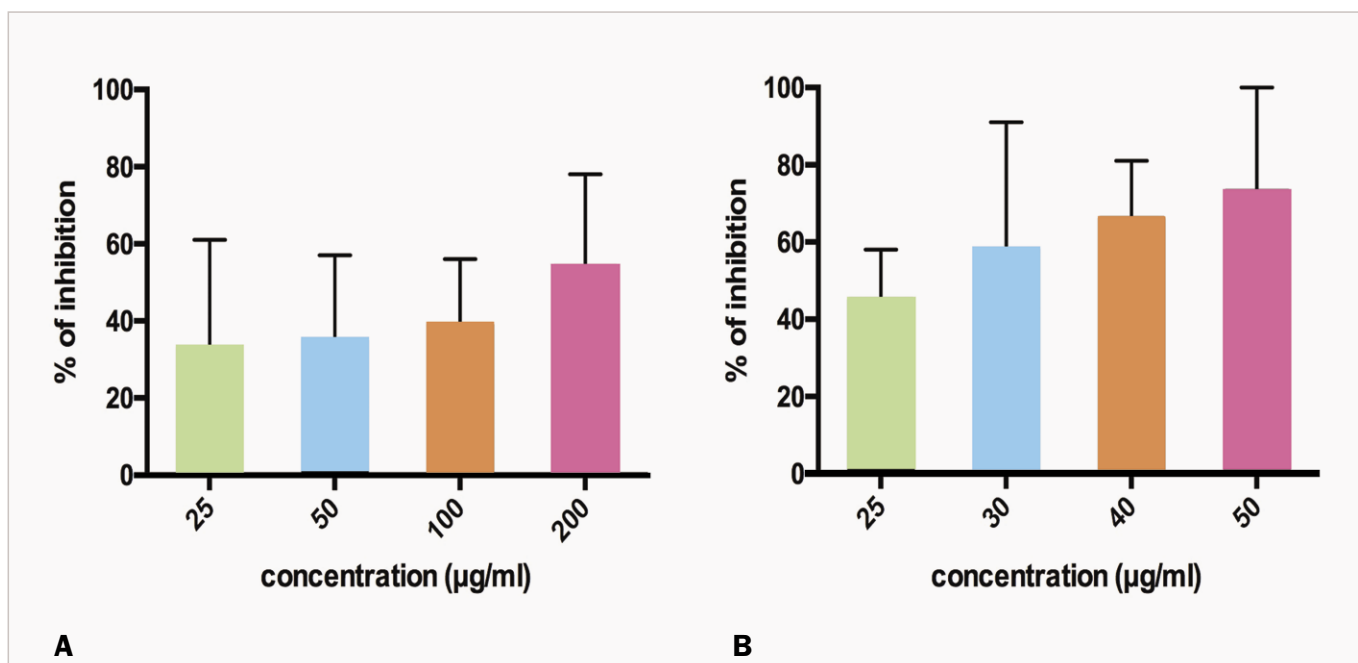
The ability of peptides to inhibit *E. faecalis* biofilm formation onto polystyrene plates was investigated by crystal violet assay. Both KP and L18R proved to notably reduce the biofilm mass in a dose-dependent manner (figure 2). In particular, KP at 50 µg/ml concentration caused 35% biofilm mass reduction. Conversely, at the same concentration, L18R determined a 73% biofilm mass reduction. As for the bactericidal activity against planktonic cells, L18R resulted more effective in biofilm inhibition in comparison to KP.

### *KP and L18R inhibition of E. faecalis biofilm on hydroxyapatite disks*

Antibiofilm properties of KP and L18R against 2 day-old *E. faecalis* ATCC 29212 biofilms grown on HA disk were assessed using CLSM in comparison with samples treated with a saturated  $\text{Ca(OH)}_2$  endodontic dressing solution. 3D CLSM image reconstructions of control samples (water incubation) showed a homogeneous and robust biofilm layer with a majority of cells alive (figure 3A). Instead, HA disks exposed to saturated  $\text{Ca(OH)}_2$  solution, KP (100 µg/ml), and L18R (50 µg/ml)

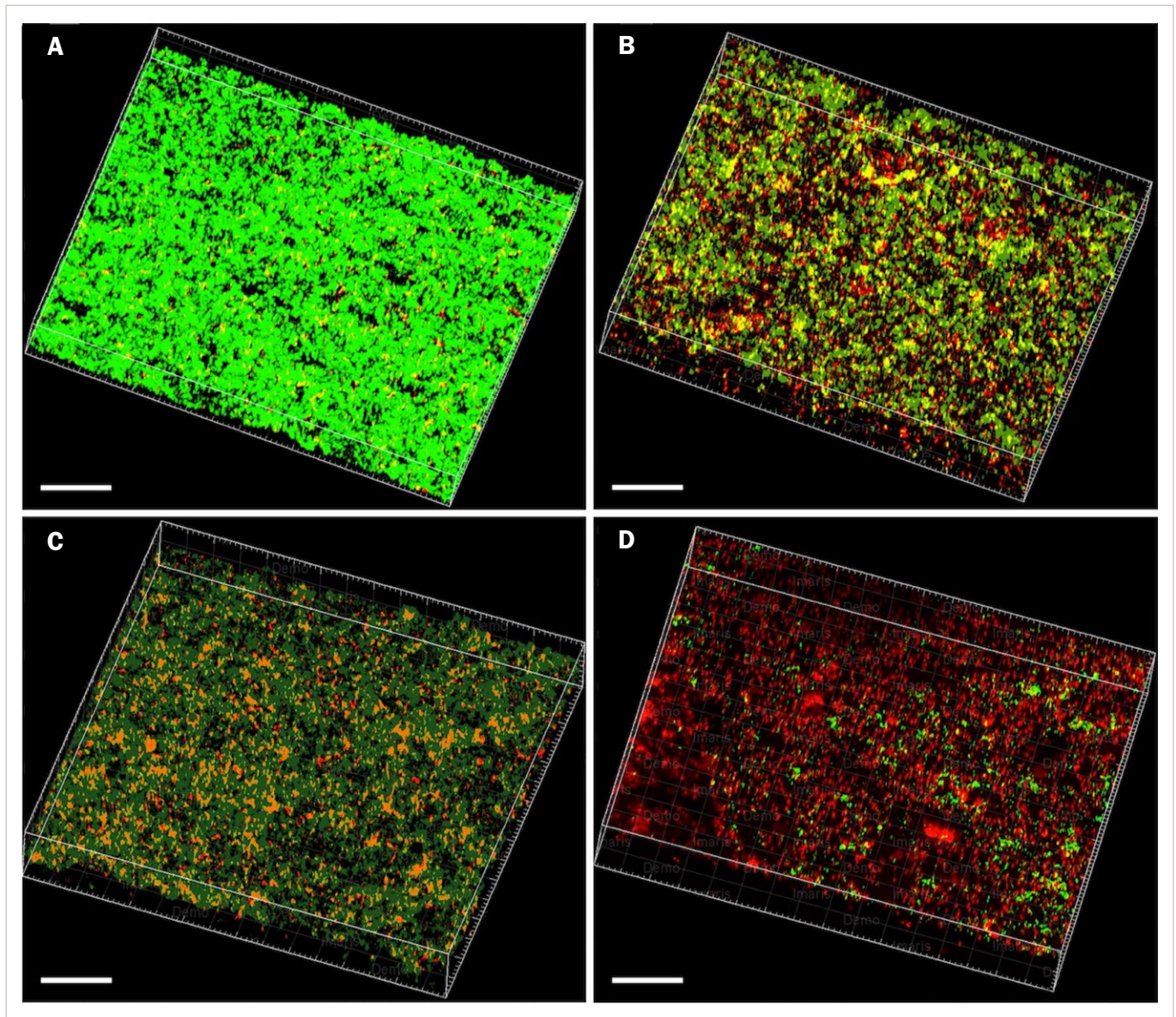
**Figure 1**

KP and L18R effects against *E. faecalis* ATCC 29212 planktonic cells determined by CFU assay. Representative plates show *E. faecalis* ATCC 29212 inhibition at different KP and L18R concentrations.

**Figure 2**

KP (A) and L18R (B) effects against *E. faecalis* ATCC 29212 biofilm. Biofilm mass was determined by crystal violet assay, comparing samples treated with different peptide concentrations to untreated samples. Data are presented as mean  $\pm$  SD of at least three independent experiments.





**Figure 3**

Representative 3D reconstruction of confocal laser scanning microscopy (CLSM) images of *E. faecalis* biofilms on HA disks. Images represent 2 day-old *E. faecalis* ATCC 29212 biofilms exposed for 24 h to H<sub>2</sub>O (control, A), Ca(OH)<sub>2</sub> saturated solution (B), 100 µg/ml KP (C) and 50 µg/ml L18R (D) and stained with SYTO9 and propidium iodide. Green, live cells; red, dead cells. Bars=50 µm.

showed an impaired biofilm layer, with a consistent number of dead cells (figure 3B-D). Overall, the qualitative analysis of the images revealed a similar effect of Ca(OH)<sub>2</sub> solution and KP treatments, while L18R appeared as the most effective in reducing both the total biomass and the viability of the biofilm.

### Discussion

The persistence of *E. faecalis* in the root canal system after conventional decontamination is considered a possible cause of endodontic treatment failure

(22). Compared to other endodontic pathogens found in infected root canals, this Gram-positive facultative anaerobic species showed some resistance to sodium hypochlorite (23), a commonly used endodontic irrigant, and proved to be less susceptible to calcium hydroxide (24, 25), which is widely employed as intracanal medication. Since *E. faecalis* ability to form biofilm on root canal surfaces contributes to its resistance, the search for new alternative antibacterial substances able to inhibit *E. faecalis* both in planktonic and biofilm form is encouraged.



The present study evaluated *in vitro* the effects of two synthetic immunoglobulin-derived peptides against *E. faecalis* ATCC 29212. The peptide L18R resulted more effective than KP against the bacterium, both in planktonic and biofilm form. In particular, the  $EC_{50}$  of L18R against planktonic cells resulted 10-fold lower as compared to KP. Moreover, L18R exhibited stronger inhibition of biofilm formation as compared to KP. The effect of both peptides were also evaluated in a model of established dental infection consisting of a 2 day-old *E. faecalis* biofilm grown on HA disks in comparison to the effect of a saturated  $Ca(OH)_2$  endodontic dressing solution.

The qualitative analysis of CLSM images demonstrated that both KP and L18R were able to impair the biofilm structure, reducing the number of attached and viable cells. The partial resistance of *E. faecalis* to  $Ca(OH)_2$ , as reported by other authors (24, 25), was confirmed. L18R was associated to the highest proportion of dead cells and to the lowest cell density compared to the other experimental groups, demonstrating a strong detaching effect of the peptide.

The mechanism of KP antibacterial activity is still not fully understood. In previous studies on yeasts, it was demonstrated that the physico-chemical properties of KP and its interaction with superficial cell-wall glucan-like structures were at the basis of the antifungal effects (17). It is possible to speculate that interactions with the surface of the bacterial cells may be involved in the antimicrobial action of the peptide. For L18R, an interaction with the cell membrane of yeasts followed by direct penetration via an energy independent pathway was hypothesised and made plausible by the hydrophobic face of the peptide (18).

As demonstrated in previous studies (17-19) an important feature of KP and L18R is the low toxicity, that could be partially explained by the cationic property of their molecules. Indeed, the peptides can easily interact with the negatively charged membranes of bacterial cells, while do not bind to the zwitterionic

membranes of mammalian cells (26). This feature may represent an important advantage over other treatments, such as  $Ca(OH)_2$ , for which a certain degree of toxicity against eukaryotic cells was demonstrated (27).

The results reported in this study are the first investigations on KP and L18R effects against an endodontic pathogen. Prior to consider the use of these peptides as a strategy for endodontic infection control, it will be necessary to evaluate the effects against other microorganisms and employ multi-species biofilm models for a better simulation of the clinical scenario.

## Conclusions

Both KP and L18R demonstrated marked inhibitory abilities against planktonic cells and biofilms of the endodontic pathogen *E. faecalis* in the experimental conditions adopted. L18R showed better performances as compared to KP and its possible role as endodontic disinfectant should be further investigated.

## Clinical Relevance

For their antibiofilm activity, AMPs may be promising agents for root canal infection control in the future.

## Conflict of Interest

The authors declare that the research was conducted in the absence of any commercial or financial relationships that could be considered as a potential conflict of interest.

## Acknowledgments

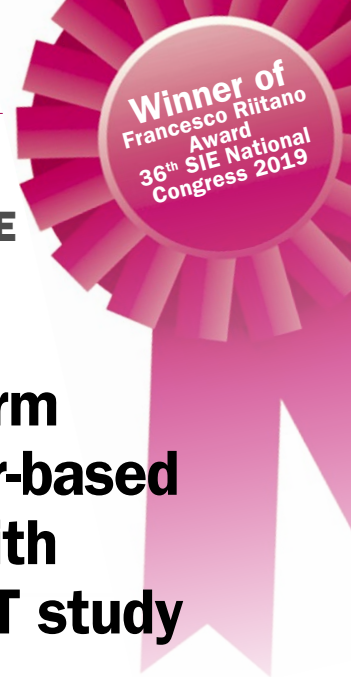We want to thank Dr. Francesca Poggia, Dr. Federica Placa and Chiara Mirabile for their support during the laboratory work and Dr. Silvana Belletti for CLSM analysis, performed in the Laboratory of Confocal Microscopy of the Department of Medicine and Surgery at the University of Parma.





## References

1. Østaviik D, Pitt Ford T. Apical periodontitis: microbial infection and host responses. In: Ørstavik D, Pitt Ford T, ed. *Essential Endodontology Prevention and Treatment of Apical Periodontitis*, (2007), 2nd edn; pp. 179–191. London, UK: Wiley-Blackwell.
2. Bystrom A, Sundqvist G. Bacteriologic evaluation of the efficacy of mechanical root canal instrumentation in endodontic therapy. *Scand J Dent Res* 1981;89:321-8.
3. Siqueira JF Jr, Machado AG, Silveira RM et al. Evaluation of the effectiveness of sodium hypochlorite used with three irrigation methods in the elimination of *Enterococcus faecalis* from the root canal, *in vitro*. *Int Endod J* 1997;30:279-82.
4. Bystrom A, Sundqvist G. The antibacterial action of sodium hypochlorite and EDTA in 60 cases of endodontic therapy. *Int Endod J* 1985;18:35-40.
5. Estrela C, Holland R. Calcium hydroxide: study based on scientific evidences. *J Appl Oral Sci* 2003;11:269-82.
6. Siqueira JF Jr, Lopes HP. Mechanisms of antimicrobial activity of calcium hydroxide: a critical review. *Int Endod J* 1999;32:361-9.
7. Wang JD, Hume WR. Diffusion of hydrogen ion and hydroxyl ion from various sources through dentine. *Int Endod J* 1988;21:17-26.
8. Siqueira JF Jr, de Uzeda M. Disinfection by calcium hydroxide pastes of dentinal tubules infected with two obligate and one facultative anaerobic bacteria. *J Endod* 1996;22:674-6.
9. Distel JW, Hatton JF, Gillespie MJ. Biofilm formation in medicated root canals. *J Endod* 2002;28:689-93.
10. Stuart CH, Schwartz SA, Beeson TJ et al. *Enterococcus faecalis*: its role in root canal treatment failure and current concepts in retreatment. *J Endod* 2006;32:93-8.
11. Marr AK, Gooderham WJ, Hancock RE. Antibacterial peptides for therapeutic use: obstacles and realistic outlook. *Curr Opin Pharmacol* 2006;6:468-72.
12. Wimley WC, Hristova K. Antimicrobial peptides: successes, challenges and unanswered questions. *J Membr Biol* 2011;239:27-34.
13. Ageitos JM, Sanchez-Perez A, Calo-Mata P et al. Antimicrobial peptides (AMPs): ancient compounds that represent novel weapons in the fight against bacteria. *Biochem Pharmacol* 2017;133:117-38.
14. Rogers LA, Whittier EO. Limiting factors in the lactic fermentation. *J Bacteriol* 1928;16:211-29.
15. Tjabringa GS, Rabe KF, Hiemstra PS. The human cathelicidin LL-37: a multifunctional peptide involved in infection and inflammation in the lung. *Pulm Pharmacol Ther* 2005;18:321-7.
16. Polonelli L, Magliani W, Ciociola T et al. From *Pichia anomala* killer toxin through killer antibodies to killer peptides for a comprehensive anti-infective strategy. *Antonie Van Leeuwenhoek* 2011;99:35-41.
17. Magliani W, Conti S, Ciociola T et al. Killer peptide: a novel paradigm of antimicrobial, antiviral and immunomodulatory auto-delivering drugs. *Future Med Chem* 2011;3:1209-31.
18. Polonelli L, Ciociola T, Sperinde M et al. Fungicidal activity of peptides encoded by immunoglobulin genes. *Sci Rep* 2017;7:10896.
19. Giovati L, Santinoli C, Mangia C et al. Novel activity of a synthetic decapeptide against *Toxoplasma gondii* tachyzoites. *Front Microbiol* 2018;9:753.
20. Ciociola T, Giovati L, Giovannelli A et al. The activity of a mammalian proline-rich peptide against Gram-negative bacteria, including drug-resistant strains, relies on a nonmembranolytic mode of action. *Infect Drug Resist* 2018;11:969-79.
21. Lagori G, Fornaini C, Rocca JP et al. Use of photo-Fenton's reaction by 400-nm LED light for endodontic disinfection: a preliminary *in vitro* study on *Enterococcus faecalis*. *J Photochem Photobiol B* 2017;171:85-9.
22. Sundqvist G, Figdor D, Persson S et al. Microbiologic analysis of teeth with failed endodontic treatment and the outcome of conservative re-treatment. *Oral Surg Oral Med Oral Pathol Oral Radiol Endod* 1998;85:86-93.
23. Rosen E, Tsesis I, Elbahary S et al. Eradication of *Enterococcus faecalis* biofilms on human dentin. *Front Microbiol* 2016;7:2055.
24. Bystrom A, Claesson R, Sundqvist G. The antibacterial effect of camphorated paramonochlorophenol, camphorated phenol and calcium hydroxide in the treatment of infected root canals. *Endod Dent Traumatol* 1985;1:170-5.
25. Orstavik D, Haapasalo M. Disinfection by endodontic irrigants and dressings of experimentally infected dentinal tubules. *Endod Dent Traumatol* 1990;6:142-9.
26. Matsuzaki K. Control of cell selectivity of antimicrobial peptides. *Biochim Biophys Acta* 2009;1788:1687-92.
27. Ehlinger C, Dartevelle P, Zaet A et al. A new combination with D-cateslytin to eradicate root canal pathogens. *Int J Pept Res Ther* 2019;25:1679-87.



## ORIGINAL ARTICLE/ARTICOLO ORIGINALE

# Evaluation of the root canal tridimensional filling with warm vertical condensation, carrier-based technique and single cone with bioceramic sealer: a micro-CT study

**KEYWORDS**

Bioceramic Sealer, Micro-CT, Root Canal Obturation, Root Canal Sealers, Volumetric Distortion

**PAROLE CHIAVE**

Cemento bioceramico, Micro-CT, Otturazione canalare, Cementi canalari, Alterazione volumetrica

*Valutazione della qualità del sigillo canalare mediante micro-CT: cono singolo con bioceramiche VS onda continua di condensazione VS guttaperca calda veicolata da carrier*

**Abstract**

**Aim:** To compare the quality of the tridimensional (3D) filling and the presence of radiographic translucencies after root canal obturation with three different techniques: warm vertical condensation, carrier-based and single cone with bioceramic sealer.

**Methodology:** Thirty single-rooted human teeth extracted for periodontal reasons were selected. Glide path was performed with ProGlider and shaping with ProTaper Next (PTN) X1, X2 and X3 up to working length (WL). The specimens were randomly divided into three groups (N=10) for the final 3D filling step: Buchanan's continuous wave of condensation (Group 1, G1), Thermafil® (Group 2, G2) or TotalFill® BC Points™ combined with TotalFill® BC Sealer (Group 3, G3).

Micro-CT scans were performed after the obturation step and the slices were 3D reconstructed with standardized parameters. Afterwards, the filled area and the associated radiographic translucencies were computer-isolated, and their volumes were calculated.

The statistical analysis was performed using one-way ANOVA and the post-hoc Student-Newmann-Keuls ( $P < 0,05$ ).

**Scopo:** questo studio si pone come obiettivo la valutazione della qualità del sigillo, mediante analisi micro-tomografica computerizzata, in termini di presenza di difetti di riempimento del sistema canalare, dell'otturazione ottenuta con tre diverse metodiche: la tecnica dell'onda continua di condensazione, della guttaperca plasticizzata veicolata da carrier e la tecnica di otturazione con cono singolo di guttaperca abbinato al sealer bioceramico.

**Materiali e metodi:** sono stati selezionati trenta elementi dentari monoradicolarati, estratti per motivi parodontali. Dopo aver eseguito l'accesso endodontico, la sagomatura è stata effettuata con sistema Protaper Next™, fino a X3, a lunghezza di lavoro (WL), irrigando con NaOCl 5% ed EDTA 10%. I campioni sono stati casualmente suddivisi in tre gruppi (N=10).

Il primo gruppo (G1) è stato otturato con la tecnica dell'onda continua di condensazione di Buchanan. Il secondo gruppo (G2) con guttaperca riscaldata veicolata da carrier (Thermafil®). Il terzo gruppo (G3) è stato infine otturato con cono singolo di guttaperca TotalFill® BC Points™ abbinato a sealer bioceramico TotalFill® BC Sealer™, secondo le specifiche della casa produttrice. Tutti i campioni sono stati analizzati tramite scansioni micro-tomografiche computerizzate (micro-CT), utilizzando parametri standardizzati. Dalle immagini ottenute sono stati calcolati tridimensionalmente i volumi dell'otturazione e delle aree di radiotrasparenza associate, tramite Materialise Mimics Medical™ e Geomagic Qualify®.

**Edoardo Moccia**<sup>1\*</sup>**Giorgia Carpegna**<sup>1</sup>**Alessandro Dell'Acqua**<sup>1</sup>**Mario Alovisi**<sup>1</sup>**Allegra Comba**<sup>1</sup>**Damiano Pasqualini**<sup>1</sup>**Elio Berutti**<sup>1</sup>

<sup>1</sup>Università degli Studi di Torino, Italy

Received 2020, February 20

Accepted 2020, March 17

**Corresponding author**

Edoardo Moccia | Università degli Studi di Torino, Dental School, Via Nizza 230, 10126 Torino | Italy  
Tel. +39 011 6331513 | edomcc@gmail.com

Peer review under responsibility of Società Italiana di Endodonzia

10.32067/GIE.2020.34.01.07

Società Italiana di Endodonzia. Production and hosting by Ariesdue. This is an open access article under the CC BY-NC-ND license (<http://creativecommons.org/licenses/by-nc-nd/4.0/>).

# Abstract

**Results:** The mean percentage of translucency areas in the warm vertical condensation group was 1,23%, whereas in the carrier-based group was 4,22% and in the single cone with bioceramic sealer group was 10,44%. The differences between the groups were statistically significant ( $P=0,029$ ).

**Conclusions:** All the obturation techniques provided an adequate 3D root canal filling. However, the null hypothesis of a superimposable 3D filling quality between groups was refused. The single cone technique with bioceramic sealer represented a viable clinical alternative, although it seemed more operator-dependent than the others.

Le analisi statistiche sono state effettuate utilizzando l'analisi one-way ANOVA ed il test post-hoc Student-Newmann-Keuls ad un livello di significatività di  $P<0,05$ .

**Risultati:** la media della percentuale delle aree di minor radiodensità nel gruppo G1 è stata 1.23%, nel gruppo G2 4.22%, nel gruppo G3 10.44%. Le differenze tra i tre gruppi si sono dimostrate statisticamente significative ( $P=0,029$ ).

**Conclusioni:** con le limitazioni di questo studio, possiamo affermare che in tutti i gruppi sia stata ottenuta un'otturazione tridimensionale soddisfacente, in linea con i dati dalla letteratura scientifica. Le tecniche dell'onda continua di condensazione e della guttaperca veicolata da carrier si sono dimostrate di maggiore predicibilità rispetto all'otturazione con sealer bioceramico. Tuttavia, quest'ultima rimane una valida alternativa in campo clinico, anche se è risultata essere ancora maggiormente operatore-dipendente.

## Introduction

During endodontic treatment, the obturation's quality is considered a main feature for a good prognosis: it aims to fill the entire root canal system and to seal it from any bacterial contamination (1). Anatomical variations such as isthmuses or bifurcations may be considered a challenge for the operator during this critical phase.

The perfect sealer and filling material have yet to be found. Its ideal characteristics have been described by Grossman in 1988 (2) and revised by Kaur in 2015 (3).

In modern endodontics, warm vertical condensation and thermo-plasticized carrier-based techniques are commonly used. Warm vertical condensation was described by Schilder in 1967 (4). In 1998, Buchanan proposed the continuous wave of condensation: it takes all the advantages of the Schilder's techniques achieving a 3D filling of the endodontic system and requiring a single heat compaction of 15 seconds (5, 6). Nowadays, thermo-plasticized carrier-based gutta-percha is taking hold solidly for its simplicity combined with high-performance (7).

Both of these techniques share the use of zinc oxide eugenol (ZOE) sealer, which is indicated as the obturation's weak link, so its volume percentage should be lower than the filling material (4, 8).

Bioceramics are a large family of root repairing cements and root canal sealers. Thanks to their high pH and ability to produce hydrated calcium silicate gel and calcium hydroxide, they have been proven highly biocompatible and nontoxic: these properties make them particularly suitable in dentistry (9, 10). One of the most well-known bioceramic-based material is mineral trioxide aggregate (MTA), a mixture of Portland cement and bismuth oxide (11). Through the years, bioceramic-based materials have been used mainly as retrograde filling materials, root repair cements or root canal sealers (12, 13, 14). Due to their capability to produce mineral tags, bioceramic sealers are supposed to bond chemically and mechanically dentinal tubules (15, 16). Nowadays, the clinical use of bioceramic-based materials endodontic sealer is widely documented (9, 17, 18). Radiopacity is an important characteristic for any filling material in order to assess the treatment's quality. Micro-computed tomography (micro-CT) is a modern highly accurate method proposed to assess the obturation quality through the three-dimensional analysis of the root canal volumes: it is widely documented as non-destructive, non-invasive, (19) repeatable and reliable, (20, 21) representing nowadays one of the best in vitro methods in the endodontics research field (22-25).

The aim of this micro-CT study is to evaluate the quality of the tridimensional fill-



ing and the presence of radiographic translucencies after the root canal obturation with three different techniques: warm vertical condensation, carrier-based technique and single cone with bioceramic sealer.

## Materials and Methods

### *Specimen selection*

For this study, intact single-rooted human teeth with closed apex, freshly extracted due to periodontal disease, were recruited and immediately stored in a NaCl 0.9% W/V solution after the extraction. Once the debridement of root's surface with a Gracey's curette was done, each tooth was restored in NaCl 0.9% W/V solution. The test tube was fixed on a customized support for low resolution scout scans (SS) (SkyScan 1172®: ©Bruker microCT, Kontich, Belgium) to obtain a general vision of the root canal system. Starting from the SS, thirty teeth with single roundish canal were selected.

### *Endodontic treatment*

After performing a minimally invasive endodontic access, the canal was scouted with a #10 k-file (Dentsply Maillefer, Ballaigues, Switzerland). Working length (WL) was assessed with a microscope (OPMI Pro Ergo®, Carl Zeiss, Oberkochen, Germany) when the instrument's tip became just visible at the apex. The glide path and the shaping were achieved respectively with ProGlider (PG) (Dentsply Maillefer, Ballaigues, Switzerland) and with ProTaper Next (PTN) (Dentsply Maillefer) X1, X2 and X3 using the X-Smart plus™ motor according the manufacturer's instruction (300 rpm, 4 Ncm), always up to WL. Each instrument was used for a maximum of 3 cycles and then discarded. The irrigation between every instrument was performed with 5% NaOCl (Nicolor 5; Ogna, Muggiò, Italy) alternated with 10% EDTA (Tubuliclean; Ogna) by using a 5 mL syringe and 30-gauge side-vented needle.

All specimens were randomly divided into three groups (N=10) for the final 3D filling step: continuous wave condensation (Group 1), carrier-based obturation (Group 2) or bioceramic sealer (Group 3).

### *Continuous wave of condensation group (G1)*

In Group 1 (G1) a dedicated gutta-percha X3 cone (Dentsply Maillefer) was selected and covered with a light coat of ZOE endodontic sealer, mixed according to manufacturer's instructions (Pulp Canal Sealer EWT; Kerr, Orange, CA). The cone was inserted up to 0.5 mm from the working length of each sample, checking the correct tug-back. An M plugger (EIE/Analytic, Redmond, WA) which penetrated within 5 mm from the working length was selected. A DownPak heat source (Hu-Friedy, Chicago, IL) heated the cone till 5 mm from working length and the plasticized gutta-percha was gently compacted with the plugger. Afterwards, backfilling step was performed with Obtura III (Analytic Technologies, Redmond, WA).

### *Carrier-based group (G2)*

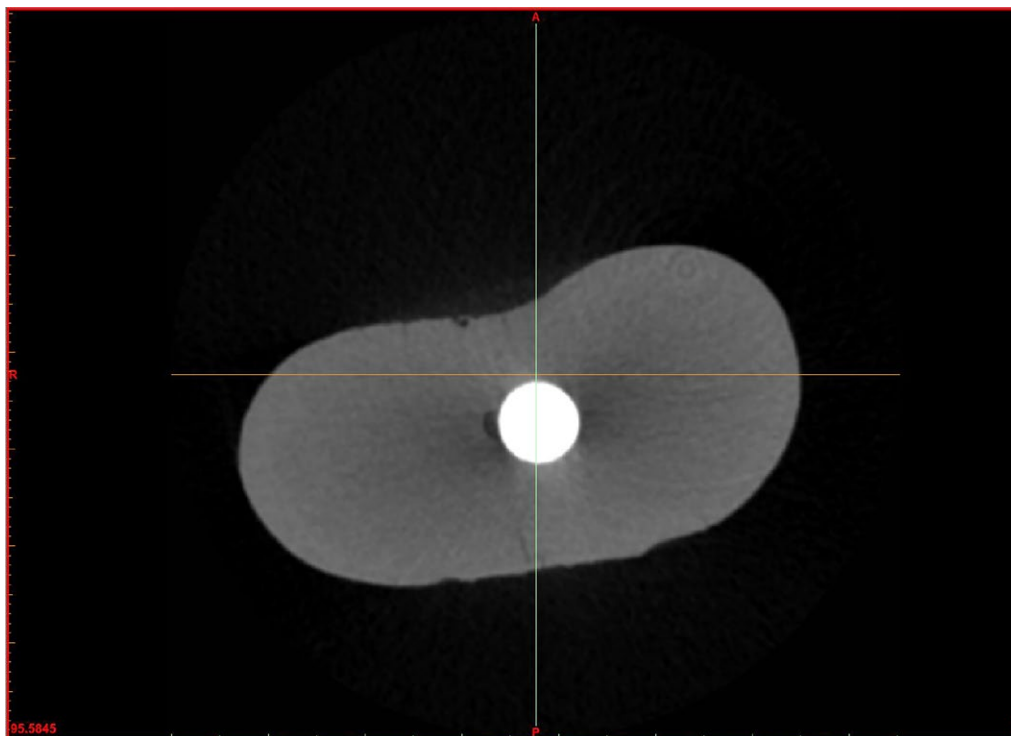
For the 3D filling step in Group 2 (G2), a small amount of ZOE endodontic sealer (Pulp Canal Sealer EWT; Kerr, Orange, CA), mixed according to manufacturer's instructions, was placed over the canal access, then a size .35 Thermafil plastic obturator (Dentsply, Tulsa Dental Products, Tulsa, OK) was heated in a Thermaprep oven (Dentsply Tulsa) for 30 seconds and inserted with firm apical pressure up to working length in the canal. The carrier was cut at the canal orifice.

### *Bioceramics group (G3)*


In Group 3 (G3) a size .30 gutta-percha cone TotalFill® BC Points™ (Brasseler U.S.A. Dental, LLC One Brasseler Boulevard Savannah, Georgia 31419, USA) was selected, in order to check its correct tug-back up to working length. A small amount of pre-mixed TotalFill® BC Sealer™ (Brasseler U.S.A. Dental, LLC One Brasseler Boulevard Savannah, Georgia 31419, USA) was placed in the canal through the intracanal tip of the pre-loaded syringe, and gently spreaded over the canal walls. The gutta-percha cone as well was covered with a light coat of sealer and finally placed in the canal up to working length. To guarantee better filling proprieties, the cone was clock-wise rotated in the final 3 mm of its insertion.



**Figure 1**  
Example of a micro-CT G2 specimen slice.



**Figure 2**  
Masks selection: green for carrier-based gutta-percha obturation and ZOE sealer; yellow for space outside the specimen; purple for intra-canal voids.



Endodontic access in all the specimens was sealed with a provisional sealer and then the teeth were stored again in a NaCl 0.9% W/V solution.

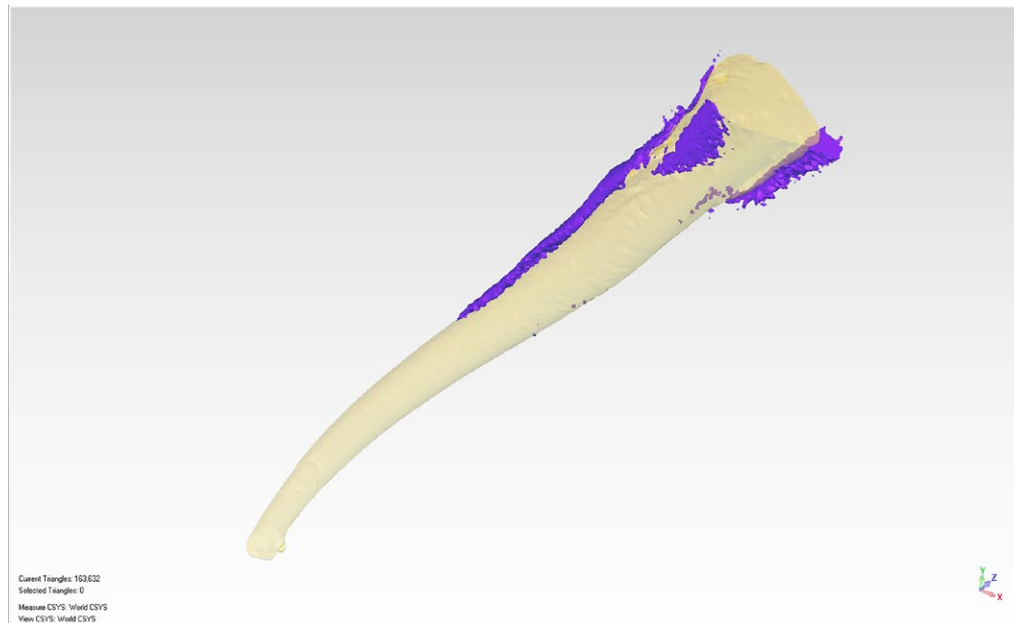
#### Micro-CT scans

Test tubes were fixed on the customized support for high resolution scans (100 kV,

100  $\mu$ A) (SkyScan 1172®: ©Bruker microCT, Kontich, Belgium), with an isotropic resolution of 12.53  $\mu$ m/pixel, in a 3 hours timeframe approximately for each specimen. Rotation step of the specimens was set at 0.4 degrees and averaging of 4 frames, through a physical 2 mm Copper and Aluminum filter. Once the scans were

**Figure 3**

The 3D rendering of the previous G2 specimen with its obturation voids: ochre for carrier-based gutta-percha and ZOE sealer; purple for intra-canal voids.



done, each acquisition was reconstructed with the software NRecon (©2012 Bruker) using standardized parameters for the whole study: 15% beam hardening; artifact correction between 4 and 8, depending on the specimen's artifact; smoothing between 3 and 5, depending on the specimen's radiodensity: Output histogram as well was standardized on the HU scale (min: 0; max: 0.064) (figure 1).

#### Digital analysis

Afterwards the software Materialise Mimics Medical™ (Materialise NV) was used for processing the reconstructed files: region of interest (ROI) was selected starting from the cement-enamel junction (CEJ) up to the root apex.

Two different masks were selected over the ROI: obturation mask (Mobt) (lower threshold=1,624; higher threshold=3,194 on the HU scale) including areas with similar radiodensity to the gutta-percha and bio-ceramic sealer; voids mask (Mvds) (lower threshold= 1,024; higher threshold=-300 in the HU scale) including areas with similar radiodensity to the space outside the tooth. After this selection, Mobt was dilated of 30 pixels, assuming that eventual obturation voids extend no more for 375,9 µm from the radicular walls.

With an intersection between dilated Mobt

and Mvds we obtained a pores mask (Mpor), as result of regions around for 0.3 mm and inside the obturation that have same radiodensity of the specimen's outside space (figure 2).

Mobt, Mvds and Mpor were exported in .stl files and rendered with the software Geomagic Qualify 12.0 (©2010 Geomagic), which also helped in the calculation (in µm<sup>3</sup>) of the obturation volume (Vobt) and pores volume (Vpor) (figure 3).

## Results

To calculate the rate of the pores in the selected areas (Rpor) the following proportion was used:

$$(Vobt + Vpor) : 100 = Vpor : Rpor$$

Table 1 shows obturation volume, pores volume and pores rate for each sample and all the three groups mean values.

The statistical analysis was performed with one-way ANOVA test and the post-hoc Student-Newmann-Keuls test (P<0,05). The mean percentage of translucency areas in G1 was 1,23%, whereas in G2 was 4,22% and in G3 was 10,44%. The differences between the three groups were statistically significant (P=0,029). The null hypothesis of a superimposable 3D filling quality between the three groups was refused.

**Table 1**

Shows obturation volume, pores volume and pores rate for each sample and groups mean values

Group	Specimen	Obturation volume ( $\mu\text{m}^3$ )	Pores volume ( $\mu\text{m}^3$ )	Pores rate (%)
<b>G1</b> (Continuous wave of condensation group)	WAV_01	13079.354794	67.012520	0.5
	WAV_02	8158.053783	19.798954	0.2
	WAV_03	6047.494961	4.322310	0.1
	WAV_04	18622.551407	107.023199	0.6
	WAV_05	9154.671449	326.944672	3.4
	WAV_06	10406.475035	44.739567	0.4
	WAV_07	7475.083765	20.232366	0.3
	WAV_08	12030.724405	691.364789	5.4
	WAV_09	6671.881436	5.616137	0.1
	WAV_10	14336.876706	195.714099	1.3
<b>G1 MEAN VALUES</b>		<b>10598.3</b>	<b>148.3</b>	<b>1.23</b>
<b>G2</b> (Carrier-based gutta-percha group)	CAR_01	10944.11089	117.166773	1.1
	CAR_02	19517.0993	109.192633	0.5
	CAR_03	10329.0327	139.868864	1.3
	CAR_04	12477.193891	2651.3298	17.5
	CAR_05	10388.39338	414.6046	3.8
	CAR_06	9497.214289	8.524728	0.08
	CAR_07	9672.531468	475.833332	4.6
	CAR_08	9790.794203	143.298172	1.4
	CAR_09	9280.845704	1096.38577	10.5
	CAR_10	10944.11089	110.191466	1.0
<b>G2 MEAN VALUES</b>		<b>11284.1</b>	<b>526.6</b>	<b>4.22</b>
<b>G3</b> (Single cone with bioceramic sealer group)	BIO_01	15161.606403	910.076029	5.7
	BIO_02	15883.825857	705.336862	4.3
	BIO_03	11490.327005	994.420567	8.0
	BIO_04	5075.217904	173.934894	3.3
	BIO_05	7810.608117	2869.873788	26.9
	BIO_06	20555.635418	2138.462997	9.4
	BIO_07	10045.453751	2149.309631	17.6
	BIO_08	15779.903813	715.423583	4.3
	BIO_09	15401.496286	2850.362639	15.6
	BIO_10	13228.770685	1363.863580	9.3
<b>G3 MEAN VALUES</b>		<b>13043.3</b>	<b>1487.1</b>	<b>10.44</b>



## Discussion

In the present study micro-CT scans were used to compare the quality of the 3D filling and the presence of radiographic translucencies of three different root canal obturation techniques: warm vertical condensation, carrier-based technique and single cone with bioceramic sealer. The same parameters among the different group were analyzed: obturation volume, pores volume and pores rate. No obturation technique showed a completely filled canal system.

The obturation techniques used during this study presented similar characteristics: they are biocompatible, radiopaque and inert, (26) offering a stable apical and intra-canal seal. The results of this study are comparable with previously published scientific data about the continuous wave of condensation and the carrier-based techniques and a good 3D filling of the root canal system was achieved (6, 27).

Both continuous wave and carrier based techniques are based on minimum sealer interface concept, while the bioceramic sealer single cone technique starts from Grossman's concept of maximum sealer interface with the gutta-percha cone intended as a carrier. This difference probably makes this obturation technique more operator-dependent compared with the other two.

Eltair et al. reported that the use of different types of gutta-percha cones compositions doesn't affect significantly the quality of the endodontic seal (28).

Micro-CT have been validated as a viable method to tridimensionally evaluate the endodontic anatomy, that instrument shaping outcomes and the obturation quality (29). Moreover, it is accurate, reproducible, repeatable and non-destructive against the specimens (30, 31). In the present study, the areas of major radiolucency isolable in our scans (Mpo) represented a lack of filling of the tested obturation material.

These areas were frequently associated with a higher physical density of the bioceramic sealer which resulted in the

formation of internal voids or in lacks of filling at the interface against the root canal walls. In conclusion, the standardization of the 3D root canal filling quality may be more operator dependent using the single cone bioceramic technique.

## Conclusions

Within the limitations of this study, all the obturation techniques provided an adequate 3D root canal filling. The single cone technique with bioceramic sealer represented a viable clinical alternative, although it seemed more operator-dependent than the continuous wave of condensation and carrier-based gutta-percha techniques.

## Clinical Relevance

3D filling is a key element for a successful endodontic treatment: continuous wave of condensation and carrier-based gutta-percha proved to be two more predictable techniques. The single cone with bioceramics, thanks to their biocompatibility properties, is a viable clinical alternative, although more operator-dependent.

## Conflict of Interest

We affirm that we have no financial affiliation (e.g. employment, direct payment, stock holdings, retainers, consultancies, patent licensing arrangements or honoraria) or involvement with any commercial organization with direct financial interest in the subject or materials discussed in this manuscript, nor have any such arrangements existed in the past three years. The Authors declare no competing conflict of interests with the materials discussed in this manuscript.

## Acknowledgements

Micro-CT scans were performed at C.I.R. Dental School (Via Nizza 230, 10100 Turin, Italy).





## References

1. Sjögren U, Figdor D, Persson S, Sundqvist G. Influence of infection at the time of root filling on the outcome of endodontic treatment of teeth with apical periodontitis. *Int Endod J* 1997; 30:297.
2. Grossman, L. *Endodontic practice* 1988; ed 11, p 242, Philadelphia, Lea & Febiger.
3. Kaur A, Shah N, Logani A, Mishra N. Biototoxicity of commonly used root canal sealers: A meta-analysis. *J Conserv Dent*. 2015; 18: 83-88.
4. Schilder H. Filling root canals in three dimensions. *Dental Clinics of North America*, 1967; 11: 723-44.
5. Buchanan LS. Continuous wave of condensation technique. *Endodontic Practice* 1998; 1:7-10, 13-6, 18 passim.
6. Buchanan LS. Endodontic Obturation Techniques. *The State of the Art in 2015. Dent Today*, 2015; 34:90, 92, 94-5.
7. Greco K., Carmignani E., Cantatore G.: The Thermafill root canal obturation system. *Giornale Italiano di Endodonzia* 2011; 25: 97-109.
8. Malagnino VA, De Luca M, Altieri P, Goracci G. L'uso del cemento nella condensazione laterale della guttaperca. *R.I.S.* 1990; 59:5.
9. Wang Z. Bioceramic materials in endodontics. *Endodontic Topics* 2015; 32: 3-30.
10. Zhang H, Shen Y, Ruse ND, Haapasalo M. Antibacterial Activity of Endodontic Sealers by Modified Direct Contact Test Against *Enterococcus faecalis*. *JOE* 2009; 35:1051-5.
11. Witte. The filling of a root canal with Portland cement. *German Quarterly for Dentistry. J Cent Assoc German Dent* 1878; 18:153-4.
12. Torabinejad M, Watson TF, Pitt Ford TR. Sealing ability of a mineral trioxide aggregate when used as a root end filling material. *J Endod* 1993; 19: 591-5.
13. Atmeh AR, Chong EZ, Richard G et al. Dentin-cement interfacial interaction: calcium silicates and polyalkenoates. *J Dent Res* 2012; 91: 454-9.
14. Koch KA, Brave DG. Bioceramics, part I: the clinician's viewpoint. *Dent Today* 2012; 31:130-5.
15. Atmeh AR, Chong EZ, Richard G et al. Dentin-cement interfacial interaction: calcium silicates and polyalkenoates. *J Dent Res*. 2012; 9:454-9.
16. Han L, Okiji T. Uptake of calcium and silicon released from calcium silicate-based endodontic materials into root canal dentine. *Int Endod J*. 2011; 44:1081-7.
17. Haapasalo M, Parhar M, Huang X et al. Clinical use of bioceramic materials. *Endodontic Topics* 2015; 32: 97-117.
18. Trope M, Bunes A, Debellian G. Root filling materials and techniques: bioceramics a new hope? *Endodontic Topics* 2015; 32, 86-9.
19. Rengo C, Goracci C, Ametrano G et al. Marginal Leakage of Class V Composite Restorations Assessed Using Microcomputed Tomography and Scanning Electron Microscope. *Oper Dent*. 2015 40:440-8.
20. Spagnuolo G, Ametrano G, D'Antò V et al. Microcomputed Tomography Analysis of Mesiobuccal Orifices and Major Apical Foramen in First Maxillary Molars. *Open Dent J*. 2012; 6, 118-25.
21. Alovisi M, Cemenasco A, Mancini L et al. Micro-CT evaluation of several glide path techniques and ProTaper Next shaping outcomes in maxillary first molar curved canals. *Int Endod J*. 2017; 50:387-97.
22. Rengo C, Spagnuolo G, Ametrano G et al. Micro-computerized tomographic analysis of premolars restored with oval and circular posts. *Clin Oral Investig*. 2014; 18:571-8
23. Pasqualini D, Alovisi M, Cemenasco A et al. Micro-Computed Tomography Evaluation of ProTaper Next and BioRace Shaping Outcomes in Maxillary First Molar Curved Canals. *J Endod*. 2015; 41:1706-10.
24. Alovisi M, Pasqualini D, Musso E. Influence of Contracted Endodontic Access on Root Canal Geometry: An In Vitro Study. *J Endod*. 2018; 44:614-620.
25. Zogheib C, Hanna M, Pasqualini D. Quantitative volumetric analysis of cross-linked gutta-percha obturators. *Ann Stomatol (Roma)* 2017; 7:46-51
26. Candeiro GTDM, Correia FC, Duarte MAH et al. Evaluation of radiopacity, pH, release of calcium ions, and flow of a bioceramic root canal sealer. *J Endod* 2012; 38:842-5.
27. Torabinejad M, Skobe Z, Trombly PL et al. Scanning electron microscopic study of root canal obturation using thermoplasticized gutta-percha. *JOE* 1978; 4:245-250.
28. Eltair M, Pitchika V, Hickel R et al. Evaluation of the interface between gutta-percha and two types of sealers using scanning electron microscopy (SEM). *Clin Oral Invest* 2018; 22:1631-9.
29. Hammad M, Qualtrough A, Silikas N. Evaluation of root canal obturation: a three-dimensional in vitro study. *J Endod* 2009; 35:541-4.
30. Metzger Z, Zary R, Cohen R et al. The quality of root canal preparation and root canal obturation in canals treated with rotary versus self-adjusting files: a three-dimensional micro-computed tomographic study. *J Endod* 2010; 36:1569-73.
31. Endal U, Shen Y, Knut Å, et al. A high-resolution computed tomographic study of changes in root canal isthmus area by instrumentation and root filling. *J Endod* 2011; 37:223-7.

## ORIGINAL ARTICLE/ARTICOLO ORIGINALE

# Diagnostic accuracy of two cone-beam computed tomography systems for detection of strip perforation in the mesial root of mandibular molars

**KEYWORDS**

Cone Beam Computer Tomography, Three Dimensional Imaging, Accuracy

**PAROLE CHIAVE**

Tomografia Computerizzata Cone Beam, Immagine 3D, Precisione

**Vida Maserat<sup>1</sup>****Heshmatallah Shahraki Ebrahimi<sup>2</sup>****Eshagh Ali Saberi<sup>3\*</sup>****Arezoo Pirhaji<sup>2</sup>****Niloofer Khosravi<sup>4</sup>**

<sup>1</sup>Department of oral and maxillofacial radiology, Faculty of Dentistry, Zahedan University of medical sciences, Zahedan, Iran

<sup>2</sup>Department of Endodontics, Faculty of Dentistry, Zahedan University of medical sciences, Zahedan, Iran

<sup>3</sup>Oral and Dental Disease Research Center, Department of Endodontics, Faculty of Dentistry, Zahedan University of medical sciences, Zahedan, Iran

<sup>4</sup>General dentist, Birjand University of Medical Sciences, Birjand, Southern Khorasan, Iran

Received 2019, August 22

Accepted 2019, January 15

*Precisione diagnostica di due sistemi di tomografia cone-beam per la rilevazione di stripping nella radice mesiale di molari mandibolari*

**Abstract**

**Aim:** This study aimed to compare the diagnostic accuracy of two cone-beam computed tomography (CBCT) systems for detection of strip perforation in the mesiobuccal canal of mandibular molars after root canal treatment.

**Methodology:** The curved mesiobuccal canals of mandibular first and second molars were instrumented as part of endodontic treatment. The canals were strip-perforated using #2 and #3 Gates-Glidden drills in distoaxial direction at 1 to 3 mm distance from the furcation. The canals were filled with gutta-percha and AH26 sealer with lateral compaction technique. The teeth were then mounted in dry bovine mandible and underwent CBCT using Acteon and NewTom CBCT systems. The CBCT scans were evaluated by two observers, and the sensitivity, specificity, positive predictive value (PPV), negative predictive value (NPV) and accuracy of the two CBCT systems for detection of strip perforation were determined and compared using the Chi-square test.

**Results:** The sensitivity and specificity for detection of strip perforation were 51.3% and 46.3% for Acteon, and 55% and 38.8% for NewTom CBCT system, respectively. The difference between the two CBCT systems for detection of strip perforation was not significant (Chi-square test,  $P > 0.05$ ).

**Conclusions:** The accuracy of Acteon and NewTom CBCT systems for detection of strip perforation is low, and no significant difference was noted between the two systems in this respect.

**Scopo:** lo studio ha lo scopo di comparare la precisione diagnostica di due sistemi di tomografia computerizzata cone-beam (CBCT) per la rilevazione di stripping nella radice mesiale di molari mandibolari dopo il trattamento canalare.

**Metodologia:** canali mesio-buccali curvi di primi e secondi molari mandibolari erano strumentati durante il trattamento endodontico. I canali erano perforati usando frese Gates-Glidden #2 e #3 in direzione disto-assiale da 1 a 3 mm di distanza dalla forcazione. I canali erano otturati con gutta-percha e cemento AH26 con tecnica di condensazione laterale. I denti erano poi montati in mandibole essiccate di bovino ed erano sottoposte a CBCT usando i sistemi Acteon e NewTom CBCT. Le scansioni CBCT sono state valutate da due osservatori e la sensibilità, la specificità, il valore predittivo positivo (PPV), il valore predittivo negativo (NPV) e l'accuratezza dei due sistemi CBCT per il rilevamento dello stripping sono stati determinati e confrontati utilizzando il test Chi-quadrato.

**Risultati:** la sensibilità e la specificità per il rilevamento dello stripping sono state rispettivamente del 51,3% e 46,3% per Acteon e 55% e 38,8% per il sistema CBCT NewTom. La differenza tra i due sistemi CBCT per il rilevamento dello stripping non era significativa (test Chi-quadrato,  $P > 0,05$ ).

**Conclusioni:** l'accuratezza dei sistemi Acteon e NewTom CBCT per il rilevamento dello stripping è bassa e non sono state rilevate differenze significative tra i due sistemi.

**Corresponding author**

Dr. Eshagh Ali Saberi | Janbazan Boulevard, 1st and 3rd Janbazan Intermediate, Unit 2, Sistan and Baluchestan, Zahedan | Iran  
Tel. +98 9151416924 | saberiendo@yahoo.com

Peer review under responsibility of Società Italiana di Endodonzia

10.32067/GIE.2020.34.01.01

Società Italiana di Endodonzia. Production and hosting by Ariesdue. This is an open access article under the CC BY-NC-ND license (<http://creativecommons.org/licenses/by-nc-nd/4.0/>).

## Introduction

**R**oot perforation is defined as a pathological and/or mechanical communication between the root canal system and the tooth supporting structures (1). Root perforation occurs in 2% to 12% of the endodontically-treated teeth (2) and is responsible for 10% of the endodontic treatment failures. It can compromise the peri-radicular tissue health and root integrity (1, 3).

Strip perforation is longitudinal perforation of the root that commonly occurs in the danger zone of the mesial root of mandibular molars due to over-instrumentation of this region (4). Several tools and techniques such as endoscopes (5), microscopes (6), electronic apex locators (7) and optical coherence tomography scan (8) have been recommended for detection of root perforation. However, none of the abovementioned diagnostic modalities can detect perforations in obturated roots because these modalities are mainly based on visualization of the empty root canal or penetration into it (9).

Cone-beam computed tomography (CBCT) is a valuable diagnostic tool for detection of periapical lesions and evaluation of their healing course (10), vertical root fractures (11), internal and external root canal anatomy (12) and root resorption defects (13). Also, evidence shows that the sensitivity of CBCT is significantly higher than that of periapical radiography for detection of strip perforation; however, the risk of misdiagnosis of strip perforation is still high in both modalities (9).

The patient radiation dose of CBCT is generally higher than that of conventional periapical radiography (14) and it may be used along with periapical radiography in presence/absence of root filling materials for detection of endodontic complications such as strip perforation (15, 16). However, no previous study is available comparing two CBCT systems. Thus, this study aimed to assess the diagnostic accuracy of two different CBCT systems for detection of strip perforation in the mesial root of mandibular molars ex vivo.

## Material and Methods

This ex vivo study evaluated (77) mandibular first and second molars and was approved by the ethics committee of Zahedan University of Medical Sciences (IR.ZAUMS.REC.1397.70).

The teeth were immersed in 5.25% sodium hypochlorite (chloraxid PPH CERKAMED Wojciech Powlowski, Poland) for disinfection and were then stored in distilled water.

All teeth were inspected under an endodontic surgery microscope and those with cracks, fracture or external resorption were excluded. Next, all teeth underwent digital periapical radiography to measure the canal curvature and ensure absence of canal calcification and internal resorption.

Access cavity was prepared and the coronal pulp tissue was removed. Canal patency was ensured using a #15 K-file (Mani Inc., Utsunomiya, Japan), and the working length was determined by introducing the file into the canal and observing its tip at the apical foramen; 1 mm was subtracted from this length to determine the working length.

The root canals were instrumented using #15 to #35 K-files (Mani Inc., Utsunomiya, Japan) with the step-back technique. The canals were repeatedly rinsed with 2% sodium hypochlorite (chloraxid PPH CERKAMED Wojciech Powlowski, Poland) with a 27-gauge needle.

After completion of instrumentation, each canal was rinsed with 2 mL of distilled water and the teeth were stored in distilled water until the next step.

### *Root perforation*

To induce root perforation, danger zone dentin of the mesiobuccal canal was thinned using #2 and #3 Gates-Glidden drills (Dentsply Maillefer, Switzerland) in distoaxial direction at 1 to 3 mm from the furcation level until strip perforation occurred. The perforation was ensured by inserting a #20 K-file (Mani Inc., Utsunomiya, Japan) into the perforation with no resistance felt. Next, the corono-apical diameter of the per-



foration was measured by a digital caliper with  $\pm 0.001$ -inch accuracy per 6 inches (Mitutoyo Corp., Tokyo, Japan).

#### *Canal obturation*

The canals were dried with #30 and #35 paper points (Aridanet, Tehran, Iran). AH26 sealer (Dentsply Maillefer, Ballaigues, Switzerland) was mixed according to the manufacturer's instructions and delivered into the canal using a Lentulo spiral operating at 400 rpm for 5 seconds. Next, a #30 gutta-percha (Gapadent, Tianjin, China) with 0.02 taper was dipped in sealer and reached to the working length. The rest of the canal was filled with #20 and #25 accessory gutta-percha points using #25 and #30 spreaders (Mani Inc., Utsumomiya, Japan) with lateral compaction technique. The roots were stored at 37 °C and 100% humidity for 2 weeks and they were then mounted in extraction sockets in a dry bovine mandible. Three layers of dental wax were applied on the bone surface to simulate the soft tissue and fix the teeth in the extraction sockets.

#### *CBCT*

Dry mandible was positioned such that it simulated the position of patients during CBCT in the clinical setting. The CBCT scans were obtained with Acteon CBCT system (Acteon Group, Norwich, United Kingdom) with the exposure settings of 85 kVp, 8 mA, 80×80 field of view, 0.2 mm voxel size and

10 s of exposure time, and NewTom Giano extraoral imaging system (Vila Silverstrini, Verona, Italy) with 90 kVp, 0.6 mA, 80×50 mm field of view, 0.2 mm voxel size and 10 s of exposure time. In this setting, minimum scatter radiation was observed.

Any discontinuation in the external surface of the root at the site of furcation was considered as strip perforation. Two observers independently observed the images in a random fashion and reported their diagnosis as "presence of perforation", "absence of perforation" or "possibility of perforation" (suspected cases when perforation could not be clearly detected).

The two observers discussed the cases with the possibility of perforation until a consensus was reached.

#### *Statistical analysis*

Two calibrated observers observed the images independently.

The diagnosis of strip perforation was made by not observing the tooth structure at the interface of furcation and root canal filling (figure 1).

The overall agreement between the two observers was calculated using the Cohen's kappa. Values  $>0.70$  indicated excellent agreement, and values  $<0.70$  indicated poor agreement.

The sensitivity, specificity, positive predictive value (PPV), negative predictive value (NPV) and accuracy of the two CBCT systems were calculated.

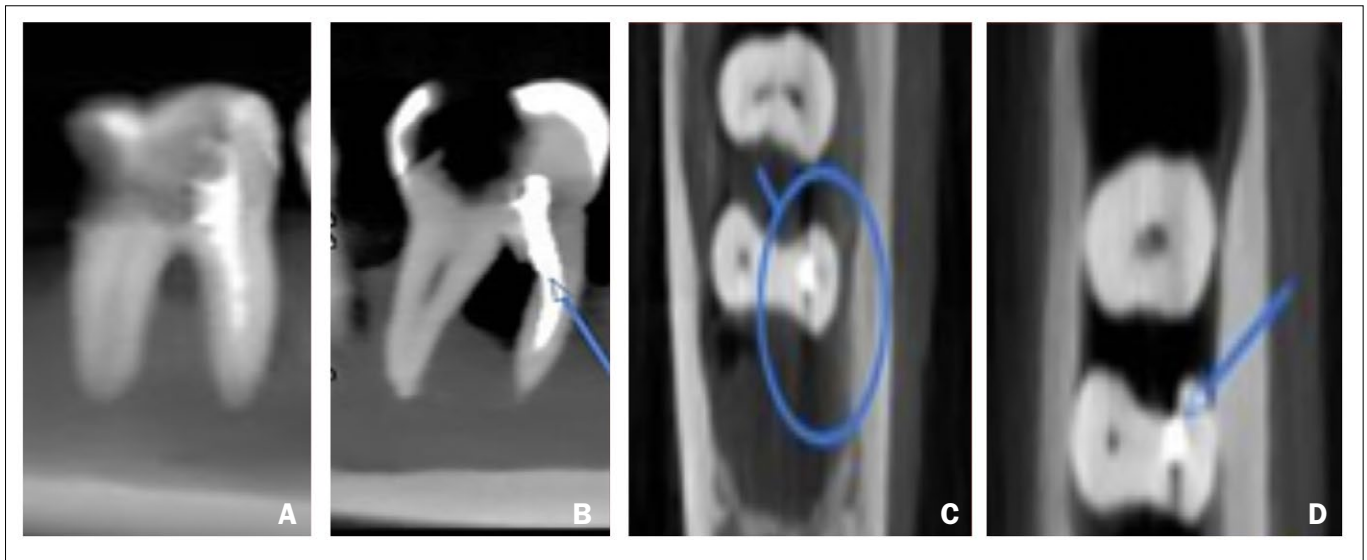
**Table 1**

**Sensitivity, specificity, positive predictive value, negative predictive value and accuracy of the two CBCT systems**

First observer	Second observer		Total			
	ACTEON	NewTom	ACTEON	NewTom	ACTEON	NewTom
Sensitivity	55	62.5	47.5	47.5	51.3	55
Specificity	42.5	32.5	50	45	46.3	38.8
PPV	44	48	51	46	47.5	47
NPV	44	46	51	46	47.5	46
Accuracy	48	47	48	46	48	46.5

PPV: Positive predictive value; NPV: Negative predictive value





**Figure 1**  
**(A)** Sagittal section of a tooth without perforation **(B)** sagittal section of a tooth with mesio Buccal canal perforation (arrow) **(C)** axial section without perforation (circle) and **(D)** axial section with perforation (arrow).

The two systems were compared using the Chi-square test. Data were analyzed using SPSS version 20 (SPSS Inc., IL, USA) with 95% confidence interval.

### Results

Table 1 shows the sensitivity, specificity, PPV, NPV and accuracy of CBCT scans for detection of strip perforation of the root. No significant difference was noted by the first ( $P=0.161$ ) or the second ( $P=0.436$ ) observer in detection of strip perforation between the two CBCT systems.

In all observations, CBCT scans taken by the Acteon system overall detected 53% (81/154) of strip perforations while the NewTom system detected 58.4% (90/154) of strip perforations with no significant difference between the two systems ( $P=0.285$ ). Also, considering the accuracy values  $<50\%$ , none of the two systems had optimally high accuracy for detection of strip perforation. The overall inter-observer agreement was high for both Acteon ( $k=0.86$ ) and NewTom ( $k=0.79$ ) CBCT systems.

### Discussion

Root perforations in the cervical third of the root and pulp chamber floor have a poorer prognosis than the perforations

in the middle third and apical third of the root.

On the other hand, literature is poor regarding the accuracy of different CBCT systems for detection of strip perforations. Thus, this study aimed to assess the sensitivity, specificity, PPV, NPV and accuracy of two CBCT systems for detection of strip perforation in the mesial root of mandibular molar teeth. Although periapical radiography greatly helps in detection of procedural errors, this 2D modality has limitations due to geometric distortion and provides limited data regarding the size, extension and location of defects (3). Inaccuracy of periapical radiography for detection of root perforation has been previously discussed (3).

Limitation of periapical radiography in detection of root perforations may be related to the location of perforation as well, since the perforation may be masked if it is located in the root surface concavity.

Thus, several imaging modalities have been suggested for enhanced detection of root perforations. CBCT has been specifically designed to provide undistorted 3D images of the maxillofacial region, the teeth and their surrounding structures (17).

Thus, CBCT was used in the present study. The results showed no significant



difference in diagnostic accuracy of the two CBCT systems for detection of strip perforation in root canals filled with gutta-percha and AH26 sealer with lateral compaction technique. The reason may be no penetration of root filling materials into the perforation site in lateral compaction technique. However, in soft gutta-percha technique, gutta-percha penetrates into the perforation site and enhances the detection of perforated region (9). Evidence shows that the lateral compaction technique has lower efficacy in providing lateral seal in the canals compared with the warm gutta-percha technique (18).

On the other hand, evidence shows that presence of root canal filling material decreases the efficacy of CBCT scans for detection of vertical root fractures (11). Radiopaque materials such as gutta-percha and AH26 sealer create streak artifacts on CBCT slices and mimic the fracture lines (19, 20). These artifacts can complicate the detection of perforations and prevent definite diagnosis of strip perforation.

A previous study showed significantly higher sensitivity, specificity and accuracy of CBCT in detection of strip perforations in empty canals. In the obturated root canals, the sensitivity of CBCT was significantly lower than that of periapical radiography (21). Although our study did not compare CBCT with periapical radiography, the results showed that the sensitivity, specificity and accuracy of both CBCT systems for detection of strip perforation were low, which was probably due to the presence of root filling materials in the canal.

Not eliminating the smear layer and dentinal debris during root canal preparation and also after perforation in this study might have resulted in penetration of dentinal debris and smear layer into the perforation site, and subsequent prevention of the entry of root filling material into the perforated region.

This would decrease the visibility of perforation site, which can consequently decrease the sensitivity of both CBCT

systems for detection of strip perforation. Moreover, strip perforations were artificially created by the use of Gates-Glidden drills in the mesiolingual canal of molar teeth in our study; thus, the results cannot be generalized to the clinical setting since strip perforations that occur in the clinical setting may be of different sizes (9). Evidence shows that CBCT, irrespective of the presence of root filling materials, can detect medium-size and large perforations significantly better than smaller perforations. Low sensitivity, specificity and accuracy of the two CBCT systems in detection of strip perforations in the mesiobuccal canals of mandibular molar teeth in our study may be due to the small size of perforation.

## Conclusions

The results of this *ex vivo* study revealed no significant difference in sensitivity, specificity, PPV, and NPV of Acteon and NewTom CBCT systems for detection of strip perforation in the mesiobuccal canal of obturated mandibular molars, and the accuracy of both systems was found to be low for detection of strip perforations.

## Clinical Relevance

The results of this study showed that cone beam computed tomography (CBCT) is not a suitable tool for detection of strip perforation of endodontically treated mesial root of mandibular molars.

## Conflict of Interest

The authors deny any conflict of interest related to this study.

## Acknowledgement

The authors would like to thank the Research Deputy of Zahedan University of Medical Sciences for financially supporting this project. The authors have no conflict of interests to declare.

## References

1. Tsesis I, Fuss ZJET. Diagnosis and treatment of accidental root perforations. *Endodontic Topics* 2006;13(1):95-107.
2. Ingle J. A standardized endodontic technique utilizing newly designed instruments and filling materials. *Oral Medicine, Oral Pathology* 1961;14(1):83-91.
3. Tsesis I, Rosenberg E, Faivishevsky V, Kfir A, Katz M, Rosen E. Prevalence and associated periodontal status of teeth with root perforation: a retrospective study of 2,002 patients' medical records. 2010; 36(5):797-800.
4. T Bryant S, Dummer P, Pitoni C, Bourba M, Moghal S. Shaping ability of .04 and .06 taper ProFile rotary nickel-titanium instruments in simulated root canals 1999. 155-64.
5. Moshonov J, Michaeli E, Nahlieli O. Endoscopic root canal treatment. 2009;40(9).
6. Kim S, Kratchman S. Modern endodontic surgery concepts and practice: a review. *Journal of Endodontics*. 2006;32(7):601-23.
7. Gordon M, Chandler N. Electronic apex locators. 2004;37(7):425-37.
8. Shemesh H, Van Soest G, Wu M-K, Van der Sluis LW, Wesselink P. The ability of optical coherence tomography to characterize the root canal walls. 2007;33(11):1369-73.
9. Shemesh H, C Cristescu R, Wesselink P, Wu MK. The Use of Cone-beam Computed Tomography and Digital Periapical Radiographs to Diagnose Root Perforations 2011. 513-6.
10. Estrela C, Bueno MR, Azevedo BC, Azevedo JR, Pécora J. A new periapical index based on cone beam computed tomography. 2008;34(11): 1325-31.
11. Hassan B, Metska ME, Ozok AR, van der Stelt P, Wesselink PRJ. Detection of vertical root fractures in endodontically treated teeth by a cone beam computed tomography scan. 2009;35(5):719-22.
12. Huang CC, Chang YC, Chuang MC, Lai TM, Lai JY, Lee BS et al. Evaluation of root and canal systems of mandibular first molars in Taiwanese individuals using cone-beam computed tomography. 2010;109(4):303-8.
13. Patel S, Dawood A, Wilson R, Horner K, Mannocci F. The detection and management of root resorption lesions using intraoral radiography and cone beam computed tomography—an in vivo investigation. 2009;42(9):831-8.
14. Shokri A, Eskandarloo A, Noruzi-Gangachin M, Khajeh S. Detection of root perforations using conventional and digital intraoral radiography, multidetector computed tomography and cone beam computed tomography. *Restorative dentistry & endodontics*. 2015;40(1):58-67.
15. Koc C, Sonmez G, Yilmaz F, Karahan S, Kamburoglu K. Comparison of the accuracy of periapical radiography with CBCT taken at 3 different voxel sizes in detecting simulated endodontic complications: an ex vivo study. *Dento maxillo facial radiology*. 2018;47(4):20170399.
16. Shokri A, Eskandarloo A, Norouzi M, Poorolajal J, Majidi G, Aliyaly A. Diagnostic accuracy of cone-beam computed tomography scans with high- and low-resolution modes for the detection of root perforations. *Imaging Sci Dent*. 2018;48 (1):11-9.
17. Patel S, Dawood A, Whaites E, Pitt Ford T. New dimensions in endodontic imaging: part 1. Conventional and alternative radiographic systems. 2009;42(6):447-62.
18. Carvalho-Sousa B, Almeida-Gomes F, Carvalho PRB, Maniglia-Ferreira C, Gurgel-Filho ED, Albuquerque DS. Filling lateral canals: evaluation of different filling techniques. 2010;4(3):251.
19. Zhang Y, Zhang L, Zhu XR, Lee AK, Chambers M, Dong L. Reducing metal artifacts in cone-beam CT images by preprocessing projection data. 2007;67(3):924-32.
20. Hassan B, Metska ME, Ozok AR, van der Stelt P, Wesselink P. Comparison of five cone beam computed tomography systems for the detection of vertical root fractures. 2010;36(1):126-9.
21. Adel M, Tofangchiha M, Atashbiz Yeganeh L, Javadi A, Azari Khojaste A. Efficacy of Cone-Beam Computed Tomography compared to Conventional Periapical Radiography in Detecting Strip Root Perforations, *J journal of research in dental sciences*. 2014;11(2):103-7.

## ORIGINAL ARTICLE/ARTICOLO ORIGINALE

# Comparison of Reciproc, Wave One, Protaper, and One Shape rotary instruments in reduction of bacterial load in root canals

**KEYWORDS**Endodontics, Bacteria,  
Root canal therapy**PAROLE CHIAVE**Endodonzia, Batteri,  
Terapia canalare

Confronto della capacità di riduzione della carica batterica in canali radicolari degli strumenti Reciproc, Wave One, Protaper e One Shape

**Abstract**

Ali Azizi<sup>1</sup>  
Reza Hatam<sup>2</sup>  
Parisa Soltani<sup>3</sup>  
Shimasadat Miri<sup>2\*</sup>  
Ramin Abiri<sup>4</sup>

<sup>1</sup>School of Dentistry,  
Kermanshah University of Medical  
Sciences, Kermanshah, Iran

<sup>2</sup>Department of Endodontics,  
School of Dentistry, Kermanshah  
University of Medical Sciences,  
Kermanshah, Iran

<sup>3</sup>Dental Implants Research  
Center, Department of Oral and  
Maxillofacial Radiology, Dental  
Research Institute, Isfahan  
University of Medical  
Sciences, Isfahan, Iran

<sup>4</sup>Department of Microbiology,  
School of Medicine, Kermanshah  
University of Medical  
Sciences, Kermanshah, Iran

Received 2020, November 4

Accepted 2020, February 27

**Aim:** To compare the effectiveness of Reciproc, Wave One, Protaper, and One Shape rotary instruments in reduction of *E. faecalis* in root canals.

**Methodology:** In this in-vitro study, after initial stages of canal enlargement and irrigation, a suspension containing *Enterococcus faecalis* was inoculated into the root canals of 84 extracted single-canal premolars. The samples (apart from two positive and two negative controls) were randomly assigned into four groups according to rotary instruments used: Reciproc, Wave One, One Shape, Protaper. Each group was then subdivided to two groups based on irrigating solutions of normal saline and NaOCl. After instrumentation, the root canals were filled with brain-heart infusion (BHI) broth. Finally bacterial colony forming units (CFU) were counted.

**Results:** Reduction in number of bacterial colonies before and after instrumentation and irrigation was not significantly different in different rotary instrument systems ( $P=0.128$ ,  $F=1.955$ ). However, NaOCl was more effective in reduction of bacterial load compared to normal saline ( $P<0.001$ ,  $F=15.528$ ).

**Conclusions:** All rotary instruments used in the study are effective in reduction of the bacterial load.

**Obiettivo:** confrontare la capacità di riduzione dell'*E. Faecalis* in canali radicolari degli strumenti Reciproc, Wave One, Protaper e One Shape.

**Materiali e Metodi:** in questo studio in vitro, dopo una fase iniziale di allargamento e irrigazione dei canali, 84 premolari estratti con singolo canale sono stati inoculati con una sospensione di *Enterococcus Faecalis*. I campioni (oltre a due controlli positivi e due controlli negativi) sono stati assegnati a quattro gruppi a seconda dello strumento utilizzato: Reciproc, Wave One, One Shape, Protaper. Ogni gruppo è stato a sua volta suddiviso in due gruppi a seconda che si utilizzasse come irrigante soluzione Salina o NaOCl. Dopo la strumentazione i canali radicolari sono stati riempiti di brain heart infusion (BHI). Successivamente sono state calcolate le unità formanti colonie (CFU).

**Risultati:** la riduzione nel numero di colonie batteriche prima e dopo strumentazione e irrigazione non è risultata statisticamente significativa fra i diversi sistemi di strumenti utilizzati ( $P=0.128$ ,  $F=1.955$ ). Comunque l'NaOCl è risultato più efficace nella riduzione della carica batterica confrontandolo con la soluzione salina ( $P<0.001$ ,  $F=15.528$ ).

**Conclusioni:** tutti gli strumenti utilizzati nello studio sono efficaci nella riduzione della carica batterica.

**Corresponding author**

Dr. Shimasadat Miri | School of Dentistry, Shariati St., Kermanshah | Iran  
Tel. +989122083785 | shsami2010@yahoo.com

Peer review under responsibility of Società Italiana di Endodonzia

[10.32067/GIE.2020.34.01.10](https://doi.org/10.32067/GIE.2020.34.01.10)

Società Italiana di Endodonzia. Production and hosting by Ariesdue. This is an open access article under the CC BY-NC-ND license (<http://creativecommons.org/licenses/by-nc-nd/4.0/>).



## Introduction

It is known that bacteria and their byproducts are the main etiologic factors in pulpal and periapical disease (1). Bacterial biofilms have been found in most teeth with apical periodontitis (2). The primary goal in endodontic treatment is elimination of bacteria from the root canal system by mechanical and chemical means (3). Also persistent infection is the main reason of failures of endodontic treatment (4). *Enterococci* are facultative anaerobic bacteria. *Enterococcus faecalis* is the most common bacteria isolated from endodontically treated teeth (5). This microorganism can penetrate the dentinal tubules and resist mechanical and chemical debridement and intracanal medicaments thus causing reinfection of the root canals (6).

Various techniques are suggested for debridement of root canal system. Mechanical instrumentation removes the infected dentin from root canal walls. Irrigants solve the organic debris in the canal and remove the microorganisms. However, regardless of technique and material complete disinfection of root canal system is not possible (7, 8). In modern endodontics, engine-driven instrumentation by rotary Nickel-Titanium (NiTi) files has been recruited increasingly for preparation of root canals as it reduces procedural error, preparation time, and operator fatigue compared to manual instrumentation (9, 10). Reciproc (RC, VDW, Munich, Germany) and Wave One (WO, Dentsply Maillefer, Ballaigues, Switzerland) files are made of a special NiTi alloy called M-wire created by an innovative thermal treatment process (11). This alloy provides increased flexibility of the instruments and improved resistance to cyclic fatigue (12). Moreover, the reciprocating motion in these two systems which necessitates the use of special motors, leads to less stress accumulation in the file and makes the instrument less susceptible to separation (13). Universal Protaper (PT, Dentsply Maillefer, Ballaigues, Switzerland) rotary system has a modified cross-sectional design similar to that of K-file. This

design allows the instrument to cut the dentin more electively and thus reduces torsional loads (14). One Shape (OS, Micro-Mega, Besancon, France) is another rotary instrumentation system with a non-working safety tip that ensures effective apical progression avoiding obstructions which can lead to instrument separation (15).

Based on our knowledge, no previous study has compared the effectiveness of the aforementioned rotary systems in reduction of bacterial load from root canals. Therefore, the aim of the present study was to compare the effectiveness of RC, WO, PT, and OS rotary instruments in reduction of *E. faecalis* in root canals.

## Materials and Methods

84 extracted single canal premolars with complete apices which were extracted for orthodontic reasons were selected. Radiography was used to confirm that only one root canal exists. The crown of the teeth is cut to achieve a root length of 15 mm. The point of termination of root canal preparation was the apical foramen. After debridement, the root canals were filled with EDTA 17% solution for 1 min and then irrigated by sodium hypochlorite (NaOCl) 1% and sterile water to remove the smear layer. Then the apical end of the teeth was sealed with composite resin and the outer surface of the roots was covered with epoxy resin in order to prevent from bacterial leakage. The teeth were then individually mounted on gypsum blocks for better handling during instrumentation. Thereafter, they were packed and sterilized in an autoclave (121 °C, 30 min, 15 psi). Two of the teeth were not sterilized as negative controls. Bacterium used in this study was *Enterococcus faecalis* (ATCC29212). The bacterium was cultured on brain-heart infusion (BHI) medium reaching the  $1.5 \times 10^8$  colonies and a bacterial suspension was prepared. Eppendorf tubes containing sterile teeth were placed under laminar flow hood and inoculated by the bacterial suspension using a sterile pipet. Fresh BHI medium was added to the sam-



**Table 1**  
**Logarithm of number of bacterial colonies before and after instrumentation and irrigation**

File	Irrigant	Before		After	
		Mean	SD	Mean	SD
Reciproc	NaOCl	1320	469.61	158	50.29
	Saline	1624	391.90	546	192.54
Wave One	NaOCl	1338	409.82	164	69.15
	Saline	1366	478.80	679	229.45
Protaper	NaOCl	1375	589.85	271	138.33
	Saline	1228	930.62	207	110.76
One Shape	NaOCl	1214	392.68	328	135.71
	Saline	1094	416.14	164	89.73
Total	<b>NaOCl</b>	<b>1311</b>	<b>457.39</b>	<b>230</b>	<b>125.29</b>
	<b>Saline</b>	<b>1328</b>	<b>606.31</b>	<b>399</b>	<b>273.18</b>

ples every 1 week and the samples were incubated for four weeks in 37 °C. After the incubation period, the teeth were removed from the tube under laminar flow hood and mounted back on their gypsum blocks. A K-file no.15 was then inserted into the canal and the canal was filed for 10 s. Two teeth were not instrumented as positive controls. The samples from root canals were collected by placement of three paper point no. 20 each placed into the canal for 10 s. then the paper points were transmitted to tubes containing 5 µl BHI medium and vortexed for 30 min for serial dilution. Each dilution was then placed on BHI agar plates and incubated for 48 h in 37 °C. Then the colony forming units (CFU) were counted.

The samples were randomly assigned into four groups each instrumented with a different rotary system; RC, WO, OS, PT each containing 20 teeth. Each group was then subdivided to 2 groups based on irrigating solutions of normal saline and NaOCl 5.25%. The total volume of irrigant was 18 ml. Roots canals were irrigated with 2 ml of irrigating solution each time the instrument was changed with the use of needles attached to 5-ml luer lock syringes. Final rinse was per-

formed by 10 ml of the irrigating solution. Instrumentation was performed using four rotary system based on company instructions:

1. RC: R25 file (tip size 25, 0.08 taper) was gently inserted into the cervical third of the root canal with in-and-out pecking motion. After three movements, the file was removed from the canal to clean the flutes. Then, the file was re-inserted in the same manner for the middle third. Lastly, the file was inserted at WL with a brushing motion against the canal walls.
2. WO: Primary file size 25, 0.08 taper was inserted into approximately two-thirds of the canal length with in-and-out pecking motion. After retrieval of the file, it was inserted again at WL with the same motion.
3. OS: Instrumentation was performed with a slight pecking motion until the WL has been achieved.
4. PT: Preparation was done by crown-down technique using the sequence of SX (at two-thirds of WL), S1 and S2 (at 1 mm short of the WL), and F1 and F2 (at WL) instruments. The files were passively used with in-and-out movements and also lateral brushing motion.

After instrumentation, the root canals were filled with BHI broth. *E. faecalis* can stay in the dentinal tubules and the samples should be filled with BHI broth and recollected after 60 days. Data was statistically analyzed by Statistical Package for the Social Sciences (SPSS, v 22, IBM, NY, USA) using descriptive statistics, Shapiro-Wilk analysis, and two-way analysis of variance. Level of significance was set at  $\alpha=0.05$ .

## Results

Shapiro-Wilk analysis confirmed the normal distribution of the data ( $P>0.1$ ). Table 1 depicts the descriptive statistics of number of bacterial colonies before and after instrumentation and irrigation. Based on two-way analysis of variance the number of bacterial colonies before instrumentation and irrigation was not significantly different in the groups with different instruments ( $P=0.316$ ) and irrigants ( $P=0.893$ ). Reduction in number of bacterial colonies before and after instrumentation and irrigation was not significantly different in different rotary instrument systems ( $P=0.128$ ,  $F=1.955$ ). However, a statistically significant difference was observed in reduction of bacterial colonies between samples irrigated with normal saline and NaOCl ( $P<0.001$ ,  $F=15.528$ ) with NaOCl being more effective in reduction of bacterial load. Moreover, the amount of reduction in bacterial load using different irrigants was dependent on instrument type ( $P<0.001$ ,  $F=18.551$ ). In RC, PT, and WO systems NaOCl was more effective in reduction of bacteria than normal saline. While, in OS system normal saline showed higher reduction of bacteria compared to NaOCl, although not significant.

## Discussion

According to the results of the present study, reduction of bacterial load was not significantly different in root canals treated with different rotary systems. However, use of NaOCl was significantly more effective in reduction of *E. faecalis* than normal saline.

In this study *E. faecalis* was used to evaluate and compare the effectiveness of four rotary systems and two irrigants in reduction of bacteria as a measure of canal disinfection. *E. faecalis* is present in persistent endodontic infections and is resistant to various protocols of root canal preparation and intracanal medicaments (16, 17). Moreover, it can survive in difficult environmental conditions (18). *E. faecalis* can also reside in infected root canals without the synergistic support of other bacteria in contrast to most other endodontic bacteria (19).

Machado et al reported that no statistically significant difference was found between PT and Mtwo rotary instruments in removal of *E. faecalis* from root canals (9).

Moreover, Martinho et al in their study concluded that WO, RC, PT, and Mtwo rotary endodontic systems are equally effective in reduction of endotoxins and cultivable bacteria from primarily infected root canals, although they were not able to eliminate them from all tested root canals (20).

Similar results were also observed by Machado et al in another study (21). These findings are consistent with the results of the present study as examined endodontic systems had similar effectiveness in reduction of *E. faecalis* from root canals.

However, Burklein et al reported that RC and Mtwo rotary systems are more effective in cleaning of the apical region compared to WO and PT (11). As their result was not observed in other similar studies, further evaluation might be needed to elucidate any possible difference between various rotary systems.

Different designs of rotary systems may alter the efficiency of these files in bacterial reduction. More aggressive removal of dentin would eliminate more bacteria from the root canals (22). Also, the size of apical enlargement is important in the amount of reduction of intracanal bacteria (23).

Practitioners must consider that regardless of the endodontic system used for cleaning and shaping of root canals, dentinal walls must be removed and proper apical preparation must be performed to ensure maximal reduction of bacteria from the root canals.

Siqueira et al stated that although both ro-



tary and hand instrumentation techniques were significantly effective in reduction of bacterial population, however, in all cases NaOCl was more effective in elimination of bacterial load from root canals compared to normal saline (24).

This finding is also similar to the results of the present study. Studies suggest that the antimicrobial effect of NaOCl is not significantly different in 0.5% to 5% solutions (25-27).

The frequency and the volume of NaOCl can compensate the differences in solution concentration. However, complete elimination of bacteria may not be possible regardless of concentration, frequency, and volume of irrigants (24).

Although reduction of bacterial load is reported in many studies following the use of hand or rotary instruments, complete elimination of bacteria such as *E. faecalis* is not possible (28). Therefore, adequate use of irrigants is important when cleaning and shaping is done by any method.

### Conclusions

Under the conditions of this study reduction of bacterial load was not significant-

ly different in root canals treated with different rotary systems. However, use of NaOCl was significantly more effective in reduction of *E. faecalis* than normal saline.

### Clinical Relevance

Elimination of bacteria from the root canal system is the primary goal of endodontic treatment. Although Reciproc, Wave One, Protaper, and One Shape rotary files used in this study were not significantly different for this purpose, NaOCl was more effective in bacterial reduction compared to normal saline.

### Conflict of Interest

The authors deny any conflict of interest.

### Acknowledgements

This study was financially supported by Kermanshah University of Medical Sciences (grant number 95560). This study was performed as a partial requirement for obtaining DDS degree for the first author (Ali Azizi) in Kermanshah University of Medical Sciences.

## References

1. Kakehashi S, Stanley H, Fitzgerald R. The effects of surgical exposures of dental pulps in germ-free and conventional laboratory rats. *Oral Surg Oral Med Oral Pathol.* 1965;20:340-9.
2. Ricucci D, Siqueira JF, Jr. Biofilms and Apical Periodontitis: Study of Prevalence and Association with Clinical and Histopathologic Findings. *J Endod.* 2010;36:1277-88.
3. Pantera EA. *Essential Endodontology: Prevention and Treatment of Apical Periodontitis.* Am Dental Educ Assoc; 2008.
4. Pinheiro E, Gomes B, Ferraz C, Sousa E, Teixeira F, Souza-Filho F. Microorganisms from canals of root-filled teeth with periapical lesions. *Int Endod J.* 2003;36:1-11.
5. Peciuliene V, Reynaud A, Balciuniene I, Haapasalo M. Isolation of yeasts and enteric bacteria in root-filled teeth with chronic apical periodontitis. *Int Endod J.* 2001;34:429-34.
6. Stuart CH, Schwartz SA, Beeson TJ, Owatz CB. *Enterococcus faecalis: its role in root canal treatment failure and current concepts in retreatment.* *J Endod.* 2006;32:93-8.
7. Siqueira JF, Alves FR, Versiani MA, Rôças IN, Almeida BM, Neves MA, et al. Correlative bacteriologic and micro-computed tomographic analysis of mandibular molar mesial canals prepared by Self-Adjusting File, Reciproc, and Twisted File systems. *J Endod.* 2013;39:1044-50.
8. Endo M, Martinho F, Zaia A, Ferraz C, Almeida J, Gomes B. Quantification of cultivable bacteria and endotoxin in post-treatment apical periodontitis before and after chemo-mechanical preparation. *Eur J Clin Microbiol Infect Dis* 2012;31:2575-83.
9. de Lima Machado ME, Sapia LAB, Cai S, Martins GHR, Nabeshima CK. Comparison of two rotary systems in root canal preparation regarding disinfection. *J Endod.* 2010;36:1238-40.
10. Foschi F, Nucci C, Montebugnoli L, Marchionni S, Breschi L, Malagnino V, et al. SEM evaluation of canal wall dentine following use of Mtwo and ProTaper NiTi rotary instruments. *Int Endod J.* 2004;37:832-9.
11. Bürklein S, Hinschitzka K, Dammashcke T, Schäfer E. Shaping ability and cleaning effectiveness of two single-file systems in severely curved root canals of extracted teeth: Reciproc and WaveOne versus Mtwo and ProTaper. *Int Endod J.* 2012;45:449-61.
12. Shen Y, Cheung GS-p, Bian Z, Peng B. Comparison of defects in ProFile and ProTaper systems after clinical use. *J Endod.* 2006;32:61-5.
13. De-Deus G, Brandão MC, Barino B, Di Giorgi K, Fidel RAS, Luna AS. Assessment of apically extruded debris produced by the single-file ProTaper F2 technique under reciprocating movement. *Oral Surg Oral Med Oral Pathol Oral Radiol Endod.* 2010;110:390-4.
14. Maitin N, Arunagiri D, Brave D, Maitin SN, Kaushik S, Roy S. An ex vivo comparative analysis on shaping ability of four NiTi rotary en-





## References

- dodontic instruments using spiral computed tomography. *J Conserv Dent.* 2013;16:219.
15. Dhingra A, Kochar R, Banerjee S, Srivastava P. Comparative evaluation of the canal curvature modifications after instrumentation with One Shape rotary and Wave One reciprocating files. *J Conserv Dent.* 2014;17:138.
  16. Sakamoto M, Siqueira J, Rôças I, Benno Y. Bacterial reduction and persistence after endodontic treatment procedures. *Mol Oral Microbiol.* 2007;22:19-23.
  17. Byström A, Claesson R, Sundqvist G. The antibacterial effect of camphorated paramonochlorophenol, camphorated phenol and calcium hydroxide in the treatment of infected root canals. *Dent Traumatol.* 1985;1:170-5.
  18. Jett BD, Huycke MM, Gilmore MS. Virulence of enterococci. *Clin Microbiol Rev.* 1994;7:462-78.
  19. Coldero L, McHugh S, MacKenzie D, Saunders W. Reduction in intracanal bacteria during root canal preparation with and without apical enlargement. *Int Endod J.* 2002;35:437-46.
  20. Martinho FC, Gomes APM, Fernandes AMM, Ferreira NS, Endo MS, Freitas LF, et al. Clinical Comparison of the Effectiveness of Single-file Reciprocating Systems and Rotary Systems for Removal of Endotoxins and Cultivable Bacteria from Primarily Infected Root Canals. *J Endod.* 2014;40:625-9.
  21. Machado M, Nabeshima C, Leonardo M, Reis F, Britto M, Cai S. Influence of reciprocating single-file and rotary instrumentation on bacterial reduction on infected root canals. *Int Endod J.* 2013;46:1083-7.
  22. Gorduysus M, Nagas E, Torun OY, Gorduysus O. A comparison of three rotary systems and hand instrumentation technique for the elimination of *Enterococcus faecalis* from the root canal. *Aust Endod J.* 2011;37:128-33.
  23. Baugh D, Wallace J. The role of apical instrumentation in root canal treatment: a review of the literature. *J Endod.* 2005;31:333-40.
  24. Siqueira JF, Rôças IN, Santos SR, Lima KC, Magalhães FA, de Uzeda M. Efficacy of instrumentation techniques and irrigation regimens in reducing the bacterial population within root canals. *J Endod.* 2002;28:181-4.
  25. Siqueira Jr JF, Rôças IN, Favieri A, Lima KC. Chemomechanical reduction of the bacterial population in the root canal after instrumentation and irrigation with 1%, 2.5%, and 5.25% sodium hypochlorite. *J Endod.* 2000;26:331-4.
  26. Byström A, Sunqvist G. The antibacterial action of sodium hypochlorite and EDTA in 60 cases of endodontic therapy. *Int Endod J.* 1985;18:35-40.
  27. Cvek M, Nord C-E, Hollender L. Antimicrobial effect of root canal débridement in teeth with immature root. A clinical and microbiologic study. *Odontol Revy.* 1976;27:1-10.
  28. Paranjpe A, De Gregorio C, Gonzalez AM, Gomez A, Herzog DS, Piña AA, et al. Efficacy of the self-adjusting file system on cleaning and shaping oval canals: a microbiological and microscopic evaluation. *J Endod.* 2012;38:226-31.

## ORIGINAL ARTICLE/ARTICOLO ORIGINALE

# Effect of composite thickness over the fiber post on fracture resistance of endodontically treated teeth

Influenza dello spessore del composito sul perno in fibra sulla resistenza alla frattura di denti trattati endodonticamente

**KEYWORDS**

Composite Resin, Conservative Dentistry, Endodontically Treated Teeth, Fiber Post, Fracture Resistance, Restorative Dentistry

**PAROLE CHIAVE**

Composito, Odontoiatria conservativa, Denti trattati endodonticamente, Perno in fibra, Resistenza alla frattura, Odontoiatria restaurativa

**Kasra Rahimpour<sup>1</sup>**  
**Narges Panahandeh<sup>1</sup>**  
**Seyedeh Mahsa Sheikh-AI-Eslamian<sup>1\*</sup>**  
**Reza Mousavi<sup>1</sup>**  
**Hassan Torabzadeh<sup>1</sup>**

<sup>1</sup>Dental Research Center, Research Institute of Dental Sciences, School of Dentistry, Shahid Beheshti University of Medical Sciences, Tehran, Iran

Received 2019, November 1

Accepted 2020, February 10

**Corresponding author**

Seyedeh Mahsa Sheikh-AI-Eslamian | Research Institute of Dental Sciences, Shahid Beheshti University of Medical Science, Evin, Tehran | Iran  
Tel. +98 21 22413897 | mahsa.sheikh@gmail.com

**Abstract**

**Aim:** This study aimed to assess the effect of composite thickness over the fiber post on fracture resistance of endodontically treated teeth.

**Materials and Methods:** This in vitro experimental study was performed on 50 sound human premolars, which were randomly divided into 5 groups (n=10). Teeth in Group 1 remained intact while other specimens underwent root canal treatment with a Mesio-occluso-distal (MOD) cavity preparation, restored with fiber posts with a distance of 1.5 mm to the occlusal surface in groups 2 and 4 and 0.5 mm in groups 3 and 5. 24 hours of incubation was applied for groups 1-3 and 1 year of incubation for groups 4 and 5. Thereafter fracture strength measured using a Universal Testing Machine at a crosshead speed of 1 mm/minute. Data were analyzed using Shapiro-Wilk, Two-Way ANOVA and Tukey HSD.

**Results:** The results showed a significant difference in terms of fracture resistance ( $P < 0.05$ ). The difference in fracture resistance between Group 1 and other groups was not statistically significant at 24h ( $P > 0.05$ ). Also, Tukey HSD revealed no statistically significant differences between Group 1 and 4 at one year. However, Group 1 ( $1255.25 \pm 280.61N$ ) exhibited significantly higher fracture resistance than that of Group 5 ( $855.72 \pm 300.20N$ ) at one year ( $P = 0.027$ ). The difference between other groups was not significant at any time point ( $P > 0.05$ ).

**Conclusions:** By covering the fiber post with 1.5 mm thickness of composite resin and cuspal reduction of 2 mm, the fracture resistance of endodontically treated teeth can be increased to the level of sound teeth.

**Obiettivo:** lo scopo di questo studio è di valutare l'influenza dello spessore del composito, posizionato sopra il perno in fibra, sulla resistenza alla frattura dei denti trattati endodonticamente.

**Materiali e Metodi:** questo studio in vitro è stato effettuato utilizzando 50 premolari umani che sono stati suddivisi in 5 gruppi (n=10). I denti del Gruppo 1 non sono stati trattati mentre negli altri campioni è stata preparata una cavità mesio-occluso-distale (MOD) ed è stata effettuata una terapia canalare. I campioni sono stati poi ricostruiti tramite posizionamento di perni in fibra, posti ad una distanza dalla superficie occlusale di 1.5 mm (Gruppo 2 e 4) e di 0.5 mm (Gruppo 3 e 5). I denti dei Gruppi 1, 2 e 3 sono stati incubati per 24 ore, quelli dei Gruppi 4 e 5 per un anno. Successivamente, utilizzando una Universal Testing Machine ad una velocità di 1 mm/min, è stata valutata la resistenza alla frattura dei campioni. I dati sono stati analizzati con i test statistici Shapiro-Wilk, Two-Way ANOVA e Tukey HSD.

**Risultati:** i risultati hanno mostrato una differenza significativa nella resistenza alla frattura ( $p < 0.05$ ). La resistenza alla frattura tra il Gruppo 1 e gli altri gruppi non è risultata statisticamente significativa a 24 ore ( $p > 0.05$ ). L'utilizzo del Tukey HSD non ha mostrato una differenza statisticamente significativa tra il Gruppo 1 e il Gruppo 4 a un anno di distanza. Il Gruppo 1 ( $1255.25 \pm 280.61N$ ) ha mostrato una resistenza alla frattura statisticamente più alta del Gruppo 5 a un anno di distanza ( $855.72 \pm 300.20N$ ) ( $P = 0.027$ ). Non c'è stata differenza statisticamente significativa fra gli altri gruppi ( $P > 0.05$ ).

**Conclusioni:** la resistenza alla frattura di un dente trattato endodonticamente risulta la stessa di un dente integro, effettuando una riduzione cuspidale di 2 mm e coprendo il perno in fibra con 1.5 mm di composito.

Peer review under responsibility of Società Italiana di Endodonzia

10.32067/GIE.2020.34.01.11

Società Italiana di Endodonzia. Production and hosting by Ariesdue. This is an open access article under the CC BY-NC-ND license (<http://creativecommons.org/licenses/by-nc-nd/4.0/>).

## Introduction

The main goal of dentistry is to preserve the teeth and minimize tooth loss as much as possible (1, 2). Many techniques have been suggested for restoration of severely damaged teeth after endodontic treatment. Evidence shows that the success of endodontic treatment not only depends on the successful completion of all procedural steps of endodontic treatment such as providing an apical seal and removing the necrotic tissue but also depends on the successful restoration of teeth (3). It should be noted that a root canal treatment should not be considered complete until the tooth crown is well restored (4).

Endodontically treated teeth are susceptible to fracture and researchers have long been in search of restorative materials and technique to reinforce the remaining tooth structure.

Considering the recent advances in formulations of composite resins and their affordability, direct composite restorations are suitable for endodontically treated teeth. Panahandeh et al (5) evaluated the effect of composite thickness on stress distribution in a restored endodontically treated premolar with cusp reduction. The results demonstrated that more stress is observed in the tooth without cusp reduction compared to the other models, and cusp reduction resulted in more suitable stress distribution. Considering the poor retention of restorative materials in endodontically treated teeth that have lost a great portion of their coronal structure, intra-radicular posts are often used in such cases to provide retention for the coronal restoration (6). Fiber posts are increasingly used in dental clinical settings due to their higher flexibility compared to metal posts and having a modulus of elasticity close to that of dentin. They allow relatively uniform stress distribution and decrease the incidence of catastrophic tooth fracture (7). Torabzadeh et al (8) evaluated the

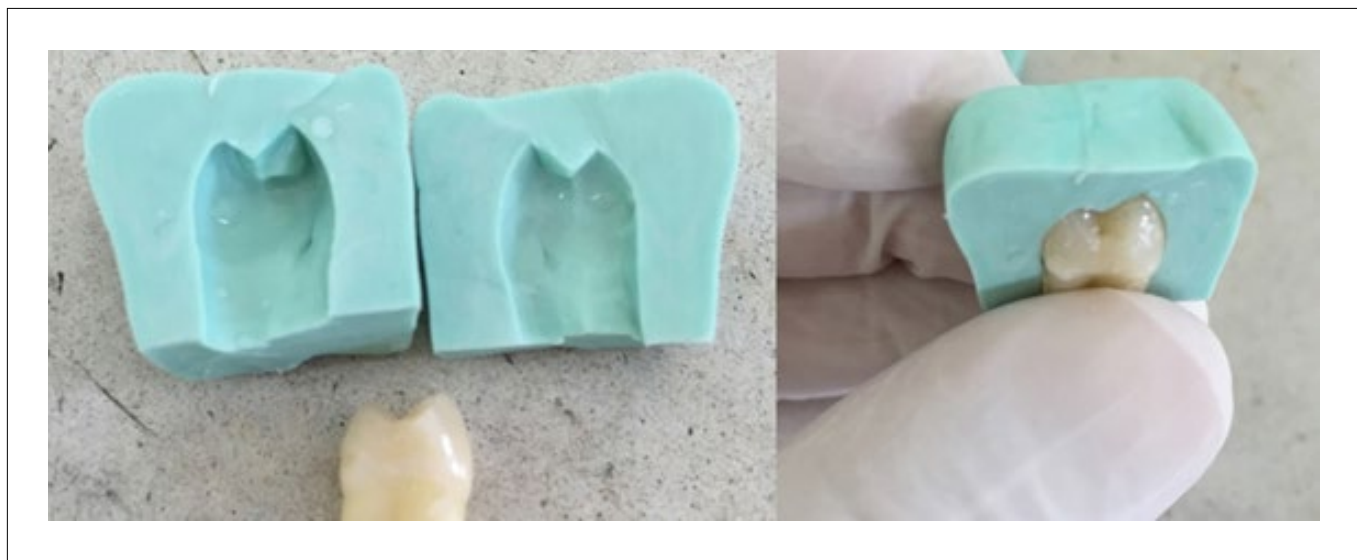efficacy of using fiber in direct composite restorations and showed that cusp coverage of 1.5 and 2.5 mm in MOD access cavities with or without insertion of resin impregnated fiber had similar fracture rates in the endodontically treated teeth. Further evidence confirmed that cuspal coverage in directly bonded restorations enhanced the fracture resistance of teeth and protected the cusps against fracture (9).

In this regard, the thickness of the core material can significantly affect the fracture resistance of endodontically treated teeth with intra-radicular posts (10). Composite resins are commonly used for reconstruction of the core in endodontically treated teeth and the thickness of composite covering the post can significantly affect load distribution and fracture resistance of teeth (11, 12). However, data are scarce regarding the effect of the composite thickness over fiber posts on fracture resistance of teeth. Therefore, this study was undertaken to assess the effect of composite thickness (0.5 and 1.5 mm) over the fiber post on the fracture resistance of endodontically treated teeth after 24 hours and one year.

## Materials and Methods

This in vitro study was performed on 50 sound single-canal human premolars extracted for orthodontic or periodontal reasons during the past six months. The soft tissue residues and calculus were removed from the coronal and radicular surfaces of the teeth using a hand scaler (Gracy Curette SG 17/18; Hu Friedy; Chicago, IL, USA). The teeth were inspected under a stereomicroscope (SZ61; Olympus, Tokyo, Japan) at x10 magnification to ensure the absence of cracks and caries. The teeth were anatomically examined to ensure that they all had normal anatomy and had no anomaly. The teeth were stored in distilled water in a screw-top container at 4 °C until the preparation. The water was refreshed weekly.

*Tooth preparation*



**Figure 1**  
Silicone impression as an index for the restoration of the crown.

The buccal and lingual height from the cusp tip to the cemento-enamel junction (CEJ) and the buccolingual width of teeth at the height of contour were measured by a digital caliper (Mitutoyo, Tokyo, Japan) to select teeth with relatively equal dimensions (for the purpose of standardization of samples). The size of the tooth was calculated by dividing tooth height by tooth width. The teeth (n=50) were randomly divided into 5 Groups of 10. Impressions were made of teeth in Groups 2 to 5 using putty silicone impression material (Speedex putty type I; Coltene, Altstätten, Switzerland) (8).

After polymerization of impression material, it was sectioned occlusoapically by a scalpel to obtain two half-impressions to serve as molds. The teeth were then removed from the impressions. These impressions were used as an index for the restoration of the crown (figure 1).

Teeth in Group 1 remained intact. In Groups 2 to 5, the access cavity was prepared in teeth using diamond fissure burs. A #15 K-file (Mani Inc., Tochigi, Japan). The root canals were cleaned, filed and flared to file #60 using the step-back technique. Saline was used for irrigation. The master file was #35, and the root canals were filled using lateral compaction technique. A #25

spreader, #15 lateral gutta-percha cones and #35 gutta-percha master cone (Aridanet, Tehran, Iran) along with AH26 sealer (Dentsply/DeTrey, Konstanz, Germany) were used for this purpose.

At this stage for post space preparation, gutta-percha in the canal was removed to 5 mm above the apex using #1 and #2 Gates-Glidden drills (Gates Glidden; Dentsply Maillefer, York, PA) and #1 and #2 peeso reamers (Peeso Burs; Dentsply Maillefer, York, PA).

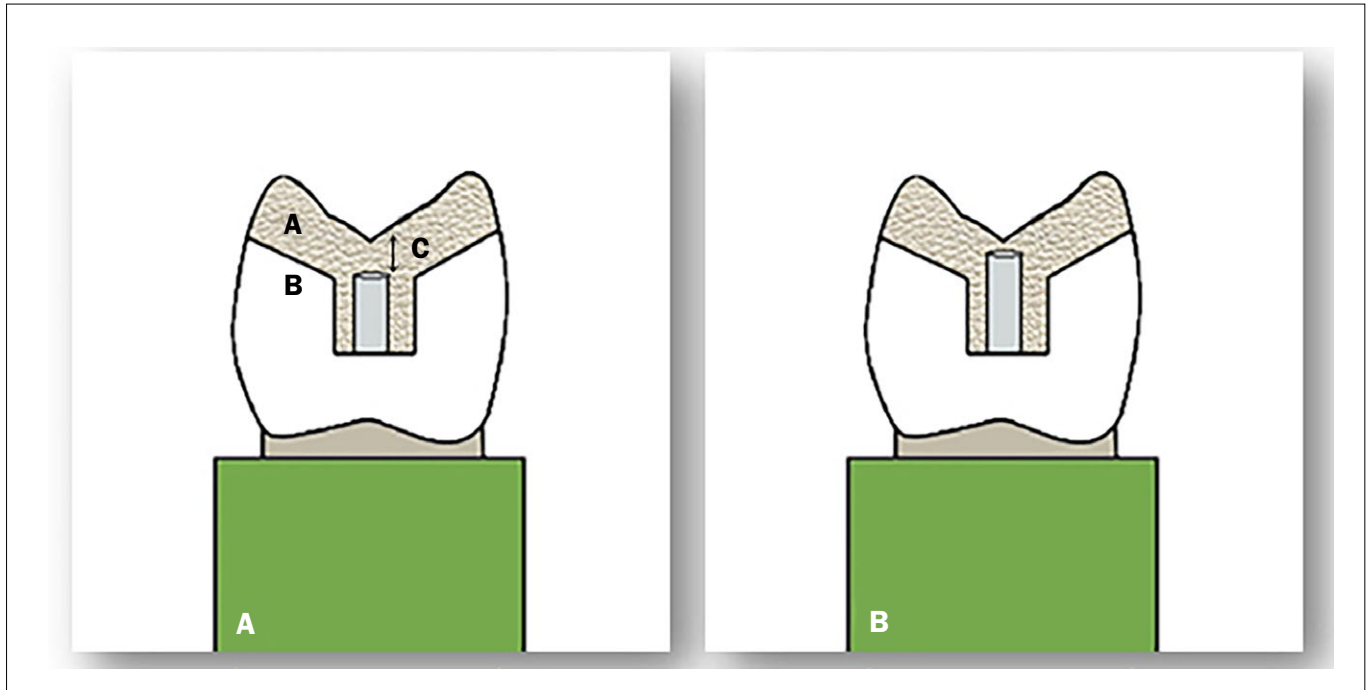
The mesio-occluso-distal (MOD) cavities were then prepared and cusp reduction was performed for teeth in Groups 2-5. The width of MOD cavity at the isthmus was two-thirds of the distance between the two cusp tips. The buccal and lingual walls of the cavity were parallel and the distance from the mesial and distal box floor to the cemento-enamel junction was 1 mm.

After cavity preparation, a few reference grooves were created with 2 mm depth on the cusps using a fissure bur with a 1.5 mm diameter and a digital caliper (Mitutoyo, Tokyo, Japan). Using these reference grooves, buccal and palatal/lingual cusp reduction was performed.

#### *Restorative procedures and FRC post placement*

Size 1 Reforpost Glass Fiber RX posts





**Figure 2**

An overview of the relation between the posts to the occlusal surface.

(A) Composite Build-up Restoration, (B) Reduced Cusps, (C) Distance between post tip and occlusal surface (a: 1.5 millimeters, b: 0.5 millimeters).

(RfX fiber; Ângelus, Londrina, PR, Brazil) were then used. After cavity and post space preparation, the canal and tooth crown were thoroughly rinsed and the fiber post was inserted into the canal. Next, one half of the previously made silicon impression was placed on the respective tooth. Using a digital caliper, in Groups 2 and 4 the post was marked at 1.5 mm and in Groups 3 and 5, 0.5 mm far from the occlusal surface of the tooth, respectively. Using a high-speed hand-piece, the posts were shortened to the marked points (figure 2). Using the other half of silicon impression and a digital caliper, distance of post from the occlusal surface was checked again and then it was removed from the canal. For the cementation of posts, Panavia F2 resin cement (Kuraray-PAN) was used according to the manufacturer's instructions.

The post was soaked in the cement and introduced into the canal. Light curing was performed using a quartz-tungsten-halogen light-curing unit with 705 mW/cm<sup>2</sup> light intensity (SN.851553 Blue Point; AriaLuxe, Tehran, Iran) for 2 seconds. Excess cement was removed and light-curing was continued for another 40 seconds.

After cementation of posts, the teeth were built-up. For this purpose, the remaining tooth structure was etched with 35% phosphoric acid, rinsed and dried. Using a micro-brush, Single Bond (3M ESPE, St. Paul, MN, USA) was applied on etched surfaces, thinned with air spray for 10 seconds from 10 cm distance and light-cured for 20 seconds. Filtek Z250 (shade A2, 3M ESPE, St. Paul, MN, USA) composite was incrementally applied into the cavity using the layering technique until the tooth was completely restored. Each increment had 1 mm thickness and light-cured for 20 seconds. The final increment of composite was applied to the previously made silicon mold and the tooth was then placed in the mold. After removing the excess composite, final curing was performed for 40 seconds.

#### Compressive test

All teeth were then mounted in acrylic resin to 2 mm below their CEJ (simulating the alveolar crest). The teeth were immersed in distilled water and incubated at 37 °C for 24 hours and 1 year. Next, they were transferred to a universal testing machine (Zwick Roell, Ulm, Germany) and subjected to compressive



stress. The load was gradually increased with a crosshead speed of 1 mm/minute until fracture occurred. The maximum load at fracture was recorded in Newtons (N) and indicated the fracture resistance of tooth.

After the fracture, all samples were evaluated by the naked eye and divided into two groups in terms of the location of the fracture line above or below the CEJ. The percentage of each mode of failure was calculated.

Data were statistically analyzed using SPSS version 22 (SPSS Inc., IL, USA). The mean and standard deviation (SD) of fracture resistance in each group were calculated. The Shapiro-Wilk test showed that the data were normally distributed, therefore, data analyzed by Two Way ANOVA and Tukey HSD test. Statistically significant was defined as  $P < 0.05$ .

## Results

Table 1 shows the mean and SD of fracture resistance in the five groups. The highest fracture resistance was noted in Group 1 and the lowest in Group 5. The Shapiro-Wilk test showed that the data were normally distributed in any of the five groups. The Two Way ANOVA test was applied to compare the groups and showed that the groups were significantly different in terms of fracture resistance ( $P < 0.05$ ) but no interaction between factors. Thus, the Tukey HSD

test was applied for pairwise comparisons, which showed that only the difference between the Groups 1 (control) and 5 (0.5 mm thickness) was significant ( $P = 0.02$ ). The difference between other groups was not significant at any time point.

The fracture was evaluated with naked eye and the position of fracture was considered according to the CEJ position. The fracture mode of the specimens is shown in Table 1. Fisher's exact test showed no significant difference among groups in terms of the percentage of modes of failure ( $P = 0.84$ ).

## Discussion

Since premolars are greatly weakened by the process of access cavity preparation and the prevalence of fracture is high in premolar teeth, reinforcement of these teeth is often necessary. Also, premolars often play a role in a beautiful smile and thus, should be necessarily restored with tooth-colored restorative materials (13). So we used this type of teeth for our research. The teeth were standardized in terms of dimensions because these dimensions dictate the size of the access cavity and according to St-Georges et al (14) cavity depth (which is dictated by the height and size of the crown) is the most critical parameter in tooth fracture. An increase by even 1 mm in depth of cavity significantly decreases the fracture resistance

**Table 1**

The mean and standard deviation of fracture resistance and mode of failure in the five groups (n=10)

Groups	Time	Composite thickness (mm)	Mean (N)±SD	Mode of failure%	
				Above CEJ	Under CEJ
1	24h	Intact Teeth	1255.25±280.61	80	20
2		1.5	1146.07±301.80	70	30
3		0.5	971.07±261.34	70	30

of teeth. Cavity width is also important. According to Roberson et al (15) if the isthmus width exceeds one-third of the distance between the cusp tips, cuspal coverage should be considered to reinforce the remaining tooth structure. Cuspal coverage is necessary when the cavity width is two-thirds of the distance between the cusp tips, especially in endodontically treated teeth. According to Linn and Messer (16) loss of the two marginal ridges can weaken the tooth structure by 60%; this negative impact is greater on premolars than molars.

Load distribution in tooth structure is an important factor affecting successful restoration of endodontically treated teeth, which depends on the type of post, core material and its thickness over the post (17, 18). The use of fiber posts is increasing due to their optimal esthetics, mechanical properties, and affordability (19).

Studies on the effect of restorative material thickness over the posts are limited. Tarun et al (17) evaluated the effect of the thickness of composite covering the titanium posts on load distribution in endodontically treated teeth. They showed that increasing the thickness decreased the stress applied to the apical third of the root. However, their

study was conducted on titanium posts and their results cannot be generalized to fiber posts. In this study, no significant difference was noted in fracture resistance of Groups 1 and 2 but the difference between Groups 1 and 5 was significant. Z250 composite used in our study has a modulus of elasticity close to that of dentin (20). Also, the mechanical properties of Angelus fiber post used in our study are highly similar to those of dentin (21). This may explain relatively similar results obtained in most groups. The head of fiber posts cannot be exposed to the oral environment because of the water sorption of their resin component. Microscopic signs of post surface degradation due to water uptake and a loss of structure due to occlusal wear were seen (22). Thus, 0.5 mm composite was the smallest possible thickness of composite on the post. Differences between Groups 1 and 5 can also be due to the brittleness of composite in lower thicknesses (17). The mode of failure of teeth can affect their restoration or may necessitate tooth extraction.

In all groups in our study, 70% of fractures were above the CEJ, which shows that the thickness of composite over the fiber post does not affect the mode of fracture. In a similar study, Reid et al

## References

1. Tyas MJ, Anusavice KJ, Frencken JE, Mount GJ. Minimal intervention dentistry-a review. *Int Dent J* 2000;50(1):1-12.
2. Ericson D, Kidd E, McComb D, Mjör I, Noack MJ. Minimally invasive dentistry-concepts and techniques in cariology. *Oral Health Prev Dent* 2003;1(1):59-72.
3. Tabassum S, Khan FR. Failure of endodontic treatment: The usual suspects. *Eur J Dent* 2016;10(1):144.
4. Sangwan B, Rishi R, Seal M, et al. An in vitro Evaluation of Fracture Resistance of endodontically treated Teeth with Different Restorative Materials. *J Contemp Dent Pract Title* 2016;17(7):549-52.
5. Panahandeh N, Torabzadeh H, Ziaee N, et al. The effect of composite thickness on the stress distribution pattern of restored premolar teeth with cuspal reduction. *J Prosthodont* 2017;26(5):440-5.
6. Alarami N, Sulaiman E, Al-Haddad A. Fracture resistance of endodontically-treated mandibular molars restored with different intra-radicular techniques. *Am J Dent* 2017;30(4):197-200.
7. Lamichhane A, Xu C, Zhang F-q. Dental fiber-post resin base material: a review. *J Adv Prosthodont* 2014;6(1):60-5.
8. Torabzadeh H, Ghassemi A, Sanei M, Razmavar S, Sheikh-Al-Eslami SM. The influence of composite thickness with or without fibers on fracture resistance of direct restorations in endodontically treated teeth. *Iran Endod J* 2014;9(3):215.
9. Xie K, Wang X, Gao X, et al. Fracture resistance of root filled premolar teeth restored with direct composite resin with or without cuspal coverage. *Int Endod J* 2012;45(6):524-9.
10. Peroz I, Blankenstein F, Lange K-P, Naumann M. Restoring endodontically treated teeth with posts and cores—a review. *Quintessence Int* 2005;36(9).
11. Chang W-C, Millstein PL. Effect of design of prefabricated post heads on core materials. *J Prosthet Dent* 1993;69(5):475-82.
12. Nathanson D. *Modern Methods of Restoring Endodontically Treated Teeth: University of British Columbia, Continuing Dental Education; 1992.*



(23) found no significant difference in fracture resistance of teeth restored with quartz, carbon and titanium posts but the type of fracture in teeth restored with fiber post was more favorable. Furthermore, more favorable modes of failure have been reported in teeth restored with direct composite restoration and cuspal coverage. Torabzadeh et al (8) showed that teeth that received cuspal coverage with 2.5 mm thickness had more favorable modes of failure than those restored with 1.5 mm of cuspal coverage. Thus, it may be postulated that teeth restored with direct composite restoration, fiber post placement, and cuspal coverage have modes of failure similar to sound teeth. This study had an in vitro design. Thus, a generalization of results to the clinical setting must be done with caution.

Future studies with larger sample sizes and water storage of teeth are required to assess the behavior of these restorations in the long-term.

### Conclusions

The fracture resistance of endodontically treated teeth restored with a fiber post and 1.5 mm thickness of composite over it along with 2 mm of cuspal coverage after 24h and one year is com-

parable to that of sound teeth. 0.5 mm thickness of composite over fiber post has a significant influence on the reduction of the flexural properties after one year.

It may be concluded that 0.5 mm of composite thickness overlying fiber post seems not to be a reliable choice but 1.5 mm thickness of composite resin covering fiber posts and cuspal reduction of 2 mm, can cause the fracture resistance of endodontically treated teeth to be increased to the level of sound teeth.

### Clinical Relevance

The presented article shows that despite the fact that fiber posts have a comparable modulus of elasticity to dentine and composite, minimum coverage of 1.5 mm is necessary for direct restoration of composite resins.

### Conflict of Interest

The authors declare that they have no conflict of interests.

### Acknowledgments

This research received no specific grant from any funding agency in the public, commercial, or not-for-profit sectors.

13. Mincik J, Urban D, Timkova S, Urban R. Fracture resistance of endodontically treated maxillary premolars restored by various direct filling materials: an in vitro study. *Int J Biomater* 2016;2016.
14. St-Georges AJ, Sturdevant JR, Swift EJ, Thompson JY. Fracture resistance of prepared teeth restored with bonded inlay restorations. *J Prosthet Dent* 2003;89(6):551-7.
15. Roberson T, Heymann H, Ritter A, Pereira P. Classes I, II, and VI direct composite and other tooth-colored restorations. *Art and science of operative dentistry Philadelphia, Mosby* 2006:576-77.
16. Linn J, Messer HH. Effect of restorative procedures on the strength of endodontically treated molars. *J Endod* 1994;20(10):479-85.
17. Tarun K, Meenu B, Goel BR, Patil S. Effects of composite resin core thickness overlying the head of a prefabricated post on the strains produced in apical portion of a root-A parametric evaluation. *ENDODONTOLOGY* 2013;25(2).
18. Kubo M, Komada W, Otake S, et al. The effect of glass fiber posts and ribbons on the fracture strength of teeth with flared root canals restored using composite resin post and cores. *Journal of prosthodontic research* 2018;62(1):97-103.
19. Trushkowsky R. Fiber post selection and placement criteria: a review. *Inside dentistry* 2008;4(4):86-94.
20. Monteiro GQdM, Montes MAJR. Evaluation of linear polymerization shrinkage, flexural strength and modulus of elasticity of dental composites. *Mat Res* 2010;13(1):51-5.
21. Novais VR, Quagliatto PS, Della Bona A, Correr-Sobrinho L, Soares CJ. Flexural modulus, flexural strength, and stiffness of fiber-reinforced posts. *Indian J Dent Res* 2009;20(3):277.
22. Goracci C, Cagidiaco M, Cagidiaco E, et al. Effects of oral environment and occlusal wear on FRC-posts integrity. *J Dent Res* 2007;86:131.
23. Reid LC, Kazemi RB, Meiers JC. Effect of fatigue testing on core integrity and post microleakage of teeth restored with different post systems. *J Endod* 2003;29(2):125-31.



## ORIGINAL ARTICLE/ARTICOLO ORIGINALE

# Use of dynamic navigation with an educational interest for finding of root canals

Usò della navigazione dinamica per un'apertura della camera pulpare minimamente invasiva

**KEYWORDS**

Cone Beam Computer Tomography, Dynamic Navigation, Endodontics training, Minimal Invasive Endodontic, Pulp Chamber

**PAROLE CHIAVE**

Tomografia computerizzata a fascio conico, Navigazione dinamica, Pratica endodontica (Endodontics training), Endodonzia minimamente invasiva, Camera pulpare

**Chiara Pirani<sup>1</sup>****Andrea Spinelli<sup>1</sup>****Claudio Marchetti<sup>2</sup>****Maria Giovanna Gandolfi<sup>1</sup>****Fausto Zamparini<sup>1</sup>****Carlo Prati<sup>1\*</sup>****Gerardo Pellegrino<sup>2</sup>**

<sup>1</sup>School of Dentistry, Department of Biomedical and Neuromotor Sciences (DIBINEM), Alma Mater Studiorum University of Bologna, Italy

<sup>2</sup>Department of Biomedical and Neuromotor Sciences, Oral and Maxillofacial Surgery Unit, University of Bologna, Italy

Received 2019, November 11

Accepted 2020, January 28

**Abstract**

**Aim:** The aim of this technical note was to evaluate the potential application of dynamic navigation in teaching undergraduate students the opening of the access cavity.

**Methodology:** Extracted human teeth were fixed into a prefabricated phantom model in place of the correspondent teeth and pre-operatively scanned with the marker plate containing the fiducial markers with a cone beam computed tomography, imported on the ImplaNav software (ImplaNav, BresMedical, Sydney, Australia) and obtaining a 3D reconstruction. Open access cavity was performed with a diamond bur in using real-time navigation. This procedure was aimed to directly identify the pulp horns and the root canal entrances with a unique hole for each canal.

**Results:** All access cavities were prepared according to a minimally invasive endodontics approach with the dynamically guided ImplaNav software. No perforations occurred and all the canals were successfully located.

**Conclusions:** Present results demonstrated a possible application of this technology for educational purposes in finding root canals. This protocol may have potentialities in teaching dental students to start their approach in endodontic field.

**Obiettivo:** lo scopo di questa nota tecnica è valutare la potenziale applicazione della navigazione dinamica per un rilevamento minimamente invasivo dei canali radicolari.

**Metodologia:** i denti estratti sono stati fissati in un modello prefabbricato al posto dei rispettivi denti in resina e scansionati pre-operativamente con il marker plate e i rispettivi marcatori, attraverso una tomografia computerizzata a fascio conico, importata sul software ImplaNav (ImplaNav, BresMedical, Sydney, Australia) al fine di ottenere una ricostruzione 3D. La cavità di accesso è stata eseguita con una fresa diamantata utilizzando la navigazione dinamica in tempo reale. Questa procedura aveva lo scopo di identificare direttamente i cornetti pulpari e l'accesso a ogni canale radicolare con un'apertura minimamente invasiva.

**Risultati:** tutte le cavità d'accesso sono state preparate secondo un approccio endodontico minimamente invasivo con il software ImplaNav mediante una guida dinamica. Non si sono verificate perforazioni e tutti i canali sono stati localizzati correttamente.

**Conclusioni:** i nostri risultati hanno dimostrato una possibile applicazione di questa tecnologia nella ricerca dei canali radicolari. Questo protocollo può avere potenzialità nell'insegnamento agli studenti di odontoiatria per iniziare il loro approccio in campo endodontico.

**Corresponding author**

Carlo Prati | [carlo.prati@unibo.it](mailto:carlo.prati@unibo.it)

Peer review under responsibility of Società Italiana di Endodonzia

[10.32067/GIE.2020.34.01.02](https://doi.org/10.32067/GIE.2020.34.01.02)

Società Italiana di Endodonzia. Production and hosting by Ariesdue. This is an open access article under the CC BY-NC-ND license (<http://creativecommons.org/licenses/by-nc-nd/4.0/>).



## Introduction

New strategies are being implemented in clinical practice to overcome traditional difficulties in endodontics (1).

Endodontic cavities' design concerning different tooth types have remained unchanged for decades with only negligible modifications (2). Access cavity preparation is one of the most important factors that influences the quantity of the residual dental substance (3) and, consequently, the fracture strength of treated teeth (4). Indeed, root fracture is one of the most significant events which lead to tooth extraction in the long term (5, 6).

In 2010, Clark and Khademi (7) modified the endodontic cavity design to minimize tooth structure removal.

Inspired by the minimally invasive dentistry concept (8), conservative endodontic access cavity (CEC) preparation was proposed by these authors to preserve maximum tooth structure, while partially maintaining the chamber roof and peri cervical dentin.

Some endodontists have taken this concept a step further, designing "ninja" and "truss" endodontic access cavities (NECs and TRECs, respectively).

A NEC consists of a small occlusal entry that should allow the clinician to find and access all of the root canal orifices (3). On the other hand, a TREC consists of direct access from the occlusal surface to each canal orifice, avoiding removal of the whole pulp chamber roof (9).

One of the most critical aspect in endodontic procedures is the detection of root canal orifices in the pulp chamber. The opening of the pulp chamber is the first invasive step of every root canal treatment and is thus crucial for the outcome, stability and longevity of the tooth (1).

Students' perceptions of the difficulties of endodontic treatment are mainly focused on this first step, thus tutors and teachers are usually involved in trying to simplify the clinical approach to improve pulp chamber preparation and the location

of the root canal orifices preventing the destruction of dentinal walls and the perforation of pulp chamber floor (10).

The use of phantoms and other plastic/resin devices to train students is therefore necessary. Unfortunately, some clinical conditions are extremely complex and require an innovative approach to avoid unnecessary risks and damages. Traditionally, a manual approach is required to remove residual dentin-enamel structure and to place the bur close or inside pulp chamber and close to the root orifices. For this reason, studies on new protocols for teaching endodontics are necessary in order to assess the effectiveness of dental care and help with the planning of future dental training (10).

Cone beam computed tomography (CBCT) has been introduced to detect not only periapical (undiagnosed) lesions and anatomy discrepancies, but also to guide the operator in clinical approach when considered difficult (11).

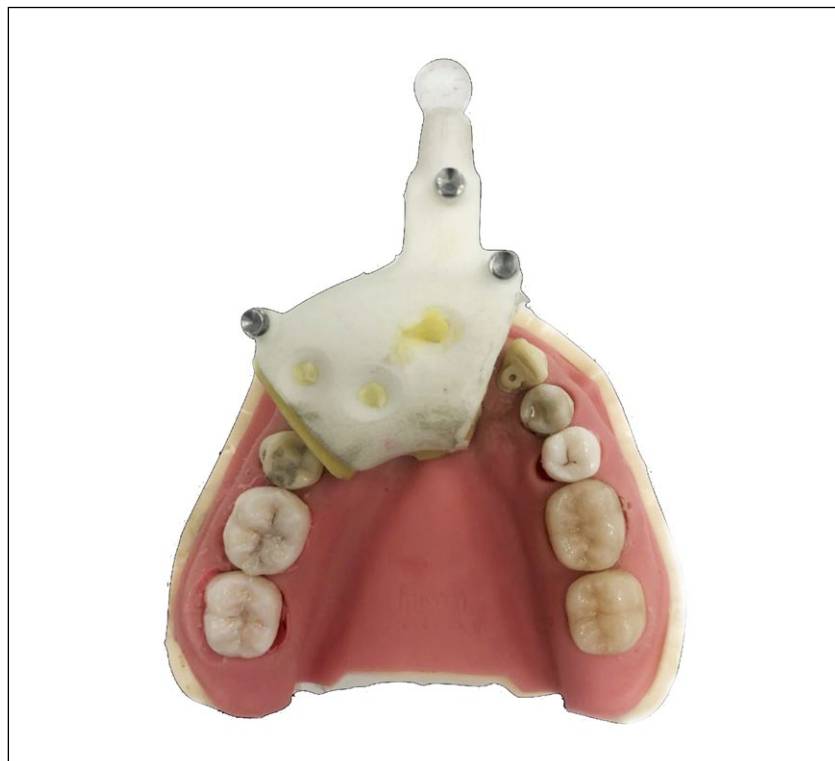
A dynamic navigation system, working on CBCT data and a computer assisted software, able to guide the high-speed handpiece (and bur) to the exact position of orifices may represent a challenging approach. This kind of technology has already been used for dental implantology for several years using the standard drill (12) and it has recently been proposed also with the aid of ultrasonic instruments (13).

The aim of the present research is to evaluate the feasibility of using a dynamic navigation system for minimally invasive Endodontics in addition to presenting an innovative didactical method for the opening of the pulp chamber cavity in order to find the root canal orifices before the endodontic treatment, thus preventing unnecessary alterations of crown morphology.

## Materials and Methods

### *Step 1. Preparation of the tooth model*

Three human teeth extracted for orthodontic reasons were selected, cleaned and stored in distilled water at 4° C for 10 days. Samples were fixed with a light cur-



**Figure 1**

Preparation of phantom tooth model: the marker plate was positioned on the anterior teeth using a silicone mold. The three metal pins were used as reference points to calibrate the dynamic navigation system.

ing resin composite into a prefabricated mouth plastic model (Phantom model) in place of the correspondent resin tooth (figure 1). Out of the extracted teeth, two were lower molars and one was a lower premolar; no one presented previous root canal treatment. A preoperative periapical radiograph of each sample was obtained to verify the dimension of the pulp chamber and the absence of root filling material.

### Step 2. CT scan of the custom model

A dental-supported marker plate tray, provided by the Company, was fixed onto the model, before undergoing a cone-beam computed tomography (CBCT scanning). The markers plate tray (MPT), for dental supported procedure, was manufactured with a base similar to an impression tray and contain on the occlusal side the fiducial markers for calibrating the navigation system. The MPT was placed in situ by the use of Putty impression material (Ramitec, 3M ESPE, USA), according to the protocol of the navigation system manufacturer (ImplaNav, BresMedical, Sydney, Australia). A pre-operative CBCT (VGI,

NewTom, Verona, Italy ) scan (110 kv, 3.00 mA, 0.15 mm, FOV [10×5] HiRes) of the model was taken with the markers plate containing the fiducial markers, in place. CBCT scan of the model was then imported on the ImplaNavig software and a 3D reconstruction model was then obtained.

### Step 3. ImplaNavig Navigation System

The ImplaNavig Navigation System was used for this step (figure 2). ImplaNavig consists of a software interface running in Microsoft Windows (Microsoft), which processes positional data obtained from a stereoscopic infrared camera. In each frame, the firmware of the camera (NDI Polaris Vicra; Northern Digital) identifies the 3D coordinates of a predefined geometric pattern of reflective spheres, which are segmented on-the-fly in the two-dimensional (2D) image obtained from the frame. Therefore, the reflective spheres are located onto two reference tools (RT) which position is identified in real-time by the camera.

The first reference tool is fixed on the model (patient reference tool: RTp) through a spherical connection present on a prominence on the anterior part of the MPT. This allows the navigation system to know in real time the position of the phantom patient.

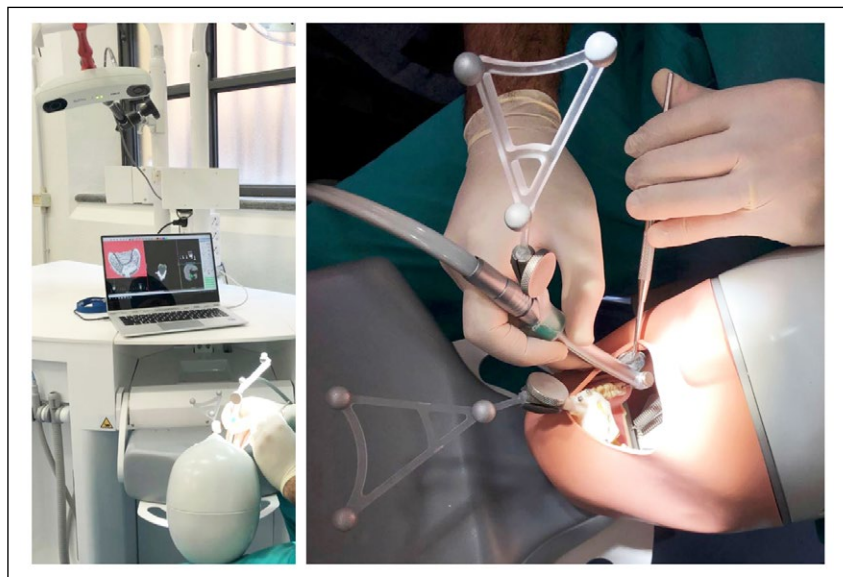
In the same way, the position of the handpiece and consequently of the drill is identified via the second reference tool fixed on the handle (handpiece reference tool: RT<sub>h</sub>) through a screwable connection.

Image-to-world registration of the phantom patient was performed using radiopaque markers embedded in the tooth-supported MPT manufactured in biocompatible plastic. In the lateral sides of the markers plate tray (MPT) are two definite points and via the touching one of these, on the left or on the right side, the handpiece calibration was done.

The calibration was completed with the patient (model) registration by touching three marker points placed on the MPT directly with the bur tip mounted on the handpiece.

This procedure allowed the system to identify in real time the position of the model.





**Figure 2**  
Dynamic guided navigation technique used in the present report.

directly identify the pulp horns and the root canal entrances with a unique hole for each canal. The bur position was virtually followed by the operator on the navigation system screen during all the procedure.

Further preparation was not necessary as the access to the root canals was immediately obtained and verified via the insertion of an endodontic manual instrument. Finally, a postoperative CBCT was taken to radiographically prove the presence of a unique hole for each orifice, from the enamel to the root canal. Different samples were prepared and tested.

**Figure 3**

Operative procedures for Sample 1 (premolar tooth). Occlusal pre-operative aspect (A) and periapical preoperative radiograph (B). Intraoperative photograph (C) and CBCT before access cavity: the green dot represents the tip of the bur in contact with the premolar enamel crown (D). Tip of the bur inside the canal orifices: photograph (E) and CBCT (F), respectively.

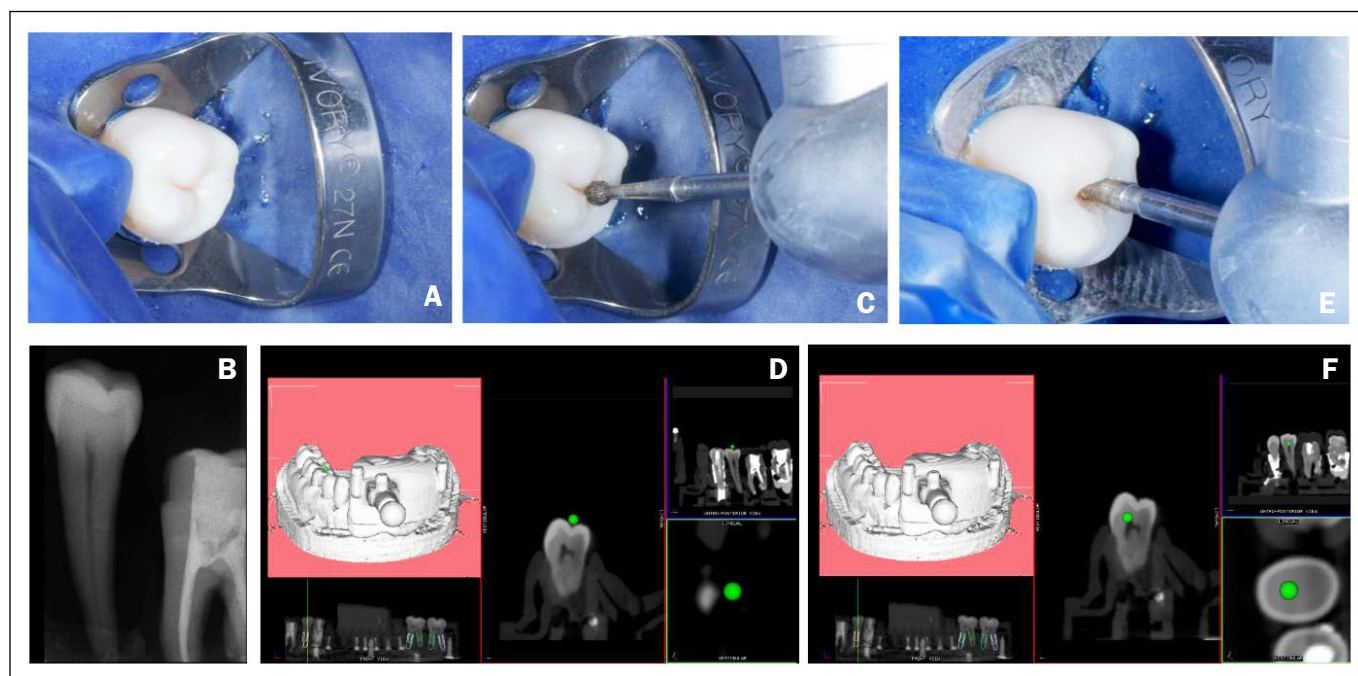
*Step 4. Cavity Preparation and Cavity Navigation*

The preparation of the pulp chamber cavity was performed under the supervision of tutors from a Master's Program, by undergraduate students with a diamond bur in a dynamical way by real-time navigation. Rubber dam isolation (Hygienic Dental Dam, Coltène Whaledent, Cuyahoga Falls, USA) was followed before creating the straight-line access.

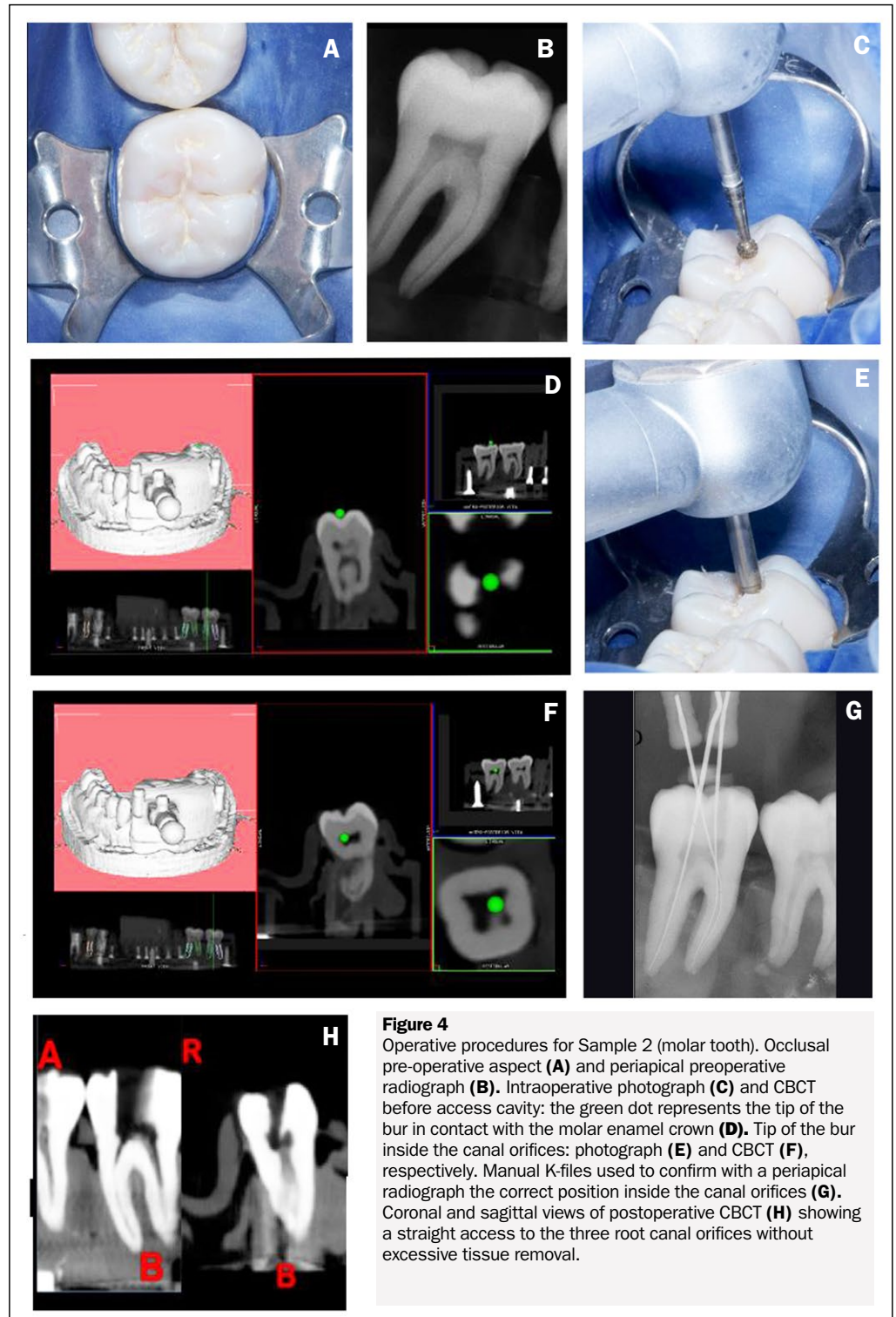
The image-guided procedure aimed to

**Sample 1.** A lower premolar was used to create a minimally invasive access cavity by using a diamond bur mounted on a high-speed handpiece.

Operative information (drilling entry point, depth and angulation of bur insertion) of the precise position of tip bur were indicated by a green dot and checked in real-time on the navigation system display (figure 3).

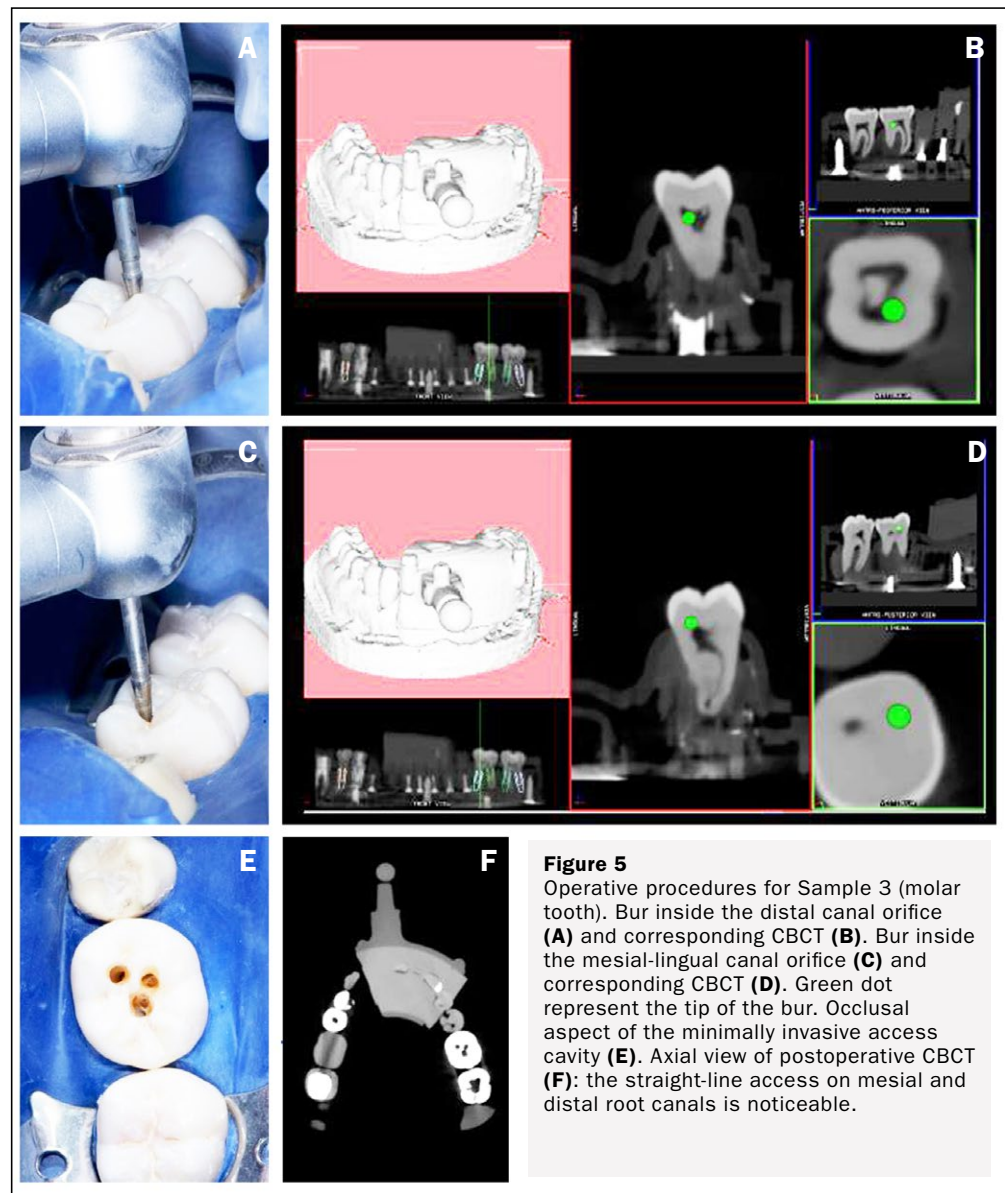






The applied movement was a vertical in and out motion to be as much conservative as possible. After achieving the correct depth in the pulp chamber, a manu-

al K-file #10 (Dentsply Maillefer) was used to confirm with a periapical radiograph the correct position inside the canal orifice.



**Sample 2.** A lower molar was used to create a minimally invasive access cavity by using a diamond bur mounted on a high-speed handpiece. The protocol of pulp chamber opening was the same as previously described for Sample 1, with the only difference that the standard cavity design satisfied the presence of three different orifices (mesiobuccal, mesiolingual and distal, figure 4).

**Sample 3.** A lower molar was used to create a truss access cavity by using a dia-

mond bur mounted on a high-speed handpiece. In this sample, the access to the canal orifices was achieved by removing enamel and dentin in three different points, and creating three different holes on the occlusal surface in correspondence of the three orifices (mesiobuccal, mesiolingual and distal, figure 5). After gaining the access to the canal orifices, postoperative CBCT scans were acquired for each of the included samples.

## Results

A reduced dentinal destruction was noted by observing axial, coronal and sagittal frames.

No perforations were recorded and all the canals were successfully located, by resulting accessible to a K-file. This approach seemed to simplify the pulp chamber opening when the operators were undergraduate students.

## Discussion

The present report describes a new method to identify the root orifices via the use of a dynamic navigation system confirming its applicability for educational purposes. The minimal access cavity allowed to preserve the structure integrity and to localize the root canal orifices with a simplified technique. All access cavities were prepared according to a minimally invasive endodontics approach with the dynamically guided ImplaNav software.

Reduction of the pulp chamber due to the formation of physiological or pathological secondary dentine, presence of blood, tissues, tooth rotation and inclination in the mouth may prevent the localization of the root canals. Straight line access to the root canals is preferable in order to preserve tooth structure and prevent instrument fractures. Peculiar root canal anatomies could be present in teeth, especially in molars where variations in the number and shape of root canals are frequent.

A virtually planned and guided minimal invasive access cavity could enhance the preservation of the tooth structure avoiding perforations, which could lead to an improved long-term prognosis, especially for teeth with calcified root canals (14).

Periapical radiographs do not show the real morphology of the root canal system and several studies have identified CBCT as a superior aid in the detection of various endodontic complications (15).

CBCT enables three-dimensional evaluation of teeth and related structures, and therefore could be considered a preferred imaging modality. CBCT is often used in the field of oral surgery for 3D planning of implant cases, to quantify bone level or to

visualize anatomic structures such as the mandibular nerve canal (16).

However, CBCT offers a static view of the anatomy system and consequently could not provide immediate advantages during the preparation of the access cavity. Although mechanical properties of dentine compared to the alveolar bone are different and may influence accuracy, the use of this computer-aided technique from oral implantology applied to endodontics could be beneficial in producing a minimally invasive access cavity, locating calcified root canals and in endodontic surgery. Several new approaches have been designed and tested regarding the minimally invasive approach in complex root canal treatments, using guided implantology software (1, 17, 18).

However, these experimental procedures were designed in a static model, creating a resin template which should be adapted first to a dental model, then in the oral cavity and the overall dimension of the template has yet to be considered. Dynamic navigation is the most recent free-hand method for computer-aided surgery via an image-guided procedure. New dynamic three-dimensional technology has already occurred in the dental implantology field (19) and could be now applied to Endodontics in order to reduce the treatment invasiveness and avoiding the use of a bulky resin template. A navigation system could give significant aid when scouting the root canal system intraoperatively.

Dynamic guided endodontics may be challenging in clinical practice because it allows a maximum preservation of the dental structure (20), by reducing the encumbrance to the minimum. The dynamic navigation seems to be a useful device to help students to identify the root canal orifices through a fast moving image guided procedure. Up to date, this kind of technology presents some limits for a full application in the Endodontic field.

First, the accuracy declared by the manufacturer companies of about 0.5 mm needs further evaluation to determine whether or not it is sufficient. Secondly, the possible presence of a metal crown could represent another problem due to the radiographic





artifacts. Our initial evaluation of using dynamic navigation for Endodontics seems promising and a worthy method to be further investigated.

The present report seems to show that the system can be useful to identify the coronal third of the root.

### Conclusions

The use of CBCT and the software assisted ImplaNav Navigation System has been tested for the first time in Endodontics at the University of Bologna.

The potentialities of this technique can be identified in teaching the pulp chamber opening and access to the canal orifices in teeth with a modified position (orthodontic reasons) and an altered anatomy.

### Clinical Relevance

Utilization of a dynamic navigation in the endodontic field may provide significant advantages in endodontic training as a didactic tool to find the root canals. In addition, this technology would be useful in complex retreatment cases or in presence of sclerotic root canals.

### Conflict of Interest

The authors deny any conflicts of interest related to this report.

### Acknowledgments

The report was self-funded.

## References

- Zehnder MS, Connert T, Weiger R, Krastl G, Kühl S Guided endodontics: accuracy of a novel method for guided access cavity preparation and root canal location. *International Endodontic Journal* 2016; 49:966-72.
- Patel S, Rhodes J A practical guide to endodontic access cavity preparation in molar teeth. *British Dental Journal* 2007; 203:133-140.
- Plotino G, Grande NM, Isufi A, Ioppolo P, Pedullà E, Bedini R, Gambarini G, Testarelli L Fracture Strength of Endodontically Treated Teeth with Different Access Cavity Designs. *Journal of Endodontics* 2017; 43:995-1000.
- Corsentino G, Pedullà E, Castelli L, Liguori M, Spicciarelli V, Martignoni M, Ferrari M, Grandini S Influence of Access Cavity Preparation and Remaining Tooth Substance on Fracture Strength of Endodontically Treated Teeth. *Journal of Endodontics* 2018; 44:1416-1421.
- Prati C, Pirani C, Zamparini F, Gatto MR, Gandolfi MG A 20-year historical prospective cohort study of root canal treatments. A Multilevel analysis. *International Endodontic Journal* 2018; 51:955-968.
- Pirani C, Zamparini F, Peters OA, Iacono F, Gatto MR, Generali L, Gandolfi MG, Prati C The fate of root canals obturated with Thermafil: 10-year data for patients treated in a master's program. *Clinical Oral Investigation* 2019 in press doi: 10.1007/s00784-019-02882-4.
- Clark D, Khademi JA Case studies in modern molar endodontic access and directed dentin conservation. *Dental Clinics North America* 2010; 54:275-289.
- Gluskin AH, Peters C, Peters OA. Minimally invasive endodontics: challenging prevailing paradigms. *Br Dent J* 2014; 216:347-53.
- Buchanan LS Endodontic Shaping Procedures: The Past, Present, and Near Future. *Dentistry Today* 2015; 34:104-107.
- Eleftheriadis GI, Lambrianidis TP. Technical quality of root canal treatment and detection of iatrogenic errors in an undergraduate dental clinic. *Int Endod J* 2005; 38:725-34.
- Patel S, Patel R, Foschi F, Mannocci F The Impact of Different Diagnostic Imaging Modalities on the Evaluation of Root Canal Anatomy and Endodontic Residents' Stress Levels: A Clinical Study. *Journal of Endodontics* 2019; 45:406-413.
- Casap N, Tarazi E, Wexler A, Sonnenfeld U, Lustmann J Intraoperative computerized navigation for flapless implant surgery and immediate loading in the edentulous mandible. *International Journal of Oral Maxillofacial Implants* 2005; 20:92-8.
- Pellegrino G, Taraschi V, Vercellotti T, Ben-Nissan B, Marchetti C Three-Dimensional Implant Positioning with a Piezosurgery Implant Site Preparation Technique and an Intraoral Surgical Navigation System: Case Report. *International Journal of Oral Maxillofacial Implants* 2017; 32:163-165.
- Lara-Mendes STO, Barbosa CFM, Machado VC, Santa-Rosa CC A new approach for minimally invasive access to severely calcified anterior teeth using the guided endodontics technique. *Journal of Endodontics* 2018; 44:1578-1582.
- Ee J, Fayad MI, Johnson BR Comparison of endodontic diagnosis and treatment planning decisions using cone-beam volumetric tomography versus periapical radiography. *Journal of Endodontics* 2014; 40:910-916.
- Yang XW, Zhang FF, Li YH, Wei B, Gong Y Characteristics of intrabony nerve canals in mandibular interforaminal region by using cone-beam computed tomography and a recommendation of safe zone for implant and bone harvesting. *Clinical Implant Dentistry Related Research* 2017; 19:530-538.
- Connert T, Zehnder MS, Amato M, Weiger R, Kühl S, Krastl G Microguided endodontics: a method to achieve minimally invasive access cavity preparation and root canal location in mandibular incisors using a novel computer-guided technique. *International Endodontic Journal* 2018; 51:247-255.
- Connert T, Zehnder MS, Weiger R, Kühl S, Krastl G Microguided endodontics: accuracy of a miniaturized technique for apically extended access cavity preparation in anterior teeth. *Journal of Endodontics* 2017; 43:787-790.
- Pellegrino G, Taraschi V, Zacchino A, Ferri A, Marchetti C Dynamic Navigation: A Prospective Clinical Trial to Evaluate the Accuracy of Implant Placement. *International Journal of Computer Dentistry* in press 2019.
- Lara-Mendes STO, Barbosa CFM, Santa-Rosa CC, Machado VC Guided endodontic access in maxillary molars using cone-beam computed tomography and computer-aided design/computer-aided manufacturing system: a case report. *Journal of Endodontics* 2018; 44:875-879.



## ORIGINAL ARTICLE/ARTICOLO ORIGINALE

# Sonic vs Ultrasonic activation of sodium hypochlorite for root canal treatments. In vitro assessment of debris removal from main and lateral canals

**KEYWORDS**

Root canal irrigation, Sodium hypochlorite, Sonic activation, Ultrasonic activation, Accessory canals

**PAROLE CHIAVE**

Irrigazione canalare, ipoclorito di sodio, Attivazione sonica, Attivazione ultrasonica, Canali accessori

*Attivazione Sonica vs attivazione Ultrasonica dell'ipoclorito di sodio per i trattamenti endodontici. Valutazione in vitro della rimozione dei detriti dai canali principali e laterali*

**Abstract**

**Aim:** Aim of this study is to evaluate the efficacy of two different sonic and ultrasonic devices in the elimination of debris from artificial main and accessory canals.

**Methodology:** Two different irrigant activator devices were tested: the sonic handpiece Endo-Activator (Dentsply Maillefer, Baillagues, Switzerland) and the ultrasonic handpiece Ultra X (Eighteeth, Changzhou Sifary Medical Technology Co., Ltd, Changzhou City, China). Two groups of 18 artificial root canals were analyzed (n=36): main and lateral canals were embedded in a transparent resin model. Canals were filled with organic paste to simulate the necrotic pulp tissues. With both devices, irrigation was performed using 5% sodium hypochlorite and two activation times of 30 seconds each. Sodium hypochlorite was replaced every 30 seconds. After a photographic exam, debris removal was evaluated by a software and assessed in terms of percentage of cleaned canal. Means and standard deviations were calculated and data were statistically analyzed with the Anova test.

**Results:** Under the same experimental conditions (same canal, time and irrigant), both sonic and ultrasonic devices completely cleaned the

**Obiettivo:** la valutazione dell'efficacia di due differenti apparecchiature, una sonica e un'altra ultrasonica, per l'eliminazione dei residui dentinali dai canali endodontici principali e accessori.

**Metodologia:** sono stati testati due diversi attivatori per irriganti endocanalari: il manipolo sonico per irriganti endocanalari: il manipolo sonico EndoActivator (Dentsply Maillefer, Baillagues, Switzerland) e il manipolo ultrasonico Ultra X (Eighteeth, Changzhou Sifary Medical Technology Co., Ltd, Changzhou City, China). Sono stati analizzati 18 canali artificiali per ciascuno dei due gruppi presi in esame (n=36): i canali principali e laterali sono stati creati all'interno di blocchi in resina trasparenti.

È stata introdotta una pasta organica nei canali per simulare la consistenza dei tessuti pulpari necrotici. Con entrambe le strumentazioni sono state effettuate due attivazioni da 30 secondi ciascuna, utilizzando ipoclorito di sodio al 5%. Dopo un esame fotografico, la rimozione dei tessuti è stata valutata attraverso l'uso di un software e riportato in percentuali: sono state calcolate le medie le deviazioni standard e i risultati sono stati analizzati statisticamente attraverso il test Anova.

**Risultati:** alle stesse condizioni sperimentali, (stesso canale, tempo di irrigazione e irrigante), entrambi i dispositivi hanno deterso completamente il canale

Gianluca Gambarini<sup>1</sup>

Gabriele Miccoli<sup>1</sup>

Stefano Di Carlo<sup>1</sup>

Giulia Iannarilli<sup>1</sup>

Greta Lauria<sup>1</sup>

Dario Di Nardo<sup>1\*</sup>

Marco Seracchiani<sup>1</sup>

Tatyana Khrenova<sup>1</sup>

Maurizio Bossù<sup>1</sup>

Luca Testarelli<sup>1</sup>

<sup>1</sup>Department of Oral and Maxillo-Facial Sciences, Sapienza University of Rome, Italy

Received 2019, November 21

Accepted 2020, February 11

**Corresponding author**

Dario Di Nardo | Department of Oral and Maxillo Facial Sciences Sapienza University of Rome | Italy  
Tel. +39 339 393 5527 | [dario.dinardo@uniroma1.it](mailto:dario.dinardo@uniroma1.it)

Peer review under responsibility of Società Italiana di Endodonzia

[10.32067/GIE.2020.34.01.12](https://doi.org/10.32067/GIE.2020.34.01.12)

Società Italiana di Endodonzia. Production and hosting by Ariesdue. This is an open access article under the CC BY-NC-ND license (<http://creativecommons.org/licenses/by-nc-nd/4.0/>).



## Abstract

main canal. On the contrary, a statistically significant difference was noted in the debridement of lateral canals, with ultrasonic device removing more debris than the sonic one ( $p < 0.05$ ). No tested device was able to remove all debris from accessory canals.

**Conclusions:** The cordless ultrasonic hand-piece Ultra X used with maximum power showed significantly greater efficacy in cleaning accessory canals when compared to the sonic EndoActivator.

principale. Al contrario, è stata evidenziata una differenza statisticamente significativa nella detersione dei canali laterali, con una migliore performance del dispositivo ultrasonico rispetto a quello sonico ( $p < 0.05$ ). Nessun dispositivo è stato in grado di rimuovere completamente i residui dai canali accessori.

**Conclusioni:** il dispositivo a ultrasuoni Ultra X utilizzato alla massima potenza ha dimostrato un'efficacia significativamente superiore rispetto al dispositivo sonico EndoActivator nella detersione dei canali laterali.

## Introduction

**R**emains of pulpal debris and bacteria in the dental root canal are the principal cause of endodontic treatment's failure: only a complete disinfection and subsequent obturation of the endodontic space could lead to success (1, 2). Satisfying instrumentation and irrigation are considered mandatory to decrease the amount of bacteria and necrotic tissues within the root canal system (3-5). In the last decades, research was mainly focused on improving shaping of the root canal with many new instruments and techniques (6-11). However, irrigation still plays a fundamental role in the root canal therapy and it should be never underestimated (12-14). Mechanical instrumentation is not able to clean all the root canal system, and remaining biofilms and infected debris can be a possible source of persistent infection and treatment failure (15). The main factors that prevent complete debridement are: the polymicrobial nature of bacteria and their organization in biofilm, the presence of the smear layer produced by instrumentation, but above all, the complex root canal anatomy that hinders the instrumentation and the penetration of the irrigants in unreachable areas of the root canal system, like fins, accessory canals and isthmuses (16). Therefore, the irrigants should be acti-

vated inside canals by proper devices to increase the amount of contact with pulp tissue and debris inside canals.

Many articles tested and compared ultrasonic and sonic devices for irrigants activation (17-21); the main function of sonic handpieces is to produce a vigorous movement of the intracanal liquid through "cavitation" and "acoustic streaming". By activating the flow of irrigants, bubbles are produced, so they expand, become unstable and subsequently collapse in an implosion. This can dissolve impurities and penetrate powerfully into the channels, breaking bacterial biofilms and clean surfaces.

Many different sonic and ultrasonic devices have been commercialized during the last decades. Among sonic devices, Endoactivator (Dentsply Maillefer, Bailagues, Switzerland) is the most studied (22-24); ultrasonic devices, using higher frequencies, create vibrations that produce a continuous current close to the file, keeping the irrigant moving continuously. Eighteeth Ultra X (Eighteeth, Changzhou Sifary Medical Technology Co., Ltd, Changzhou City, China) is a new ultrasonic battery operated device. No studies have been published so far on this device.

Aim of this study is to compare the in vitro efficacy of the two above mentioned sonic and ultrasonic devices in the elimination of debris from canal irregularities in artificial root canals.

## Materials and Methods

Power analysis was performed to evaluate sample size. A transparent resin model simulating a radicular canal was divided into two parts of equal thickness and adopted for this study (figure 1). Model and testing methodology have been validated in a previous study (12). The dimensions of the resin model were 10 mm length and 2.5 mm width. Both parts were specular, with a depression inside, at the same level, so that once assembled (by means of two screws) each depression overlapped to its counterpart to reproduce the lumen of a root canal. The canals were embedded with three semi-circular cavities, simulating the presence of irregular lateral canals at different levels (coronal, middle and apical). The three semicircles per side were filled with organic paste similar in consistency and density to the dental pulp, simulating the debris accumulated in the non-instrumented areas of the root canal. Organic paste was obtained by crushing bovine dental pulp and add a bit of dark stain (tempera colour) for better visualization.

The same simulator of the root canal was employed for both groups and the test was repeated 3x3 times for each experimental group (18 repetitions in total). The same irrigation procedure was adopted for all the tests: a 2,5 cc Luer-lock sterile


syringe with endodontic needle (Navi Tip, Ultradent, Utah, USA) was placed at 1 mm from the working length (WL). 5% sodium hypochlorite (Ogna, Muggiò, Italy) was activated for 1 minute per procedure. The protocol used for both groups tested was the one suggested by the manufacturer in their instructions for use and included the following phases:


1. First irrigation with a disposable sterile syringe with endodontic needle (2,5 cc 5% NaOCl)
2. Activation time 30 sec.
3. Second irrigation with a disposable sterile syringe with endodontic needle (2,5 cc 5% NaOCl)
4. Activation time 30 sec.

For the group 1, the sonic handpiece EndoActivator was used at the maximum power of 10 kHz. The selected activator tip was a 25.04 red insert, used by following manufacturer instructions. For the group 2, the ultrasonic handpiece Ultra X worked at the maximum power of 45 kHz, using the soft and flexible X Silver tip. In both cases, the selected activator tip fitted passively when placed 2 mm short from the working length. The irrigant solution was activated using short vertical strokes for 30 seconds.

Digital photographs of the artificial canals were taken before, during and after the activation, due to record the amount of debridement. The resulting images were viewed and analyzed using a default

**Figure 1**  
The transparent resin block containing artificial canals: block can be split in two halves for better placement of organic material inside and then reassembled.





**Figure 2**

The artificial canal was divided in sectors, allowing more precise and easier visualization of the debridement.

template, realized with a computer-aided technical drawing program (AutoCAD® 2012, Autodesk, San Rafael, USA). The percentages obtained were derived from a graphic interpretation of the results. Specifically, each section in which the artificial channel was divided (coronal, middle and apical third), was further divided into 10 parts, considering both the main channel and the lateral canal irregular extensions (figure 2). At the end of the irrigant activation process, it was made a percentage calculation of the parts that visually appeared to be completely cleaned. Means and standard deviations were statistically analyzed with Anova test to highlight the differences in the ratios of removed debris between groups. The level of significance was set at  $p=0.05$ .

## Results

Results are shown in table 1. Shapiro-Wilk was performed to verify the normality of data. Both sonic and ultrasonic irrigant activators completely cleaned the main canal of all resin models, while statistically relevant differences have been found in cleaning the lateral canals. Ultrasonic handpiece statistically removed more debris than the sonic one ( $p < 0.05$ ), but none of the tested devices completely removed debris from lateral canals.

## Discussion

The majority of ultrasonic handpiece are electric devices with plug-in or handpieces to be connected to the dental unit. The new handpiece is cordless, light in weight, very easy to handle, store, transport and use, even if it is not connected to a source of irrigating solution. The main advantage of a cordless handpiece is the easier practical use, but there are some concerns about efficacy. More precisely, the power of cordless handpieces is sometimes not predictable, due to problems related to battery and charge. A lower input from battery could easily generate a vibration with reduced frequency, thus reducing the effectiveness of ultrasonic activation. So far, research about improving endodontic

irrigation followed two parallel paths: the search for more effective and diffusible irrigants and the search for improved irrigant activation. Different irrigating solutions have been used throughout the years and, among them, sodium hypochlorite has proved to be the best solution (19, 25). Data from literature clearly demonstrated that the increase in temperature has the effect of enhancing the solvent action on the collagen of the hypochlorite, while the bactericidal activity is influenced by the concentration and the time of contact with the bacteria; the optimal concentration is considered to be 5.25% (26). The bactericidal action is carried out in 2-5 minutes, if there is a direct contact between hypochlorite and bacteria. Mechanical activation of sodium hypochlorite is considered capable to increase tissue dissolution and its agitation could provide a continuous flow of renewed chlorine (17, 18).

Disinfection and debridement could be improved by different irrigation delivery devices which use sonic, ultrasonic and negative pressure. In the last decades many new devices and techniques have been proposed for the purpose, but still there is no consensus on which one is the most reliable and efficient for the clinical use (20). Besides the concepts of positive and negative pressure, the differences amongst devices are mainly based on the source and quantity of the released energy, but in similar devices, the conformation of the tip could reach different results.

Aim of this study was to compare the efficacy of sonic and ultrasonic devices for the cleanliness of canal irregularities using the following similar parameters: anatomy, irrigant, activation time and amount of residuals. Results showed that both sonic and ultrasonic irrigant activators completely cleaned the main canal of all resin models, while statistically relevant differences have been found in cleaning the lateral canals. Statistical analysis revealed that the ultrasonic handpiece removed more debris than the sonic one ( $p < 0.05$ ). Such difference can be explained by the fact that a more efficient transmission of energy allows a better irrigant activation and progression in endodontic



**Table 1**

**Percentage of debris removal between Endoactivator and Eighteeth experimental groups**

Activation	1	2	3	4	5	6	7	8	9	Mean	Std.Dev
<b>Endoactivator (S) main canal</b>	100	100	100	100	100	100	100	100	100	100	0
<b>Eighteeth (US) main canal</b>	100	100	100	100	100	100	100	100	100	100	0
<b>Endoactivator (S) accessory canal</b>	60	58	55	47	64	61	44	58	72	57,66a	8,44
<b>Eighteeth (US) accessory canal</b>	72	69	80	71	82	70	74	68	73	73,22a	4,81

Ultrasonic (US) activation removed a larger amount of debris when compared to sonic (S) one in the accessory canals in all tests. Main canal debris removal was complete in all cases for both groups. Results showing significative differences are evidenced by upper letter (a).

spaces (like lateral canals, isthmus etc) which are not instrumented or directly reached by the tip of the sonic/ultrasonic device. This experimental condition simulates a clinical situation where tips are inserted in the main canal. A better flow and activation of the irrigant results in increased debridement.

The results showed that there is a significant difference between the sonic and ultrasonic devices, with the last one showing significantly better removal for organic tissues.

A possible explanation is that sonic devices were less efficient, mainly due to their lower power and lower frequency of vibration (25, 27, 28, 29). Typically, a sonic device operates at 1-8 kHz and ultrasonic at 25-40 kHz (30). The efficacy is related to the power of the units. The Eighteeth device has only two selectable values of power and for this study it was used the higher one. The provided power, even if derived from a battery, has proved efficacy, but it should be compared to non-cordless ultrasonic units to appreciate differences, if any. A cordless device makes the handpiece more ergonomic and easy to use, even if special cares have to be

paid to ensure that the ultrasonic handpiece is always properly charged.

Efficacy is also related to the possibility to insert the tip in the apical portion of canal. In this in vitro study, artificial main canals were wide and straight, allowing easier placement of tips. All main canals were adequately cleaned by both devices. Clinically in curved canals, efficacy could also be dependant on the flexibility of the files/tips (17).

The current increase of the use of cone beam in endodontic practice, has clearly shown clinically more complex anatomies than expected, underlining the necessity to improve our shaping and cleaning procedures (31, 32).

According to literature, if sonic handpiece is used under 2 mm of the working length it may cause extrusion of irrigant over the apex. Another issue could be evidenced when the size of the apical part of the preparation is too narrow respect to the size of the vibrating tip: once forced by the dentinal walls, the cavitation and movement of the irrigant could be ineffectual (33). However, sonic devices are considered



safer than ultrasonic ones because they are embedded with oscillating plastic point which doesn't stop when in contact with the canal surfaces and it doesn't deform the root canal (12). In fact, ultrasonic files are made of metal alloy, therefore, when they touch the root canal wall, this may cause uncontrolled removal of dentin, with deformation of the root canal morphology (34). Most of the studies about ultrasounds were performed using electric plug-in devices with cord, while only a few ones investigated cordless handpieces. Due to different power supply cordless and plug-in devices are supposed operate at slightly different frequencies (usually varying from 30 to 50 kHz). A small difference was reported to have no effect on the treatment outcome (35). The two different kind of devices are assumed to operate with similar ultrasonic induced flow patterns. In the ultrasonic instrument oscillation, the pressure waves

generate acoustic streaming and cavitation, with the main flow factor appears to be acoustic microstreaming.

The present study is the first one which evaluates and compare in vitro performance of the new handpiece. Ultra X works at 45 kHz, by utilizing acoustic microstreaming, agitation and cavitation. Frequency can be modified by the operator that could optimize the efficacy of the tips during the debridement.

In the present study, two activation times of 30 seconds each were used, according to the clinical protocol established at the beginning of the trial. The test, for the two groups, was conducted under the same conditions and by the same operator, however there are some limitations to keep in mind: the in vitro model used in this study was an artificial root canal with artificial lateral extensions simulating inaccessible areas of the main root canal; the organic

## References

- Gambarini G, Di Nardo D, Miccoli G, et al. The Influence of a New Clinical Motion for Endodontic Instruments on the Incidence of Postoperative Pain. *Clin Ter.* 2017;168:e23-e27.
- Gambarini G, Piasecki L, Miccoli G, Gaimari G, Di Giorgio R, Di Nardo D, Azim AA, Testarelli L. Classification and cyclic fatigue evaluation of new kinematics for endodontic instruments. *Aust Endod J.* 2019;45:154-162.
- De Gregorio C, Estevez R, Cisneros R et al. Efficacy of different irrigation and activation systems on the penetration of sodium hypochlorite into simulated lateral canals and up to working length: An in vitro study. *J Endod.* 2010;36:1216-1221.
- Gambarini G, Testarelli L, Galli M et al. The effect of a new finishing process on the torsional resistance of twisted nickel-titanium rotary instruments. *Minerva Stomatol.* 2010;59:401-6.
- Gambarini G, Tucci E, Bedini R et al. The effect of brushing motion on the cyclic fatigue of rotary nickel titanium instruments. *Ann Ist Super Sanita.* 2010;46:400-4.
- Gambarini G, Galli M, Di Nardo D et al. Differences in cyclic fatigue lifespan between two different heat treated NiTi endodontic rotary instruments: WaveOne Gold vs EdgeOne Fire. *J Clin Exp Dent.* 2019;11:e609-e613.
- Gambarini G, Miccoli G, Seracchiani M et al. Role of the Flat-Designed Surface in Improving the Cyclic Fatigue Resistance of Endodontic NiTi Rotary Instruments. *Materials (Basel).* 2019;12:E2523.
- Di Nardo D, Galli M, Morese A et al. A comparative study of mechanical resistance of two reciprocating files. *J Clin Exp Dent.* 2019;11:e231-e235.
- Gambarini G, Seracchiani M, Piasecki L et al. Measurement of torque generated during intracanal instrumentation in vivo. *Int Endod J.* 2019;52:737-745.
- Di Nardo D, Galli M, Morese A et al. A comparative study of mechanical resistance of two reciprocating files. *J Clin Exp Dent.* 2019;11:e231-e235.
- Gambarini G, Miccoli G, Seracchiani M et al. Fatigue Resistance of New and Used Nickel-Titanium Rotary Instruments: a Comparative Study. *Clin Ter.* 2018;169:e96-e101.
- Plotino G, Grande NM, Mercade M et al. Efficacy of sonic and ultrasonic irrigation devices in the removal of debris from canal irregularities in artificial root canals. *J Appl Oral Sci.* 2019;27:e20180045.
- Plotino G, Cortese T, Grande NM et al. New Technologies to Improve Root Canal Disinfection. *Braz Dent J.* 2016;27:3-8.
- Gambarini G. Shaping and cleaning the root canal system: a scanning electron microscopic evaluation of a new instrumentation and irrigation technique. *J Endod.* 1999;25:800-3.
- Ricucci D, Siqueira JF, Bate AL et al. Histologic Investigation of Root Canal-treated Teeth with Apical Periodontitis: A Retrospective Study from Twenty-four Patients. *J Endod.* 2009;493-502.
- Ricucci D, Siqueira JF. Fate of the tissue in lateral canals and apical ramifications in response to pathologic conditions and treatment procedures. *J Endod.* 2010;36:1-15.
- Walmsley AD, Williams AR. Effects of constraint on the oscillatory pattern of endosonic files. *J Endod.* 1989;15:189-194.
- De Gregorio C, Estevez R, Cisneros R et al. Effect of EDTA, Sonic, and Ultrasonic Activation on the Penetration of Sodium Hypochlorite into Simulated Lateral Canals: An In Vitro Study. *J Endod.* 2009;35:891-895.



material present in the real canals was simulated by using a paste with a consistency similar to the pulpal tissues; differently from the natural teeth, plastic canals were poor of irregularities; lateral canals were larger than natural ones and activation was performed always at the same level (12). Another limitation of this study is the fact that the assessment of debridement was only two-dimensional, so it was not possible to precisely measure the amount of residual tissues in all the canal complexities.

### Conclusions

Both sonic and ultrasonic activation demonstrated a good capacity for debris removal in the main canal, but in the present experimental model, the Ultra X ultrasonic system significantly removed more debris from lateral extensions than the EndoActivator sonic system.

### Clinical Relevance

Endodontic irrigation is mandatory for a successful root canal treatment. Devices for mechanical irrigation could improve the irrigant diffusion through main and accessory canals for a better disinfection.

### Conflict of Interest

The authors deny any conflict of interests.

### Acknowledgments

The authors would like to thank Eighteeth, Changzhou Sifary Medical Technology Co., Ltd, Changzhou City, China, for providing the Ultra X device for the experimental purposes.

## References

- Zehnder M. Root Canal Irrigants. *J Endod.* 2006;32:389-398.
- Gu L sha, Kim JR, Ling J et al. Review of Contemporary Irrigant Agitation Techniques and Devices. *J Endod.* 2009;35:791:804.
- Plotino G, Pameijer CH, Maria Grande N et al. Ultrasonics in Endodontics: A Review of the Literature. *J Endod.* 2007;33:81-95.
- Pedullà E, Genovese C, Messina R et al. Antimicrobial efficacy of cordless sonic or ultrasonic devices on *Enterococcus faecalis*-infected root canals. *J Investig Clin Dent.* 2019 Jul 11:e12434. [Epub ahead of print].
- Abraham S, Vaswani SD, Najan HB et al. Scanning electron microscopic evaluation of smear layer removal at the apical third of root canals using diode laser, endoActivator, and ultrasonics with chitosan: An in vitro study. *J Conserv Dent.* 2019;22:149-154.
- Haupt F, Meinel M, Gunawardana A et al. Effectiveness of different activated irrigation techniques on debris and smear layer removal from curved root canals: a SEM evaluation. *Aust Endod J.* 2019 Mar 25. [Epub ahead of print].
- Arslan H, Capar ID, Saygili G et al. Efficacy of various irrigation protocols on the removal of triple antibiotic paste. *Int Endod J.* 2014;47:594-9.
- Rodrigues PA, Franco Nassar RS, da Silva TS et al. Effects of Different NaOCl Concentrations Followed by 17% EDTA on Dentin Permeability. *J Contemp Dent Pract.* 2019;20:838-841.
- Bolles JA, He J, Svoboda KKH, Schneiderman E et al. Comparison of vibringe, endoactivator, and needle irrigation on sealer penetration in extracted human teeth. *J Endod.* 2013;39:708-11.
- Klyn SL, Kirkpatrick TC, Rutledge RE. In vitro comparisons of debris removal of the EndoActivator™ System, the F File™, ultrasonic irrigation, and NaOCl irrigation alone after hand-rotary instrumen-
- tation in human Mandibular molars. *J Endod.* 2010;36:1367-71.
- Mancini M, Cerroni L, Iorio L et al. Smear layer removal and canal cleanliness using different irrigation systems (EndoActivator, EndoVac, and passive ultrasonic irrigation): Field emission scanning electron microscopic evaluation in an in vitro study. *J Endod.* 2013;39:1456-60.
- Sabins RA, Johnson JD, Hellstein JW. A comparison of the cleaning efficacy of short-term sonic and ultrasonic passive irrigation after hand instrumentation in molar root canals. *J Endod.* 2003;29:674-8.
- Boutsoukis C, Lambrianidis T, Kastrinakis E et al. Measurement of pressure and flow rates during irrigation of a root canal ex vivo with three endodontic needles. *Int Endod J.* 2007;40:504-13.
- Gambarini G, Piasecki L, Ropini P et al. Cone-beam computed tomographic analysis on root and canal morphology of mandibular first permanent molar among multiracial population in Western European population. *Eur J Dent.* 2018;12:434-438.
- Valenti-Obino F, Di Nardo D, Quero L et al. Symmetry of root and root canal morphology of mandibular incisors: A cone-beam computed tomography study in vivo. *J Clin Exp Dent.* 2019;11:e527-e533.
- Lea SC, Felver B, Landini G et al. Ultrasonic scaler oscillations and tooth-surface defects. *J Dent Res.* 2009;88:229-34.
- Mikulik R, Naji A, van der Hoeven R. et al. Efficacy evaluation of a cordless ultrasonic unit in achieving reduction of bacterial load within a root canal system as compared to a conventional ultrasonic unit and negative pressure irrigation. *Evid based endod.* 2019;4:2.

## ORIGINAL ARTICLE/ARTICOLO ORIGINALE

# Accuracy, sensitivity and specificity of three imaging modalities in detection of separated intracanal instruments

**KEYWORDS**

Accuracy, CBCT, Nickel Titanium, PSP, Radiography, Separated Instrument

**PAROLE CHIAVE**

Precisione, CBCT, Nichel-titanio, Radiografia, Strumento separato

Sara Alemam<sup>1</sup>  
Shaimaa Abuelsadat<sup>2</sup>  
Shehabeldin Saber<sup>3,4</sup>  
Tarek Elsewify<sup>3</sup>

<sup>1</sup>Department of Endodontics, The Egyptian Russian University, Cairo, Egypt

<sup>2</sup>Department of Oral Radiology, Ain Shams University, Cairo, Egypt

<sup>3</sup>Department of Endodontics, Ain Shams University, Cairo, Egypt

<sup>4</sup>Department of Endodontics, The British University in Egypt, Cairo, Egypt

Received 2020, February 15

Accepted 2020, February 25

*Precisione, sensibilità e specificità di tre modalità di imaging nel rilevamento di strumenti intracanalari separati*

**Abstract**

**Aim:** To compare the accuracy, sensitivity and specificity of CBCT imaging and two dimensional periapical radiography in detection of separated intracanal endodontic instruments with and without root canal filling.

**Methodology:** Eighty (n=80) extracted mandibular molars were randomly divided into four groups (n=20); control, fracture/non-filled, non-fracture/filled, and fracture/filled. Molars were placed in a mandible for imaging. Conventional 2D radiography using D-speed periapical film (SKYDENT, Slovak Republic), semidirect digital radiographs using Soredex Digora Optime system (DIGORAOptime, Soredex, Finland), and cone beam computed tomography using Gendex-GXDP 800 (GENDEX GXDP-800 Kavo, Germany) were acquired. An artifact reduction algorithm was applied. Images were evaluated by three blinded examiners (two endodontists and one radiologist). Qualitative examination for the presence/absence of separated instrument was performed according to a 5-point rank scale (1, definitely absent; 2, probably absent; 3, uncertainty; 4, probably present; and 5, definitely present). Accuracy, sensitivity and specificity were calculated as well as inter-observer reliability. Statistical analysis was performed and significance level was set at 5%.

**Results:** Non-filled groups showed no significant difference between all three tested imaging modalities. Filled groups showed statistically decreased accuracy and sensitivity of CBCT. Good inter-observer agreement was shown.

**Conclusions:** Conventional 2D radiography is a good tool for detection of intracanal separated instruments in filled canals.

**Obiettivo:** confrontare l'accuratezza, la sensibilità e la specificità della CBCT e della radiografia periapicale bidimensionale nel rilevamento di strumenti endodontici intracanalari separati con e senza riempimento del canale radicolare.

**Metodologia:** ottanta (n=80) molari mandibolari estratti sono stati divisi casualmente in quattro gruppi (n=20); controllo, frattura/non riempito, non frattura/riempito e frattura/riempito. I molari sono stati collocati in una mandibola per l'esposizione con radiografia 2D convenzionale con film periapicale D-speed (SKYDENT, Repubblica slovacca), radiografie digitali semidirette con sistema Soredex Digora Optime (DIGORAOptime, Soredex, Finlandia) e tomografia computerizzata a fascio conico con Gendex-GXDP 800 (GENDEX GXDP-800 Kavo, Germania). È stato applicato un algoritmo di riduzione degli artefatti. Le immagini sono state valutate da tre esaminatori (due endodontisti e un radiologo). L'esame qualitativo della presenza/assenza di strumento separato è stato eseguito secondo una scala di 5 punti (1, decisamente assente; 2, probabilmente assente; 3, incerto; 4, probabilmente presente; e 5, sicuramente presente). Sono stati calcolati precisione, sensibilità e specificità, nonché affidabilità inter-osservatore. È stata eseguita un'analisi statistica e il livello di significatività è stato fissato al 5%.

**Risultati:** i gruppi non riempiti non hanno mostrato differenze significative per tutte e tre le modalità di imaging testate. I gruppi riempiti hanno mostrato un'accuratezza e una sensibilità della CBCT statisticamente diminuite. È stato mostrato un buon accordo tra osservatori.

**Conclusioni:** la radiografia 2D convenzionale è un buon strumento per la rilevazione di strumenti separati intracanalari in canali riempiti.

**Corresponding author**

Dr. Tarek Elsewify | Department of Endodontics, Faculty of Dentistry, Ain Shams University, Cairo | Egypt  
Tel. 002 010 67440940 | [Tarek\\_Elsewify@dent.asu.edu.eg](mailto:Tarek_Elsewify@dent.asu.edu.eg)

Peer review under responsibility of Società Italiana di Endodonzia

10.32067/GIE.2020.34.01.03

Società Italiana di Endodonzia. Production and hosting by Ariesdue. This is an open access article under the CC BY-NC-ND license (<http://creativecommons.org/licenses/by-nc-nd/4.0/>).



## Introduction

**A**lthough rotary nickel-titanium (NiTi) instruments have the ability to shape root canal systems in a shorter time with less procedural errors, unexpected instrument fracture still does occur (1). The possibility of NiTi instrument separation was shown to range from 0.4% to 4.4% (2).

Sattapan et al (3) identified two modes of fracture; cyclic fatigue and torsional failure. Cyclic fatigue which occurs due to metal fatigue when it rotates freely in a curved canal at the point of maximum flexure (4, 5), while torsional failure happens upon reaching the ultimate shear strength. Many factors influence the occurrence of this mishap including root canal geometry (6), cleaning and shaping techniques (7), debris accumulation (8) sterilization procedures (9), size (5), taper (10), cross section (11), and instrument design (12), as well as the manufacturing technique (13); unfortunately, cyclic fatigue often happens without any visible sign of plastic deformation (2).

Once a separated instrument is observed on a routine radiograph or accidentally happened during root canal treatment, the patient should always be informed (14). From a medicolegal point, it is imperative to accurately diagnose a separated instrument inside a root canal before starting endodontic retreatment procedures. Otherwise, the clinician performing the retreatment might be blamed for it (15). Diagnosis and documentation of separated instruments is deemed mandatory (16).

Intracanal separated instruments may affect the treatment outcome as it prevents adequate root canal disinfection and/or obturation (17). Management of separated instruments includes leaving the instrument inside the root canal after bypassing it, instrument retrieval via orthograde approach, and surgical approach (18). Factors affecting treatment options are the preoperative pulp state, instrument position, remaining radicular dentin thickness, and root canal geometry (18). Proper diagnosis of a separated instrument in a

previously filled canal is not that easy because of the continuous radioopaque appearance of the instrument and the root canal filling (19).

Radiation dosage reduction, lack of image processing, and easier manipulation of image contrast, brightness, and sharpness are the main advantages of digital radiography over conventional radiographs (16). A primary limitation of periapical radiography being a two-dimensional image of a three-dimensional object. Cone-beam computed tomographic (CBCT) imaging overcomes this and allows for accurate assessment of morphology and proper diagnosis (20). Yet, CBCT suffers from metallic artifacts which hinders its ability to accurately diagnose separated metallic instruments (20).

CBCT demonstrated better accuracy than two-dimensional periapical radiography in detecting root perforations, external root resorption, and deviated posts (20). However, CBCT requires a longer scan time, and the patient is exposed to a larger X-ray dose compared to conventional or digital radiography (20). Moreover, contradictory results were reported regarding the detection of separated instruments in filled root canals (21).

Therefore, investigation of the best method to image and diagnosis the presence of instruments in filled root canals was of value. Our null hypothesis is that there is no difference in the accuracy of conventional radiography, digital radiography or CBCT to detect separated instruments in filled root canals.

## Materials and Methods

### *Sample Selection and Classification*

The current study was approved from the Research Ethics Committee of Ain Shams University (Cairo, Egypt), (approval number 07062019).

Eighty sound human mandibular molars extracted for periodontal reasons were selected and used. Teeth were randomly divided into four groups (n=20).

Group I: The control group in which root canals were prepared but left unfilled.

Group II: The fracture/non-filled group in

which root canals were prepared, and files were intentionally fractured.

Group III: The non-fracture/ filled group in which root canals were prepared and filled.

Group IV: The fracture/filled group in which root canals were prepared, files were intentionally fractured, then filled till the level of the separated instruments.

#### Sample Preparation

Endodontic access cavities were prepared in all teeth. Cleaning and shaping of teeth were performed using the Wa-

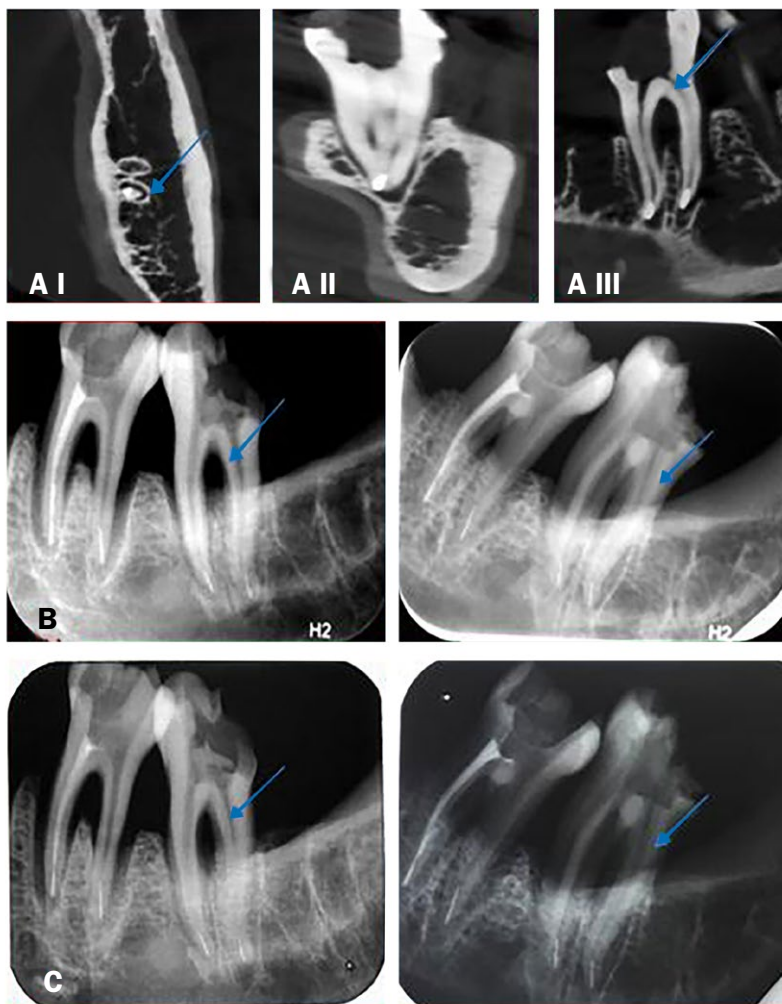
veOne Gold primary (Dentsply Maillefer, Ballaigues, Switzerland) in the presence of 2.5% NaOCl. Forty rotary NiTi files size 25 taper 0.06 were weakened by making a notch on each file at 3 mm from the tip. Then, file was inserted into the canal through the apical foramen and twisted to induce intra-canal instrument separation in groups II and IV (2, 30). Groups III and IV were obturated using gutta percha (META BIOMED CO, Republic of Korea) and AD-SEAL resin sealer (META BIOMED CO, Republic of Korea) in a cold lateral compaction technique. A dry human mandible was covered with utility wax to simulate soft tissue present in the clinical situation (2). Sockets were minimally modified to fit the teeth in the molar area properly.

#### Image Acquisition

**Conventional Radiography (CR):** Rinn-XCP film holder (AZDENT, XCP, film holding system, China) was used to place D-speed periapical film (SKYDENT, Slovak Republic) parallel to the long axis of the tooth and to direct the central beam perpendicular to both. The focus receptor distance was 25 cm. Two radiographs were acquired with two different horizontal angulations (1,2). Image acquisition was performed using FONAXDC periapical intraoral X-ray machine (FONAXDC, Assago, Italy) with the following exposure parameters; 70 kVp, 7 mA and one second exposure time. Automatic processing was performed using Velopex Extra-X (Velopex Extra-X, Velopex International, England).

**Semidirect Digital Radiography (SDDR)** were acquired using Soredex Digora Optime system (DIGORAOptime, Soredex, Finland). Photostimulable phosphor imaging plate (PSP) size #2 was held by XCP film holder as for conventional imaging with exposure parameters of 70 kVp, 7 mA and 0.04 seconds exposure time.

**CBCT Scans:** Gendex-GXDP 800 (GENDEX GXDP-800 Kavo, Germany) was used with the following image acquisition protocol: 5\*5 FOV, 90 kVp, 5 mA and spatial resolution 0.085 mm.



**Figure 1**

Mesiobuccal canal of lower second molar (blue arrows) radiographed by 3 different imaging modalities (A) CBCT; (I) axial section, (II) coronal section, (III) sagittal section. (B) SDDR with two different horizontal angulations and (c) CR with two different horizontal angulations.

**Table 1**

Mean diagnostic values for different imaging methods in the absence of filling material

Imaging method	Accuracy	Sensitivity	Specificity
CBCT	0.889 <sup>a</sup>	0.900 <sup>a</sup>	0.889 <sup>a</sup>
SDDR	0.883 <sup>a</sup>	0.900 <sup>a</sup>	0.889 <sup>a</sup>
CR	0.844 <sup>a</sup>	0.833 <sup>a</sup>	0.850 <sup>a</sup>

Different letters in the same column indicate statistically significance difference ( $p < 0.05$ ).

*Image Evaluation*

Conventional periapical radiographs were evaluated on a view box. Indirect digital images were viewed on an 18.5 inch HD LED monitor with resolution of 1366x768

using DFW 2.7 software. Zoom, brightness and contrast tools were available for use. CBCT images were analyzed using In Vivo Anatomage 5.3 software on an 18.5 inch HD LED monitor with resolution of 1366x768. A multiplanar reformatted screen was used to evaluate the CBCT scans. Zoom, brightness and contrast tools were also used when required. An artifact reduction algorithm was applied to enhance the image quality and the decrease the imaging artifacts.

Images were evaluated by 3 blinded examiners (two endodontists and one oral and maxillofacial radiologist). Qualitative examination for the presence/absence of separated instrument was performed according to a 5-point rank scale (1, definitely absent; 2, probably absent; 3, uncertainty; 4, probably present; and 5, definitely present) (16).

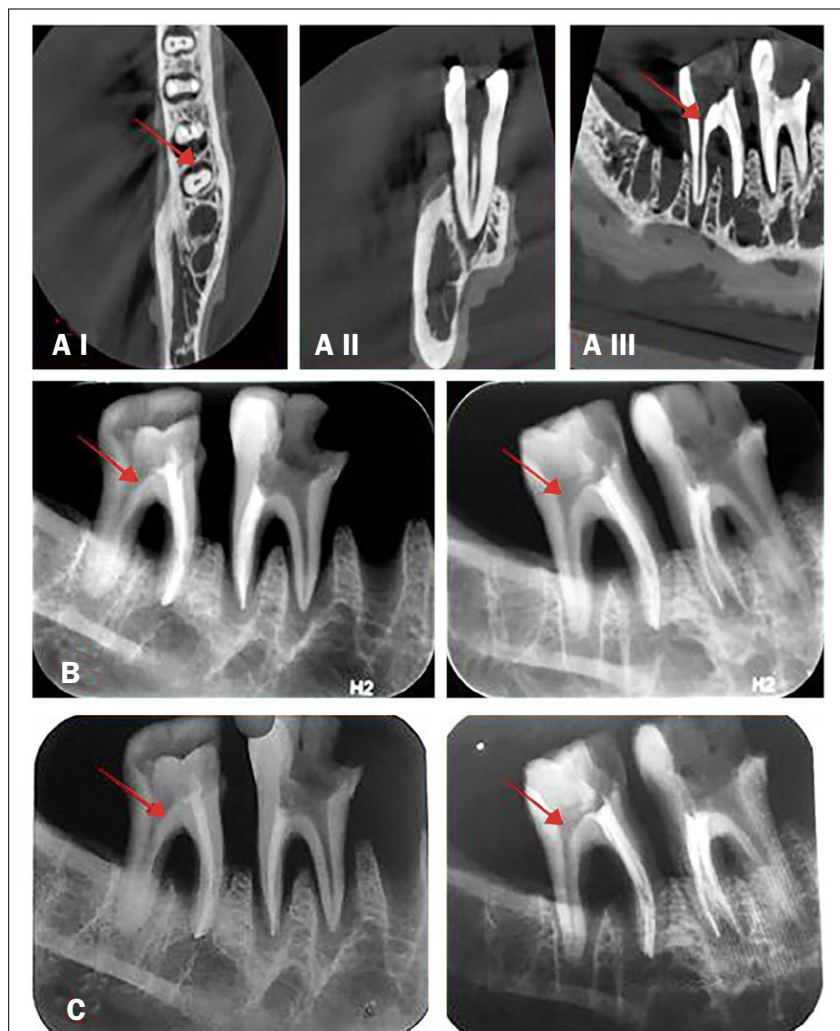
*Statistical Analysis*

Kendall's coefficient of concordance was used to study the inter-rater reliability. Paired comparisons of receiver operator characteristic (ROC) curves were used to assess the diagnostic accuracy of the imaging methods utilized. The significance level was set at 5% for all tests. Statistical analysis was performed using NCSS version 12 for Windows.

**Results**

*Accuracy, Sensitivity and Specificity*

For groups I and II, non-filled, diagnostic accuracy (AUC), sensitivity and specificity values for all imaging modalities tested are shown in table 1. No significant difference was shown between all three tested imaging modalities regarding diagnostic accuracy, sensitivity or specificity (figures 1 and 2).



**Figure 2**

Distal canal of lower second molar (red arrows) radiographed by 3 different Imaging modalities (A) CBCT; (I) axial section, (II) coronal section, (III) sagittal section (B) SDDR with two different horizontal angulations and (C) CR with two different horizontal



**Table 2**

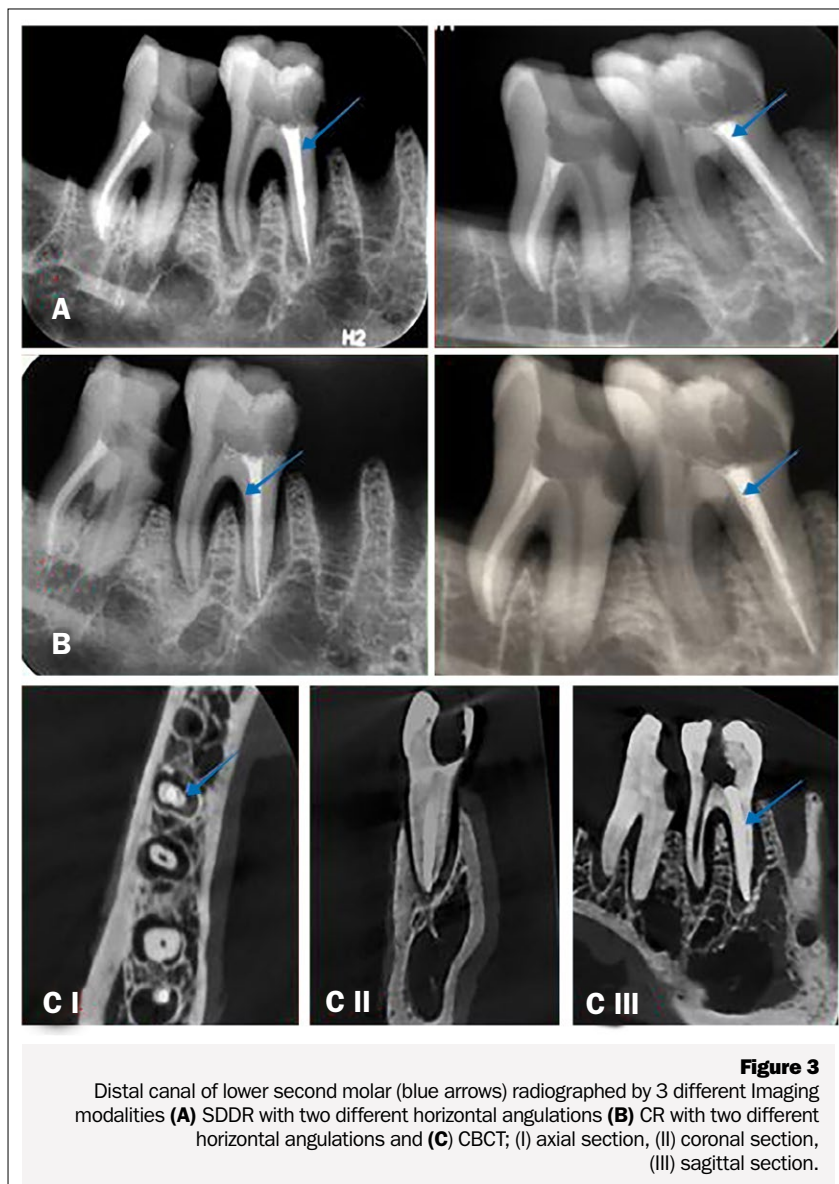
Mean diagnostic values for different imaging methods in the presence of filling material

Imaging method	Accuracy	Sensitivity	Specificity
CBCT	0.526 <sup>b</sup>	0.300 <sup>b</sup>	0.888 <sup>a</sup>
SDDR	0.807 <sup>a</sup>	0.900 <sup>a</sup>	0.722 <sup>a</sup>
CR	0.793 <sup>a</sup>	0.80 <sup>a</sup>	0.666 <sup>a</sup>

Different letters in the same column indicate statistically significance difference ( $p < 0.05$ ).

For groups III and IV, filled canals, accuracy, sensitivity and specificity values for all imaging modalities tested are shown in table 2. CBCT showed a statistically significantly smaller AUC and sensitivity

values compared to SDDR ( $P = 0.006$ ) and CR ( $P = 0.005$ ). No significant difference was shown between SDDR and CR regarding accuracy, sensitivity or specificity (figures 3 and 4).



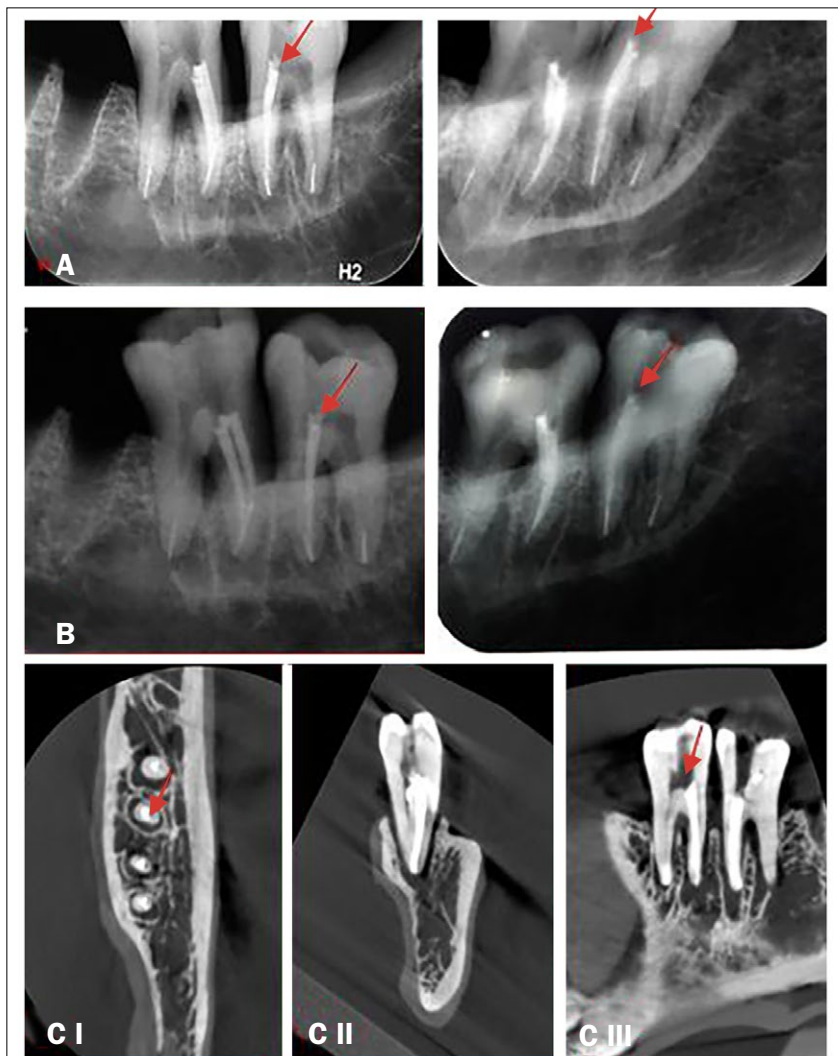
#### Interobserver Reliability

There was an overall good agreement between the three observers for all imaging techniques ( $W = 0.813$ ) which was statistically significant ( $P < 0.001$ ). There was a strong agreement for the measurements of CBCT ( $W = 0.878$ ) and CR ( $W = 0.856$ ) which was statistically significant ( $P < 0.001$ ). While for the SDDR, the observers' agreement was excellent ( $W = 0.914$ ) and statistically significant ( $P < 0.001$ ).

#### Discussion

An intracanal separated instrument may hinder or block the access to the apical part of the canal and compromises the effectiveness of cleaning and shaping procedures. Decision making in the clinical situation to bypass, remove or leave separated instruments will depend on the clinical and radiographic findings (21). Hence, the diagnostic capability of the imaging modality used for assessment of separated instruments should be reliable, especially in the presence of root canal filling materials. Generally, the ability of radiographs to display high image quality in an image is influenced by spatial and contrast resolution. The spatial resolution, represented as LP/mm, is the ability of radiographs to distinguish fine details in an image (22). With CBCT, images with high spatial resolution are obtained when the high-definition mode and a low voxel size are used for scanning (23). Consequently, CBCT scans with endo mode 0.085 mm voxel





**Figure 4**  
Distal canal of lower second molar (red arrows) radiographed by 3 different imaging modalities (A) SDDR with two different horizontal angulations (B) CR with two different horizontal angulations and (C) CBCT; (I) axial section, (II) coronal section, (III) sagittal section.

size was selected in the present study. A limited FOV 5x5 was also used in this study. According to Patel al (25), it is suitable for endodontic purposes as the produced reconstructed images are of high diagnostic power because of the higher spatial resolution than that of those of larger FOV scans. Moreover, only the region of interest is irradiated. Thus, the effective dose to the patient is reduced. Five points scale was used in the present study as it has the advantage of not expecting a simple Yes/No answer from the respondent, but rather allow for degrees of

opinion, even in case of hesitation. Therefore, quantitative data could be obtained, which means that the data can be analyzed with relative ease (16).

The interpretation of images with respect to clarity is a subjective judgment of its appearance, which comprises both the technical qualities of the image as well as experience, skill and visual perception of the viewer. There was an excellent inter-observer reliability as their diagnostic scores for all imaging techniques were nearly comparable whether in the presence or absence of the filling material.

PSP plates also have better contrast detectability in addition to the increased exposure latitude in comparison to conventional periapical films, which enable them to distinguish between different densities on the radiographs (16). This explains the high accuracy, sensitivity and specificity of indirect digital radiography used in the current study.

The results of our study showed that the accuracy and sensitivity of CBCT were negatively affected by the presence of gutta-percha. This agrees with Khedmat et al (26), who concluded that the presence of gutta-percha reduced the accuracy, sensitivity and specificity of CBCT, and Kobayashi et al (27) who reported that one of the drawbacks of CBCT images was its low contrast resolution which is the ability to distinguish different densities or shades of grey within a radiographic image (21). The decreased accuracy and sensitivity in the present study is not related to the CBCT artifacts but rather to its inherent low contrast resolution. Inherent or induced artifacts caused by the intracanal metallic and non-metallic fillings are considered to be a significant limitation of CBCT (25). Therefore, an artifact reduction algorithm was applied in the present study to enhance the image quality and avoid beam hardening effect from the gutta-percha filling. The higher specificity value of CBCT in filled canals compared to SDDR and CR may be explained by the evaluators' difficulty in detecting separated instrument. This could be due to proper condensation of the filling material and the absence of the gap between filling material and the separated



instrument. Hence, there was a tendency to answer “probably absent” or “absent”, which resulted in a high number of “negative” answers, consequently increasing the number of “true-negative” cases (24).

It should be pointed out that our results were confined and limited to only one type of intraoral digital imaging and CBCT imaging systems. Results may vary if other direct or semi-direct digital systems and CBCT scanners were used. Within limitations of the current study, the null hypothesis is rejected and we conclude that conventional 2D radiography is a useful tool for the detection of intracanal separated endodontic instruments in filled canals.

## Clinical Relevance

Conventional two-dimensional radiography is a useful tool for the detection of intracanal separated endodontic instruments in filled canals.

## Conflict of Interest

The authors deny any conflicts of interest related to this study.

## Acknowledgments

The authors deny any conflicts of interest related to this study.

## References

1. Saber SEDM, Sadat SM. Effect of altering the reciprocation range on the fatigue life and shaping ability of WaveOne nickel titanium instruments. *J Endod* 2013;39:685-8.
2. Saber SE. Factors influencing the fracture of rotary nickel titanium instruments. *ENDO (Lond Engl)* 2008;2:273-83.
3. Sattapan B, Nervo GJ, Palamara JE, Messer HH. Defects in rotary nickel-titanium files after clinical use. *J Endod* 2000;26:161-5.
4. Pruett JP, Clement DJ, Carnes DL Jr. Cyclic fatigue testing of nickel-titanium endodontic instruments. *J Endod* 1997;23:77-85.
5. Gambarini G, Seracchiani M, Piasecki L, Valenti Obino F, Galli M, Di Nardo D, et al. Measurement of torque generated during intracanal instrumentation in vivo. *Int Endod J* 2019;52:737-45.
6. Booth JR, Scheetz JP, Lemons JE, Eleazer PD. A comparison of torque required to fracture three different nickel-titanium rotary instruments around curves of the same angle but of different radius when bound at the tip. *J Endod* 2003;29:55-7.
7. Roland DD, Andelin WE, Browning DF, Hsu GH, Torabinejad M. The effect of preflaring on the rates of separation for 0.04 taper nickel titanium rotary instruments. *J Endod* 2002;28:543-5.
8. Alapati SB, Brantley WA, Svec TA, Powers JM, Nusstein JM, Daehn GS. Proposed role of embedded dentin chips for the clinical failure of nickel-titanium rotary instruments. *J Endod* 2004;30:339-41.
9. Viana AC, Gonzalez BM, Buono VT, Bahia MG. Influence of sterilization on mechanical properties and fatigue resistance of nickel-titanium rotary endodontic instruments. *Int Endod J* 2006;39:709-15.
10. Schrader C, Peters OA. Analysis of torque and force with differently tapered rotary endodontic instruments in vitro. *J Endod* 2005;31:120-3.
11. Cheung GS, Darvell BW. Low-cycle fatigue of niTi rotary instruments of various cross-sectional shapes. *Int Endod J* 2007;40:626-32.
12. Gambarini G, Miccoli G, Seracchiani M, Khrenova T, Donfrancesco O, D'Angelo M, et al. Role of the flat-designed surface in improving the cyclic fatigue resistance of endodontic niTi rotary instruments. *Materials (Basel)* 2019;12: pii: E2523.
13. Bhagabati N, Yadav S, Talwar S. An in vitro cyclic fatigue analysis of different endodontic nickel-titanium rotary instruments. *J Endod* 2012;38:515-8.
14. Saunders JL, Eleazer PD, Zhang P, et al. Effect of a separated instrument on bacterial penetration of obturated root canals. *J Endod* 2004;30:177-9.
15. Givol N, Rosen E, Taicher S, Tsesis I. Risk management in endodontics. *J Endod* 2010;36:982-4.
16. Ramos Brito A., Verner F, Junqueira R, Yamasaki M., Queiroz P, Freitas D, and Oliveira-Santos C. Detection of Fractured Endodontic Instruments in Root Canals: Comparison between Different Digital Radiography Systems and Cone-beam Computed Tomography. *J Endod* 2017;43:544-549.
17. Panitvisai P, Parunnit P, Sathorn C, Messer HH. Impact of a retained instrument on treatment outcome: a systematic review and meta-analysis. *J Endod* 2010;36: 775-80.
18. McGuigan MB, Louca C, Duncan HF. Clinical decision-making after endodontic instrument fracture. *Br Dent J* 2013;214:395-400.
19. Alves RA, Souza JB, Goncalves Alencar AH, et al. Detection of procedural errors with stainless steel and NiTi instruments by undergraduate students using conventional radiograph and cone beam computed tomography. *Iran Endod J* 2013;8:160-5.
20. Venskutonis T, Plotino G, Juodzbalsys G, Mickeviciene L. The importance of conebeam computed tomography in the management of endodontic problems: a review of the literature. *J Endod* 2014;40:1895-901.
21. Rosen E, Azizi H, Friedlander C, et al. Radiographic identification of separated instruments retained in the apical third of root canal-filled teeth. *J Endod* 2014;40: 1549-52.
22. Schulze R, Heil U, Gross D, Bruellmann DD, Dranischnikow E, Schwannecke U, Schoemer E. Artefacts in CBCT: a review. *Dentomaxillofac Radiol.* 2011; 40:265-73.
23. Scarfe WC, Levin MD, Gane D, Farman AG. Use of Cone Beam Computed Tomography in Endodontics. *Int J Dent.* 2009; 2009:634567.
24. Liedke GS, Spin-neto R. Diagnostic accuracy of cone beam computed tomography sections with various thicknesses for detecting misfit between the tooth and restoration in metal-restored teeth. *Oral Surgery, Oral Med Oral Pathol Oral Radiol.* 2015;120:131-137.
25. S Patel, C Durack, F Abella, M Roig, H Shemesh, P Lambrechts & K Lemberg. European Society of Endodontology position statement: The use of CBCT in Endodontics. *Int Endod J.* 2014;47:502-5
26. Khedmat S, Rouhi N, Drage N, Shokouhinejad N, Nekoofar MH. Evaluation of three imaging techniques for the detection of vertical root fractures in the absence and presence of gutta-percha root fillings. *Int Endod J.* 2012; 45:1004-9.
27. Kobayashi KI, Shimoda S, Nakagawa Y YA. No Title. *Int J Oral Maxillofac Implant.* 2004;19:228-231.

## ORIGINAL ARTICLE/ARTICOLO ORIGINALE

# Post removal techniques: a systematic review and meta-analysis

Tecniche di rimozione perni: revisione sistematica e meta-analisi

**KEYWORDS**

Cast Metal Post, Clinical Chair Time, Post-removal, Glass Fiber Post, Ultrasonics

**PAROLE CHIAVE**

Perni metallici, Tempo clinico alla poltrona, Rimozione perno, Perno in fibra di vetro, Ultrasuoni

Laís Dornelles Bianchini<sup>1</sup>  
Bruna Muhlinberg Vetromilla<sup>1\*</sup>  
Jovito Adiel Skupien<sup>1</sup>  
Carlos José Soares<sup>2</sup>  
Tatiana Pereira-Cenci<sup>1</sup>

<sup>1</sup>Federal University of Pelotas, Brazil

<sup>2</sup>Federal University of Uberlândia, Brazil

Received 2018, October 17

Accepted 2020, March 12

**Abstract**

**Aim:** This systematic review aimed to answer what is the best way to remove prefabricated metallic, fiber or cast metal posts.

**Methodology:** An electronic search was conducted in Medline and Scopus databases to identify clinical and in vitro studies that assessed post removal techniques from 1950 to October 2018. Tables were generated to summarize the included studies and reports were assessed for bias using the Cochrane risk of bias tool. A meta-analysis was performed to evaluate the force necessary to remove posts ( $\alpha=5\%$ ).

**Results:** Of the 2,951 studies identified in the initial search, 33 were selected. The duration of using ultrasonic vibrations (and the number of surfaces where the vibration was applied) led to less time spent and less force needed to dislodge a metal post. Dentist's expertise (more than 10 years) was also related to easier post removal. The use of adhesive cements resulted in a more difficult protocol for post removal.

**Conclusions:** Although there is need for more consistent results, the data summarized and meta-analysis points toward the use of ultrasonic energy as the first option to remove posts, with best results for metal posts.

**Scopo:** questa revisione sistematica mira a rispondere a quale sia il modo migliore per rimuovere i perni prefabbricati metallici, in fibra o di metallo.

**Metodologia:** è stata condotta una ricerca nei database Medline e Scopus per identificare studi clinici e in vitro che hanno valutato le tecniche di rimozione dei perni dal 1950 a ottobre 2018. Sono state generate tabelle per riassumere gli studi inclusi e le relazioni sono state valutate per bias utilizzando il rischio Cochrane come strumento di giudizio. È stata eseguita una meta-analisi per valutare la forza necessaria per rimuovere i post ( $\alpha=5\%$ ).

**Risultati:** dei 2.951 studi identificati nella ricerca iniziale, 33 sono stati selezionati. La durata dell'utilizzo delle vibrazioni ultrasoniche (e il numero di superfici su cui è stata applicata la vibrazione) ha comportato un minor dispendio di tempo e una minore forza necessaria per spostare un perno metallico. L'esperienza del dentista (più di 10 anni) era anche correlata alla rimozione del perno più facile. L'uso di cementi adesivi ha comportato un protocollo più difficile per la rimozione dei perni.

**Conclusioni:** sebbene siano necessari risultati più coerenti, i dati riepilogati e le meta-analisi indicano l'uso degli strumenti ultrasonici come prima opzione per rimuovere i post, con i migliori risultati per i perni metallici.

**Introduction**

The purpose of an intraradicular post is to increase the retention of restorative materials when the remaining dental tissue is not enough to support the treatment performed (1). While post-retained restorations are

known to present good survival, with both indirect and direct restorations (2), the need for removal of an intraradicular post may be necessary (3-5), and many methods can assist in this process. The use of an ultrasound device brings the advantage of decreased force to such removal, since their vibrations act in the cement line, causing its rupture (6). How-

**Corresponding author**

Bruna Muhlinberg Vetromilla | School of Dentistry, Federal University of Pelotas Gonçalves Chaves Street, 457, 96015-560, Pelotas, Rio Grande do Sul | Brazil  
bvvetromilla@gmail.com

Peer review under responsibility of Società Italiana di Endodonzia

10.32067/GIE.2020.34.01.09

Società Italiana di Endodonzia. Production and hosting by Ariesdue. This is an open access article under the CC BY-NC-ND license (<http://creativecommons.org/licenses/by-nc-nd/4.0/>).



ever, attention should be paid to water-cooling, as there is the risk of reaching a temperature deleterious to adjacent tissues. Another removal method is to drill out the post (depending on the material) with the assistance of diamond, Gates Glidden or Largo burs, or ultrasound cutting tips. In clinical practice, the technique is usually post-dependent. In both techniques, radiographic assessment is important before starting the procedure to avoid unnecessary loss of tooth structure, root perforations or to be sure that no root fracture already exists.

Also, it may be said that the experience of the dentist will influence the success of a post that is to be removed (7, 8). Yet, it is unknown whether there is a best technique to remove a post considering the various types of posts that may be used in clinical practice. Thus, this study aimed to conduct a systematic review to answer if there is a best technique to remove prefabricated metallic, fiber or cast metal posts. The hypothesis tested was that available post removal techniques would result in distinct times of removal and maintenance of sound dental structure.

## Materials and Methods

This review followed the guidelines of the Cochrane Handbook for Systematic Reviews of Interventions (9) and the reporting was based on PRISMA (10).

### *Eligibility criteria*

Is ultrasound device better than burs for post removal in endodontic treated teeth, considering time and maintenance of dental structure?

Any in vitro or in vivo study that involved protocols or techniques for dental posts removal were included. Only English-language articles were selected. Studies that did not use post removal techniques were excluded, as well as the clinical case reports and discussions/reviews on the subject.

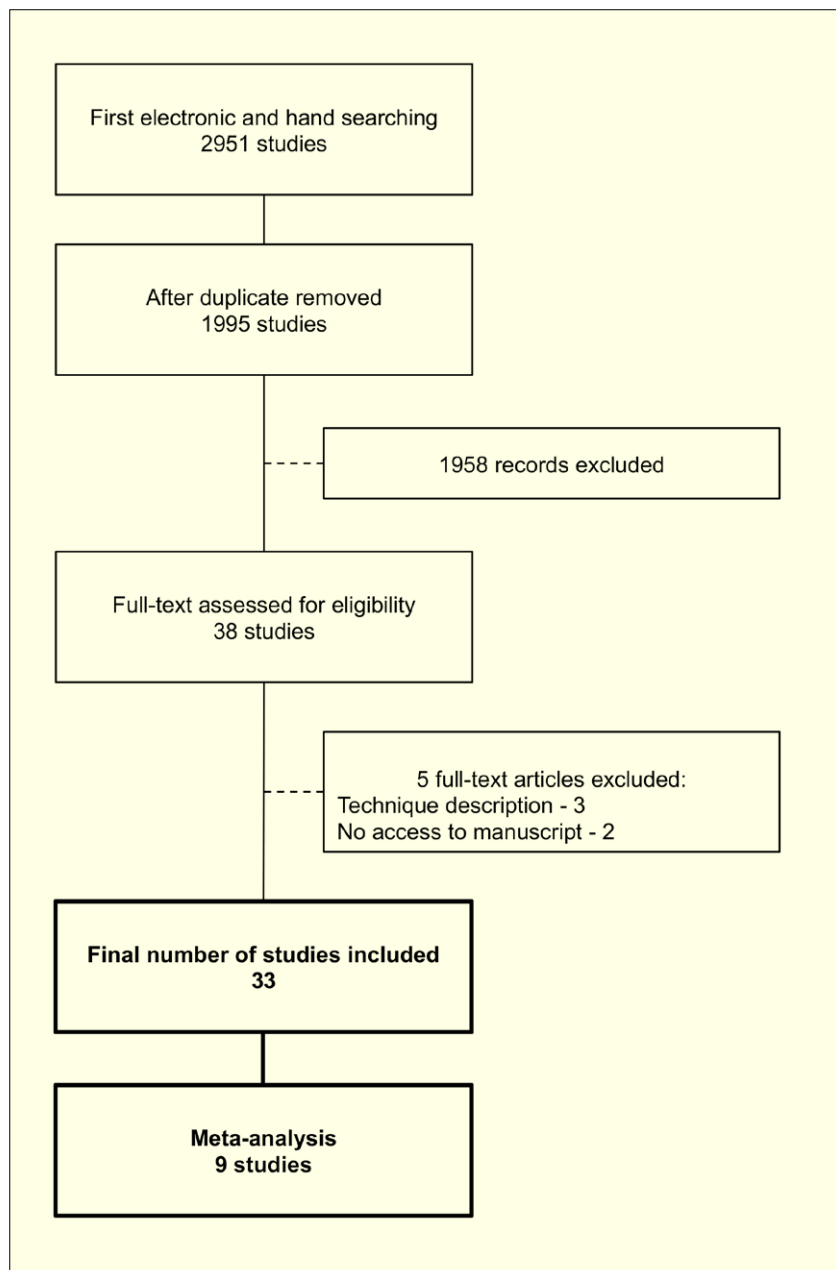
### *Information sources and literature search*

Searches were performed in electronic databases (Medline and Scopus) to identify all relevant articles published from 1950 to October 2018. The references of articles included in the review were searched, including hand searching, for additional articles. The literature search strategy is available in table 1.

**Table 1**  
Search strategy for the electronic databases

Database	Search strategy
PubMed	((“Tooth, Nonvital”[Mesh] OR “Nonvital Tooth” OR “Tooth, Devitalized” OR “Devitalized Tooth” OR “Tooth, Pulpless” OR “Pulpless Tooth” OR “Teeth, Pulpless” OR “Pulpless Teeth” OR “Teeth, Devitalized” OR “Devitalized Teeth” OR “Teeth, Nonvital” OR “Nonvital Teeth” OR “Teeth, Endodontically-Treated” OR “Endodontically-Treated Teeth” OR “Teeth, Endodontically Treated” OR “Tooth, Endodontically-Treated” OR “Endodontically-Treated Tooth” OR “Tooth, Endodontically Treated”)) AND (“Post and Core Technique”[Mesh] OR “Post-Core Technic” OR “Post-Core Technics” OR “Technic, Post-Core” OR “Technics, Post-Core” OR “Post and Core Technic” OR “Post Technique” OR “Post Techniques” OR “Technique, Post” OR “Techniques, Post” OR “Post Technic” OR “Post Technics” OR “Technic, Post” OR “Technics, Post” OR “Dental Dowel” OR “Dowels, Dental” OR “Dental Dowels” OR “Dowel, Dental”)
Scopus	ALL ( “Tooth, Nonvital” OR “Nonvital Tooth” OR “Tooth, Devitalized” OR “Devitalized Tooth” OR “Tooth, Pulpless” OR “Pulpless Tooth” OR “Teeth, Pulpless” OR “Pulpless Teeth” OR “Teeth, Devitalized” OR “Devitalized Teeth” OR “Teeth, Nonvital” OR “Nonvital Teeth” OR “Teeth, Endodontically-Treated” OR “Endodontically-Treated Teeth” OR “Teeth, Endodontically Treated” OR “Tooth, Endodontically-Treated” OR “Endodontically-Treated Tooth” OR “Tooth, Endodontically Treated” ) AND ALL ( “Post and Core Technique” OR “Post-Core Technic” OR “Post-Core Technics” OR “Technic, Post-Core” OR “Technics, Post-Core” OR “Post and Core Technic” OR “Post Technique” OR “Post Techniques” OR “Technique, Post” OR “Techniques, Post” OR “Post Technic” OR “Post Technics” OR “Technic, Post” OR “Technics, Post” OR “Dental Dowel” OR “Dowels, Dental” )





**Figure 1**  
PRISMA flowchart.

### Study selection

Literature searches were de-duplicated in the EndNote program. Two independent researchers (LDB and BMV) identified articles by first analyzing titles and abstracts for relevance and presence of the selection criteria listed above. The full-text articles of included and uncertain records were obtained for further eligibility screening by the same two reviewers. Discrepancies in eligibility were resolved through discussion between the

two reviewers. In the event of disagreement, the opinion of a third specialist (TPC) was obtained.

### Data collection process and data items

Data were collected through Excel (Microsoft Corp, Washington, USA) spreadsheets by the two reviewers, each of them responsible for half of the included studies. A standardized outline was used to extract the main findings of the studies (that is, the results and conclusion) as well as variables as type of technique, type of post and cement were extracted and recorded. The missing data was requested to the authors by e-mail in two attempts. Studies were excluded if there was no reply from the authors or if they did not have the data anymore.

### Data synthesis and risk of bias assessment

The estimated effect of pooled data was obtained by comparison of means and was represented by weights between different means ( $p < 0.05$ ). The analysis was conducted using Review Manager Software version 5.1 (Copenhagen: The Nordic Cochrane Centre, The Cochrane Collaboration). Also, a qualitative investigation was made with all papers included. Reports of the studies were assessed for bias using the Cochrane risk of bias tool considering the judgment of the blinding of evaluators, presence of a control group, sample size calculation and sample randomization (9).

## Results

### Study selection and characteristics

The initial literature search yielded 2,951 studies. After duplicates removal and analysis of titles and abstracts, 38 articles were selected to access the full-text and 33 were included in the review (5 excluded for the following reasons: two studies were not found and three were technique descriptions; PRISMA flowchart – figure 1). All studies were in English. The most used technique was ultrasound removal and bur removal. The characteristics of each included study are presented in table 2.



**Table 2**  
**Main characteristics of the included studies**

Year	Author	Type of substrate	Endodontic treatment	Post type	Aging /storage	Cement	Groups
2017	Graça et al	Molar	Y	Cast post	Humidity at 37°C for 24h	Zinc phosphate	G1: no cavity/no ultrasonic vibration G2: ultrasonic vibration in the coronal portion G3: cavity in the core G4: cavity in the core and ultrasonic inside the cavity
2014	Abe et al	Canine	Y	Glass fiber	Dry light-protect environment for 30 days	Resin cement	G1: diamond bur and largo reamer G2: ultrasonic insert G3: carbide bur and ultrasonic insert
2013	Ebrahimi et al	Canine and PM	Y	Titanium	Water at 37°C for 7 days	Zinc phosphate	G1: post length 5 mm G2: post length 7 mm G3: post length 9 mm
						Glass ionomer	G4: post length 5 mm G5: post length 7 mm G6: post length 9 mm
						Resin cement	G7: post length 5 mm G8: post length 7 mm G9: post length 9 mm
2013	Feiz et al	Premolar	Y	Alloy Metallic	Thermal cycling machine - 5-55°C 500 cycles 20sec of stay   10sec transfer time	Resin self-etch	G1: No ultrasonic vibration G2: Ultrasonic vibration
						Resin self-adhesive	G3: No ultrasonic vibration G4: Ultrasonic vibration
2013	Scotti et al	Single-Rooted	Y	G1: Fiber post (D.T. Light-Post)	Humidity at 37°C for 24h	Resin cement	G1: Ultrasonic vibration with one unit without refrigeration
				G2: Fiber post (Hi-Rem)			G2: Manufacturer's instructions
2012	Braga et al	Canine	Y	Copper-aluminum alloy	Distilled water at 37°C for 7 days	Zinc phosphate	G1: control (no ultrasonic vibration) G2: device tip positioned close to the incisal edge G3: device tip positioned close to the cementation line
2010	Adarsha et al	Canine	Y	Alloy NiCr	Humidity at room temperature for 3 weeks	Glass ionomer	G1: No ultrasonic vibration (control) G2: Ultrasonic vibration without refrigeration G3: Ultrasonic vibration with refrigeration
						Resin cement	G4: No ultrasonic vibration (control) G5: Ultrasonic vibration without refrigeration G6: Ultrasonic vibration with refrigeration
2010	Davis et al	Canine and PM	Y	Metallic	.	Resin cement	G1: common refrigerant spray for 10s G2: common refrigerant spray for 15s G3: common refrigerant spray for 20s G4: water spray for 10s G5: water spray for 15s G6: water spray for 20s G7: air spray for 10s G8: air spray for 15s G9: air spray for 20s
2010	Lipski et al	Incisor	Y	Prefabricated	.	Zinc phosphate	...
2009	Brito-Júnior et al	Premolar	Y	Alloy CuAl	Humidity at 37°C for 7 days	G1: Zinc phosphate	G1/A: Enac
							G1/B: Profi II
							G1/C: Jet Sonic
						G2: Glass ionomer	G2/A: Enac
							G2/B: Profi II
							G2/C: Jet Sonic

**Table 2**  
**Main characteristics of the included studies**

2009	Garrido et al	Canine	Y	G1 Core: 5mm Post: 1,3mm	Distilled water at 37°C for 7 days	Zinc phosphate	G1/A: Ultrasonic vibration - 5s on each surface
				G2 Core: 1,3x5 mm (DxH)   Post: 1,3mm			G1/B: Ultrasonic vibration with intermittent application of the ultrasonic tip, for 10 s on B and L faces alternately, 10 s on M and D faces in the same way and 5 s on the incisal face
				G3 Core: 1,3x3 mm (DxH)   Post: 1,3mm			G2/A: Ultrasonic vibration - 5s on each surface
							G2/B Ultrasonic vibration with intermittent application of the ultrasonic tip, for 10 s on B and L faces alternately, 10 s on M and D faces in the same way and 5 s on the incisal face
							G3/A: Ultrasonic vibration - 5s on each surface
							G3/B: Ultrasonic vibration with intermittent application of the ultrasonic tip, for 10 s on B and L faces alternately, 10 s on M and D faces in the same way and 5 s on the incisal face
2009	Soares et al	Canine	Y	Alloy NiCr	Humidity at 37°C for 24h	G1: Zinc phosphate	Burs and tapered diamond burs around the post and Ultrasonic Vibration in all surfaces
						G2: Glass ionomer	
						G3: Resin cement	
2008	Braga et al	Canine	Y	G1/A: Stainless Steel	Distilled water at 37°C for 72h	G1: Panavia F 2.0	Enac OE-5 unit and ST09 tips were applied to the incisal portion of the post, perpendicular to the long axis
				G1/B: Titanium			
				G2/A: Stainless Steel			
				G2/B: Titanium			
2007	Anderson et al	Single-Rooted	Y	G1: Fiber post (D.T. Light-Post)	100% humidity in opaque bottles individually numbered for 7 days	Resin cement (Duo-Link)	A) D.T. Light-Post kit B) Kodex/Tenax drills C) Diamond and Peeso reamer burs
				G2: Fiber post (ParaPost FiberLux)		Resin cement (ParaCem Universal DC)	A) D.T. Light-Post kit B) Kodex/Tenax drills C) Diamond and Peeso reamer burs
2007	Campos et al	Incisor	N	No post	37°C under 100% humidity for 24 h	Zinc phosphate	G1: control (no post)
				CuAlZn alloy			G2: Carbide bur G3: Ultrasound
				PdAg alloy			G4: Carbide bur G5: Ultrasound
2007	Ettrich et al	Not found	Y	Stainless steel	Water bath at 37°C and 100% humidity	Zinc phosphate	G1: no coolant G2: air-cooled G3: water-cooled
2007	Queiroz et al	Single-Rooted bovine	Y	PdAg alloy	Distilled water at 37°C for 72h	Zinc phosphate	G1: with coronal anatomy reproduced G2: without coronal anatomy reproduced
2006	Braga et al	Canine	Y	G1: Glass-Fiber	Distilled water at 37°C for 72h	Resin cement	G1: Instron 4444
				G2: Alloy CuAl			G2: Instron 4444
2005	Braga et al	Canine	Y	Alloy CuAl	Distilled water at 37°C for 72h	Resin cement	G1: Ultrasonic vibration with one unit for 30s on each surface G2: Ultrasonic vibration with one unit for 60s on each surface G3: Ultrasonic vibration with two units for, for 30s on two opposed surfaces at the same time G4: Ultrasonic vibration with two units for, for 60s on two opposed surfaces at the same time G5: No ultrasonic vibration (control)



**Table 2**  
**Main characteristics of the included studies**

2005	Dominici et al	Incisor	Y	Titanium	100% humidity for 30 days	Zinc phosphate	.
2005	Lindemann et al	Premolar	Y	G1: ParaPost XH (control)	Wrapped in paper towel moistened with water and stored in plastic bags for 24h	ParaPost Cement	G1 Method 1 Ruddle Post Removal System-PRS with refrigeration G1 Method 2 Diamond burs and Ultrasonic vibration
				G2: ParaPost Fiber White			G2 Method 1 Performed according with the manufacturer's instructions G2 Method 2 Diamond burs and Ultrasonic vibration
				G3: Luscent Anchors			G3 Method 1 Performed according with the manufacturer's instructions G3 Method 2 Diamond burs and Ultrasonic vibration
				G4: Aestheti-Plus			G4 Method 1 Performed according with the manufacturer's instructions G4 Method 2 Diamond burs and Ultrasonic vibration
2005	Pečiulienė et al	Single-Rooted	Y	Cast Post	.	G1: Zinc phosphate G2: Modified glass ionomer for resin	MasterPiezon 400 (EMS) with a D4 (EMS) ultrasonic tip
2003	Chandler et al	Canine	N	Titanium	Saline bath at 37°C	Resin cement	G1: Control G2: Trephination G3: Ultrasound
2003	Gesi et al	Anterior	Y	G1: Tapered Fiber	Water for 48h	G1: Dual-Cure G2: Excite DSC and Variolink II G3: Duo-Link Cement	G1/A: Kit RDT G1/B: 1 diamond bur and 1 Largo bur
				G2: Glass-Fiber			G2/A: Kit RDT G2/B: 1 diamond bur and 1 Largo bur
				G3: Carbon Fiber			G3/A: Kit RDT G3/B: 1 diamond bur and 1 Largo bur
2003	Hauman et al	Canine	Y	Parapost (SS)	Saline at 37°C for 14 days	Zinc phosphate	G1: vibration G2: no vibration
						Glass ionomer	G3: vibration G4: no vibration
						Resin cement	G5: vibration G6: no vibration
				Parapost (Ti)		Zinc phosphate	G7: vibration
						Glass ionomer	G8: vibration
						Resin cement	G9: no vibration
2002	Castrisos et al	Single-Rooted	Y	Non-precious alloy	.	Zinc phosphate	G1: 1 mm of dentine thickness G2: 2 mm of dentine thickness
2002	Dixon et al	Canine	Y	Alloy Stainless Steel	Natural water at room temperature for at least 2 months	Zinc phosphate	G1: Instron 444 G2: Spartan Ultrasonic G3: Enac Ultrasonic



**Table 2**  
**Main characteristics of the included studies**

2001	Bergeron et al	Canine	Y	Titanium	37°C under 100% humidity for 14 days	Zinc phosphate	G1: vibration and Root's 821 Elite Sealer G2: no vibration and Root's 821 Elite Sealer G3: vibration and AH26 Sealer G4: no vibration and AH26 Sealer
						Resin cement	G5: vibration and Root's 821 Elite Sealer G6: no vibration and Root's 821 Elite Sealer G7: vibration and AH26 Sealer G8: no vibration and AH26 Sealer
1996	Johnson	Premolar	Y	Parapost (SS)	37°C and 100% humidity for 30 days	Zinc phosphate	G1: Control (no vibration) G2: Ultrasonic for 4 minutes
							G3: Ultrasonic for 12 minutes G4: Ultrasonic for 16 minutes
1994	Buoncristiani	Single-rooted	Y	Titanium	100% humidity for 24 h	Zinc phosphate	G1: Control (Cavitron ultrasonic) G2: Neosonic ultrasonic G3: Enac ultrasonic G4: Micro mega sonic sealer G5: Densonc sonic sealer

#### *Risk of bias of the included studies*

From the 33 studies included, almost all presented unclear risk of bias (figure 2). The parameters considered in the analysis were the presence of a control group, blinding of evaluators, sample size calculation and sample randomization.

#### *Results of individual studies and synthesis of results*

Two types of outcomes were extracted from the 33 papers selected: time of post removal (11-21) and force required for post dislodgment or removal. Due to different methodologies and materials employed in those papers, a meta-analysis was only possible to be done with nine studies regarding the force needed to dislodge the intraradicular posts (11, 22-29). The main reasons for the impossibility of gathering data in the meta-analysis were varying types of posts, cements (resin-based, zinc phosphate, glass-ionomer-based) but especially various techniques employed for post removal as ultrasonic vibration with totally different protocols, use of kits for removal or use of diamonds/largo burs. Also, three papers were excluded and could not be included in the meta-analysis as it was impossible to extract the data (data presented in graphs – even after contact with the authors to obtain raw data or not

enough data available to run the analysis) (18,30,31). The analysis using a random-effect model showed that the necessary force to remove prefabricated and cast metal posts is decreased in 64.03 N (53.95-74.12;  $p < 0.00001$ , figure 3) when using ultrasonic vibration.

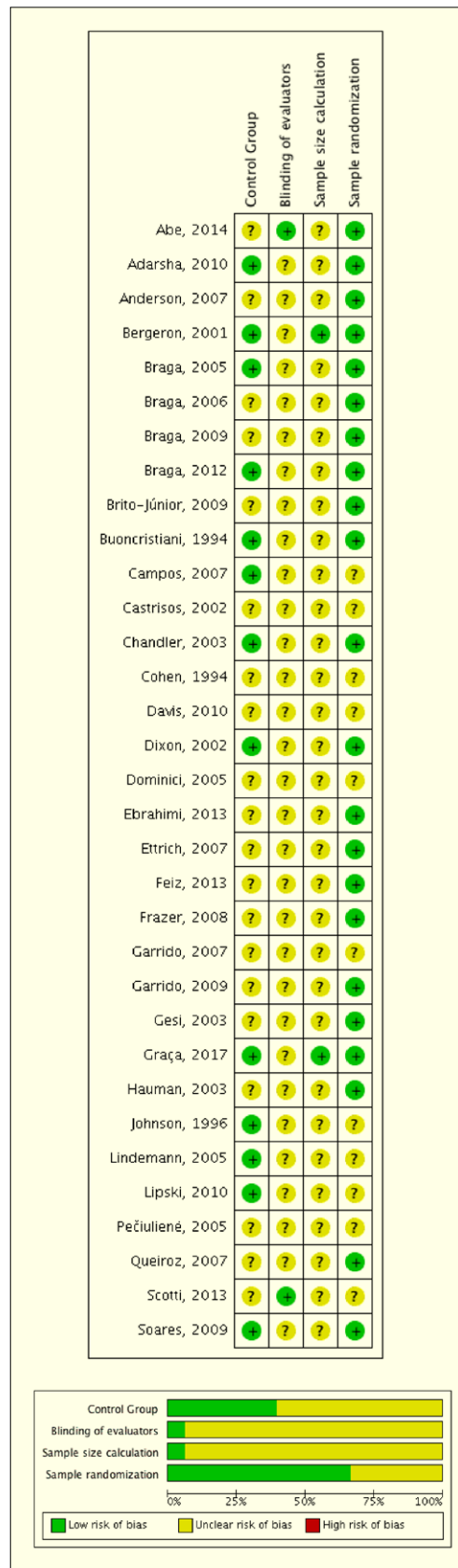
#### *Descriptive analysis*

Due to heterogeneous datasets, a descriptive analysis was the only option to describe the results of the other included studies. Not only the type of post and type of luting material were different among the included studies, but also the intervention method to evaluate post removal was also distinct. Even when ultrasonic vibration was assessed, the duration of ultrasonic vibration used (6, 16, 22, 32) and the use or not of water spray (11, 16, 33, 34) were also evaluated, leading to various scenarios that impaired the analysis. Still, it was possible to observe that the longer the duration of using ultrasonic vibrations (as well as the number of surfaces where the vibration was applied), the lower the time or the force needed to dislodge the post.

The influence of the dentist's expertise was also evaluated. Irrespective of the technique used to remove the post, a dentist with more than ten years of expertise in endodontics removed the post in less



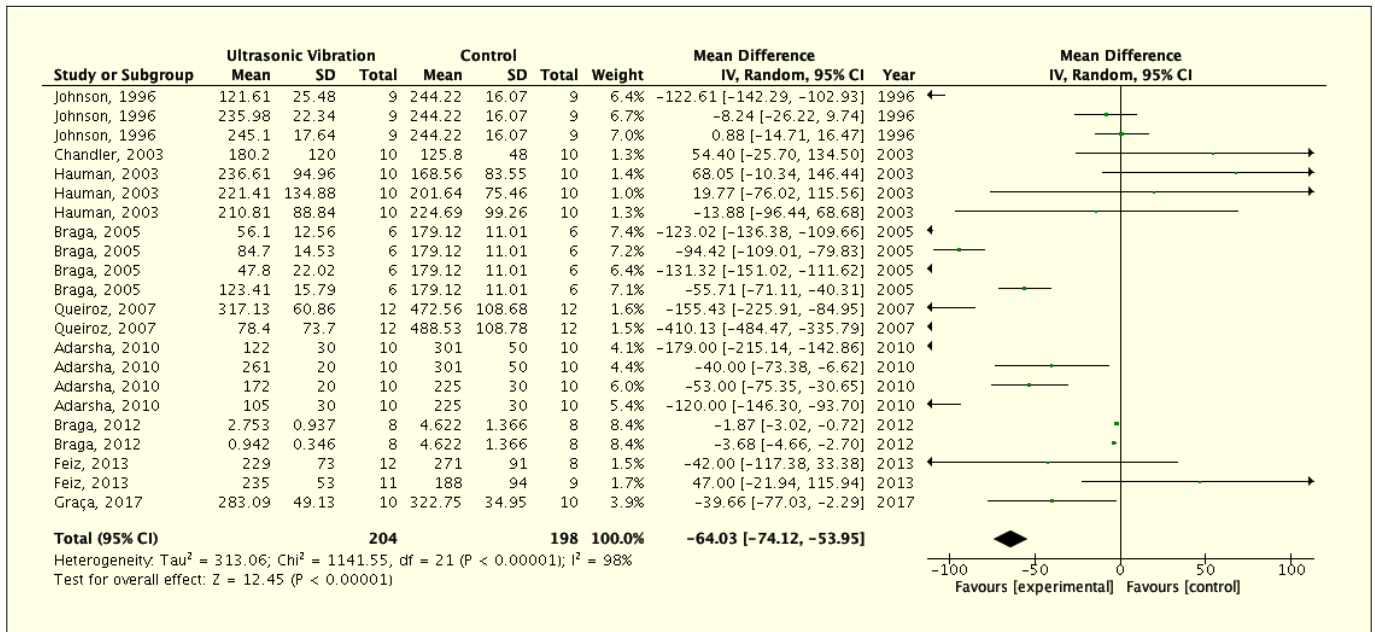
**Figure 2**  
Assessment of risk of bias  
of included studies.



time compared with an undergraduate student (20). Still, concerning the time spent to remove the post, a comparison regarding the type of material used for cementation was possible. Three studies found that posts cemented with zinc phosphate took less time to be removed when compared to glass ionomer cement irrespective of the method used (14, 19, 35). However, when compared with resin-based cement, both presented lower time needed to remove the post (21, 31, 35). Besides, regarding the force necessary to dislodge the post, one study found no difference between zinc phosphate, glass ionomer and resin-based cements (25), while another study evaluated resin-based and glass ionomer-based cement and concluded that it seems to be technique-dependent (11). One important clinical issue is the removal of a coronal portion of the post until the cement line is visualized, which could clinically help post removal; however, only two studies reported this issue in the methodology (14, 27). As for the material of the post, one study considered time needed to remove different types of posts and found that titanium posts took more time to be removed than fiber posts (31). Three studies compared post resistance. Glass fiber posts required more force to be removed compared to cast post (13) while titanium and glass fiber posts removal were dependent on the cement brand used (22). When titanium and stainless steel posts were compared, no difference was found (25).

## Discussion

This is the first systematic review comparing various techniques available to remove intraradicular posts and it has shown that time spent to remove a post using an ultrasound device is statistically significantly lower compared to other techniques for cast metal posts. It seems that ultrasonic energy would be helpful for fiber post removal, but the evidence is not as strong as for cast metal posts. Besides, when considering post removal, a series of actions should be care-



**Figure 3**  
 Results of meta-analysis. Best results are shown for ultrasonic vibration group (p<0.00001).

fully planned to avoid iatrogenic perforations or root fractures, including an X-ray. Techniques as use of trephines, hemostats or forceps are less used because of disadvantages as the procedure takes longer time, it removes more sound dental structure, and there is a need of the presence of a coronal structure for the apprehension of the instrument. The use of these specific devices to break the cement and pull out the post is only possible when a passive post has been used as there is a risk of a root fracture in active posts. These techniques, although reported in the literature, were not included in our study, as force is impossible to be measured, but also because no reports were found comparing those techniques.

When drilling out a post with diamond burs, there is sound dental structure removal, but this is lower when compared to the other technique cited above and is a feasible option to be used together with ultrasonic devices. On that situation, there is a difference between metallic and glass fiber posts removal. For the former, the idea is to open space for the post to be dislodged. Also, the technique is to diminish the metallic post diameter and height to expose the cement. Yet, for the fiber posts the technique is intended to drill the post completely.

Ultrasonic energy is effective when used to

remove metal posts, as these materials are rigid and present high elastic moduli, allowing vibrations to be conducted along the post, reducing the necessary force for removal. On the other hand, for fiber posts, the use of this technique still remains uncertain, as there is not enough information to draw definitive conclusions. The use of ultrasonic devices present the advantage of less chair time, although it presents higher cost and possibility of generating dentin micro cracks. When the use of ultrasonic device is not enough to dislodge the post, drills may be additionally used for final removal (13, 19, 21, 29). However, when considering glass fiber posts – and their low elastic modulus – the scenario may be different. Glass fiber posts are more difficult to be removed with ultrasonic devices, as not only the elastic modulus will negatively influence on the breaking of cement, but the cement itself is usually a resin-based cement, which neutralizes vibrations, absorbing the energy (21). Thus, it seems reasonable to indicate post drilling when a fiber post is to be removed.

Regarding the bonding agent, zinc phosphate took less time to be removed when compared to glass ionomer cement irrespective of the method used (14, 19, 35). When comparing these two cements with resin-based cements, both demonstrated low-



er time for removal (21, 31, 35). Historically, cast metal posts were cemented with zinc phosphate, which allows easy rupture when ultrasonic energy is used. Resin-based cements available are used to lute any type of post and the difficulty on its removal is possibly due to a better dentin union when compared to zinc phosphate and glass ionomer cements. In contrast, some authors report that the heat of ultrasonic devices would decrease adhesive characteristics of resin-based cements, leading to similar results when compared to the other cements (36). The impossibility of comparing time difference to remove different post types and cements is one of the limitations from the present study, and it is justified by the high heterogeneity of the present data. There is need of standardized studies, even if they are in vitro. Details as sample size calculation, randomization, use of control/comparison group, measurement of time for post removal, blinding of the operator, when

possible, are usually reported in clinical trials and should be present also in in vitro studies. Specifically, the authors must choose a technique and vary the type of cement and type of post or other variables, as presence or not of water-cooling. Considering that cast metal posts, glass fiber posts and resin cements are the most commonly selected materials (37), those must be selected for future studies.

In the present review, no conclusive advice can be given for fiber posts removal in clinical practice, due to limited data regarding it or the lack of standardized studies with this type of post. In addition, if a post is cemented with resin-based cement, glass ionomer and zinc phosphate, the bond strength of the first is higher than the others (36), leading us to believe that if there is a best technique to remove a post cemented with resin cement, probably it will be the best for the other types of cements. Considering the increased use of fiber posts, fur-

## References

- Schwartz RS, Robbins JW. Post placement and restoration of endodontically treated teeth: a literature review. *J Endod* 2004;30:289-301.
- Skupien JA, Cenci MS, Opdam NJ, Kreulen CM, Huysmans MC, Pereira-Cenci T. Crown vs. composite for post-retained restorations: A randomized clinical trial. *J Dent* 2016;48:34-9.
- Abe FC, Bueno CE, De Martin AS, Davini F, Cunha RS. Efficiency and effectiveness evaluation of three glass fiber post removal techniques using dental structure wear assessment method. *Indian J Dent Res* 2014;25:576-9.
- Goodacre CJ, Bernal G, Rungcharassaeng K, Kan JY. Clinical complications in fixed prosthodontics. *J Prosthet Dent* 2003;90:31-41.
- Ng YL, Mann V, Gulabivala K. Outcome of secondary root canal treatment: a systematic review of the literature. *Int Endod J* 2008;41:1026-46.
- Garrido AD, Oliveira AG, Osorio JE, Silva-Sousa YT, Sousa-Neto MD. Evaluation of several protocols for the application of ultrasound during the removal of cast intraradicular posts cemented with zinc phosphate cement. *Int Endod J* 2009;42:609-13.
- Rollings S, Stevenson B, Ricketts D. Posts—when it all goes wrong! Part 1: case assessment and management options. *Dent Update* 2013;40:82-4,6-8,90-1.
- Rollings S, Stevenson B, Ricketts D. Posts—when it all goes wrong! Part 2: post removal techniques. *Dent Update* 2013;40:166-8,70-2,75-8.
- Higgins JP, Altman DG, Gotzsche PC et al. The Cochrane Collaboration's tool for assessing risk of bias in randomised trials. *BMJ* 2011;343:d5928.
- Moher D, Liberati A, Tetzlaff J, Altman DG, Group P. Preferred reporting items for systematic reviews and meta-analyses: the PRISMA statement. *BMJ* 2009;339:b2535.
- Adarsha MS, Lata DA. Influence of ultrasound, with and without water spray cooling, on removal of posts cemented with resin or glass ionomer cements: An in-vitro study. *J Conserv Dent* 2010;13:119-23.
- Anderson GC, Perdigão J, Hodges JS, Bowles WR. Efficiency and effectiveness of fiber post removal using 3 techniques. *Quintessence Int* 2007;38:663-70.
- Braga NM, Paulino SM, Alfredo E, Sousa-Neto MD, Vansan LP. Removal resistance of glass-fiber and metallic cast posts with different lengths. *J Oral Sci* 2006;48:15-20.
- Brito Jr M, Soares JA, Santos SM, Camilo CC, Moreira Jr G. Comparison of the time required for removal of intraradicular cast posts using two Brazilian ultrasound devices. *Braz Oral Res* 2009;23:17-22.
- Dixon EB, Kaczowski PJ, Nicholls JI, Harrington GW. Comparison of two ultrasonic instruments for post removal. *J Endod* 2002;28:111-5.
- Garrido AD, Fonseca TS, Silva-Sousa YT, Alfredo E, Sousa-Neto MD. Evaluation of root external temperature during the application of ultrasound in removal of intraradicular posts. *Gen Dent* 2007;55:121-4.
- Gesi A, Magnolfi S, Goracci C, Ferrari M. Comparison of two techniques for removing fiber posts. *J Endod* 2003;29:580-2.
- Lindemann M, Yaman P, Dennison JB, Herrero AA. Comparison of the efficiency and effectiveness of various techniques for removal of fiber posts. *J Endod* 2005;31:520-2.



ther research must be conducted for this material. Also, non-destructive techniques as MicroCT and cone beam could be helpful to measure the amount of dentin lost during the removal process.

### Conclusions

Based on the findings from the present study, the use of an ultrasonic device seems to be the best technique when removing metal posts, although it seems less predictable for removing non-metal posts. Type of cement, post design, and length are important co-factors. More studies are necessary to draw more precise conclusions.

### Clinical Relevance

When there is a need for removal of an intraradicular post, the use of an ultrasonic device is the best technique for metal post,

although it is less predictable for non-metal posts. Post design, length, and type of cement are co-factors and should be considered as well.

### Conflict of Interest


The authors deny any conflicts of interest.

### Acknowledgments

This study was financed in part by Coordenação de Aperfeiçoamento de Pessoal de Nível Superior – Brazil (CAPES) – Finance Code 001, #88882. 346903/2019-01. TPC is partially funded by the National Council for Scientific and Technological Development (CNPq - Brazil) and FAPERGS - PRONEX #16/2551-0000471-4. The funders had no role in the study design, data collection, and analysis, decision to publish or preparation of the manuscript.

## References

- Peciuliene V, Rimkuvienė J, Maneliene R, Pletkus R. Factors influencing the removal of posts. *Stomatologija* 2005;7:21-3.
- Scotti N, Bergantin E, Alovizi M, Pasqualini D, Berutti E. Evaluation of a simplified fiber post removal system. *J Endod* 2013;39:1431-4.
- Soares JA, Brito-Junior M, Fonseca DR et al. Influence of luting agents on time required for cast post removal by ultrasound: an in vitro study. *J Appl Oral Sci* 2009;17:145-9.
- Braga NM, Resende LM, Vasconcellos WA, Paulino SM, Sousa-Neto MD. Comparative study of the effect of ultrasound on the removal of intracanal posts. *Gen Dent* 2009;57:492-5.
- Braga NM, Silva JM, Carvalho-Junior JR, Ferreira RC, Saquy PC, Brito-Junior M. Comparison of different ultrasonic vibration modes for post removal. *Braz Dent J* 2012;23:49-53.
- Chandler NP, Qualtrough AJ, Purton DG. Comparison of two methods for the removal of root canal posts. *Quintessence Int* 2003;34:534-6.
- Hauman CH, Chandler NP, Purton DG. Factors influencing the removal of posts. *Int Endod J* 2003;36:687-90.
- Johnson WT, Leary JM, Boyer DB. Effect of ultrasonic vibration on post removal in extracted human premolar teeth. *J Endod* 1996;22:487-8.
- Queiroz EC, Menezes MS, Biffi JC, Soares CJ. Influence of the shape core on custom cast dowel and core removal by ultrasonic energy. *J Oral Rehabil* 2007;34:463-7.
- Feiz A, Barekattain B, Naseri R, Zarezadeh H, Askari N, Nasiri S. The influence of ultrasound on removal of prefabricated metal post cemented with different resin cements. *Dent Res J (Isfahan)* 2013;10:760-3.
- Graça IAA, Sponchiado Júnior EC, Marques AAF, de Moura Martins L, Garrido ÂDB. Assessment of a Cavity to Optimize Ultrasonic Efficiency to Remove Intraradicular Posts. *J Endod* 2017;43(8):1350-1353.
- Cohen BI, Pagnillo M, Condos S, Musikant BL, Deutsch AS. Post removal using a thick-walled hollow tube post design. *Oral Health* 1994;84:15-8,21-2.
- Frazer RQ, Kovarik RE, Chance KB & Mitchell RJ. Removal time of fiber posts versus titanium posts. *Am J Dent* 2008;21(3):175-178.
- Dominici JT, Clark S, Scheetz J, Eleazer PD. Analysis of heat generation using ultrasonic vibration for post removal. *J Endod* 2005;31:301-3.
- Davis S, Gluskin AH, Livingood PM, Chambers DW. Analysis of temperature rise and the use of coolants in the dissipation of ultrasonic heat buildup during post removal. *J Endod* 2010;36:1892-6.
- Ettrich CA, Labossiere PE, Pitts DL, Johnson JD. An investigation of the heat induced during ultrasonic post removal. *J Endod* 2007;33:1222-6.
- Ebrahimi SF, Shadman N, Nasery EB, Sadeghian F. Effect of polymerization mode of two adhesive systems on push-out bond strength of fiber post to different regions of root canal dentin. *Dent Res J (Isfahan)* 2014;11:32-8.
- Hagge MS, Wong RD, Lindemuth JS. Retention strengths of five luting cements on prefabricated dowels after root canal obturation with a zinc oxide/eugenol sealer: 1. Dowel space preparation/cementation at one week after obturation. *J Prosthodont* 2002;11:168-75.
- Sarkis-Onofre R, Pereira-Cenci T, Opdam NJ, Demarco FF. Preference for using posts to restore endodontically treated teeth: findings from a survey with dentists. *Braz Oral Res* 2015;29:1-6.



# Lettera DEL PRESIDENTE

**1** 9 anni fa, per l'esattezza, ho fatto il mio ingresso come Socio Attivo della Società Italiana di Endodonzia.

Devo molto alla nostra Società, gli stimoli maggiori sono legati alla ricerca del miglioramento della mia attività clinica e alla necessità di adeguarmi, aggiornandomi e ascoltando i consigli e i suggerimenti di coloro che, da sempre, ho considerato i nostri maestri.

Tutti abbiamo bisogno di migliorare in continuazione e tutti dobbiamo con umiltà riconoscere coloro i quali, in modi diversi, ci hanno aiutato a crescere professionalmente.

La SIE ha assunto in questo modo la forma di una Scuola di diversi pensieri, tutti interessanti e ben supportati.

Durante i miei mandati come Segretario della Regione Liguria ho presentato al Consiglio in carica di allora la proposta di iniziare un percorso di formazione post laurea da svilupparsi a livello regionale: il progetto è stato prontamente approvato ed è stato collaudato dapprima all'interno della nostra Regione e poi esportato nelle altre Sezioni Regionali, con un successo che sicuramente ha superato le mie aspettative.

Il progetto ha dato la possibilità alla nostra Società, negli anni, di condurre una capillarizzazione della formazione endodontica a km 0 conferendole una caratteristica che può essere considerata una nostra esclusiva peculiarità.

Le tecniche moderne supportate da strumentario all'avanguardia hanno reso l'Endodonzia più predicibile e i risultati iconograficamente molto apprezzabili, ma la conoscenza endodontica deve avere un più ampio traguardo.

I giovani odontoiatri devono associare alla manualità un adeguato aggiornamento mediante le letture delle pubblicazioni scientifiche e questo arricchimento dovrebbe essere fatto con regolarità per poter ottenere una buona base culturale, per questo motivo ho pensato e fortemente voluto SIE ACADEMY: il nostro nuovo Socio Attivo deve essere formato e stimolato a una preparazione con più ampia visione dove l'elemento dentale deve essere inquadrato nella giusta integrazione che permetta una considerazione delle diverse patologie odontoiatriche; l'interazione con le varie specialità è necessaria per evitare una compartizzazione alienante della conoscenza professionale, per questo motivo l'aggiornamento attraverso i giornali dedicati deve essere continuo e approfondito.


Per ultimo, ma non ultimo, la mia presidenza, per quanto singolare poiché vicariante, ha finalmente aperto un confine fino a oggi ben chiuso, sono infatti fiera di essere la prima donna a ricoprire questa carica, ma sono anche certa che le mie colleghe più giovani preparate ed estremamente decise nelle "competizioni" con i colleghi, sapranno continuare questo percorso con il successo che meritano.

La nostra Società è in salute e questo risultato deve essere attribuito a un costante impegno da parte di tutti i componenti del Consiglio, ma anche dei soci che veramente si sono dimostrati "Attivi" e che in modo compatto e con entusiasmo hanno ben lavorato dedicando tempo e risorse al bene della Società. Inoltre, abbiamo una collaboratrice eccezionale nella nostra preziosa Gaia che con competenza ed efficacia conduce la complessa gestione della Segreteria.

È inutile nascondere che i lunghi anni trascorsi mi hanno fatto assistere a diatribe infuocate, più o meno giustificate, ma penso utopisticamente che le battaglie dovrebbero sempre essere condotte con eleganza e con rispetto e che, soprattutto attualmente, esista la necessità di pensare al bene futuro solo e sempre della Società.

SIE per sempre!

Il Presidente SIE  
Dott.ssa Maria Teresa Sberna



## STRUTTURA SOCIETARIA



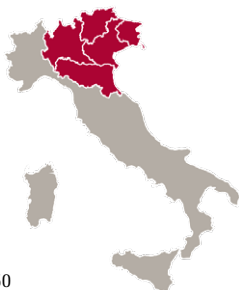**RESPONSABILE SCIENTIFICO  
E COORDINATORE CULTURALE SIE**

**Andrea Polese**  
P.zza Golgi, 16/1 - 16011 Arenzano GE  
Tel. 010-9124625 - 338-1289165  
[andrea.polese1971@gmail.com](mailto:andrea.polese1971@gmail.com)  
[andrea.polese@libero.it](mailto:andrea.polese@libero.it)

## COORDINATORI MACROAREE IN CARICA NEL BIENNIO 2019-2020



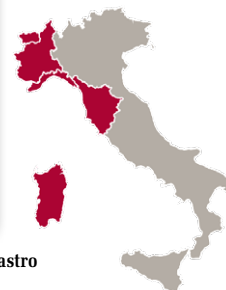**SIE MacroArea  
Nord-Est**



**Stefano Gaffuri**  
Via Napoleone, 50  
25039 Travagliato BS  
tel. studio 030-6864844  
cell. 335-5866543  
fax 030-6866189  
[stefanogaffuri@libero.it](mailto:stefanogaffuri@libero.it)  
[info@gaffurigalvaniodontoiatri.it](mailto:info@gaffurigalvaniodontoiatri.it)



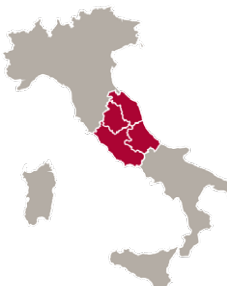**SIE MacroArea  
Nord-Ovest**



**Davide Fabio Castro**  
Via Otolì, 6B  
28013 Gattico NO  
tel. 0331-735276  
cell. 338-7075126  
[davidefabio.castro@gmail.com](mailto:davidefabio.castro@gmail.com)



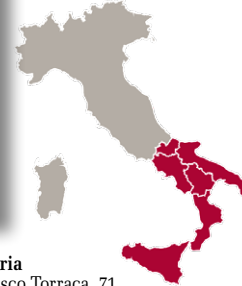**SIE MacroArea  
Centro**



**Luigi Scagnoli**  
Via Graziano, 57  
00165 Roma RM  
tel. 06-8607899  
cell. 393-3316543  
fax 06-8607899  
[luigiscagnoli@gmail.com](mailto:luigiscagnoli@gmail.com)



**SIE MacroArea  
Sud**



**Giorgio Vittoria**  
Largo Francesco Torraca, 71  
80133 Napoli NA  
tel. 081-5529419  
cell. 347-3848922  
fax 081-5424251  
[giorgio.vittoria@gmail.com](mailto:giorgio.vittoria@gmail.com)



## STRUTTURA SOCIETARIA

### SOCI ONORARI

Borsotti Prof. Gianfranco  
Bresciano Dott. Bartolo  
Cavalleri Prof. Giacomo  
Pecora Prof. Gabriele  
Perrini Dott. Nicola  
Vignoletti Dott. Gianfranco

### SOCI ATTIVI

Agresti Dott. Daniele  
Altamura Dott. Carlo  
Amato Prof. Massimo  
Ambu Dott. Emanuele  
Amoroso D'Aragona Dott.ssa Eva  
Ascione Dott.ssa Maria Rosaria  
Autieri Dott. Giorgio  
Badino Dott. Mario  
Barattolo Dott. Raniero  
Barboni Dott.ssa Maria Giovanna  
Becciani Dott. Riccardo  
Beccio Dott. Roberto  
Bertani Dott. Pio  
Berutti Prof. Elio  
Bonaccorso Dott. Antonino Maria  
Bonacossa Dott. Lorenzo  
Bonelli Bassano Dott. Marco  
Borrelli Dott. Marino  
Boschi Dott. Maurizio  
Bottacchiari Dott. Renato Stefano  
Botticelli Dott. Claudio  
Brenna Dott. Franco  
Bugea Dott. Calogero  
Cabiddu Dott. Mauro  
Calapaj Dott. Massimo  
Calderoli Dott. Stefano  
Campo Dott.ssa Simonetta  
Cantatore Prof. Giuseppe  
Capelli Dott. Matteo  
Cardinali Dott. Filippo  
Cardosi Carrara Dott. Fabrizio  
Carmignani Dott. Enrico  
Carratù Dott.ssa Paola  
Carrieri Dott. Giuseppe  
Cascone Dott. Andrea  
Cassai Dott. Enrico  
Castellucci Dott. Arnaldo  
Castro Dott. Davide Fabio  
Cavalli Dott. Giovanni  
Cecchinato Dott. Luigi  
Cerutti Prof. Antonio  
Cinelli Dott. Marco  
Ciunci Dott. Renato Pasquale  
Colla Dott. Marco  
Conconi Dott. Marcello  
Coraini Dott. Cristian  
Cortellazzi Dott. Gianluca  
Cotti Prof.ssa Elisabetta  
Cozzani Dott.ssa Marina  
D'Agostino Dott.ssa Alessandra  
Daniele Dott. Lucio  
Del Mastro Dott. Giulio  
Dettori Prof.ssa Claudia  
Di Giuseppe Dott. Italo  
Donati Dott. Paolo  
Dorigato Dott.ssa Alessandra  
Fabbri Dott. Massimiliano  
Fabiani Dott. Cristiano  
Faitelli Dott.ssa Emanuela

Fassi Dott. Angelo  
Favatà Dott. Pasquale Massimo  
Fermani Dott. Giorgio  
Ferraioli Dott. Gennaro  
Ferrari Dott. Paolo  
Ferrini Dott. Francesco  
Forestali Dott. Marco  
Fornara Dott. Roberto  
Fortunato Prof. Leonzio  
Franchi Dott.ssa Irene  
Franco Dott. Vittorio  
Fumei Dott. Gianluca  
Fuschino Dott. Ciro  
Gaffuri Dott. Stefano  
Gagliani Prof. Massimo  
Gallo Dott. Roberto  
Gallottini Prof. Livio  
Gambarini Prof. Gianluca  
Generali Dott. Paolo  
Gesì Dott. Andrea  
Giacomelli Dott.ssa Grazia  
Giovarruscio Dott. Massimo  
Gnoli Dott.ssa Rita  
Gorni Dott. Fabio  
Greco Dott.ssa Katia  
Gullà Dott. Renato  
Hazini Dott. Abdol Hamid  
Iacono Dott. Francesco  
Iandolo Dott. Alfredo  
Ivaldi Dott. Luca  
Kaitsas Dott. Roberto  
Kaitsas Prof. Vassilios  
Lamorgese Dott. Vincenzo  
Lamparelli Dott. Andrea  
Lendini Dott. Mario  
Libotte Dott. Fabrizio  
Maggiore Dott. Francesco  
Malagnino Dott. Giovanni Pietro Vito  
Malagnino Prof. Vito Antonio  
Malentacca Dott. Augusto  
Mancini Dott. Roberto  
Mancini Dott. Mario  
Mancini Dott. Manuele  
Manfredonia Dott. Massimo Francesco  
Manfrini Dott.ssa Francesca  
Mangani Prof. Francesco  
Martignoni Dott. Marco  
Mazzocco Dott. Alberto  
Messina Dott. Giovanni  
Migliau Dott. Guido  
Monza Dott. Daniele  
Mori Dott. Massimo  
Multari Dott. Giuseppe  
Mura Dott. Giovanni  
Natalini Dott. Daniele  
Negro Dott. Alfonso Roberto  
Olivi Prof. Giovanni  
Ongaro Dott. Franco  
Orsi Dott.ssa Maria Veronica  
Padovan Dott. Piero  
Palazzi Dott. Flavio  
Palmeri Dott. Mario  
Paone Dott. Pasquale  
Pansecchi Dott. Davide  
Papaleoni Dott. Matteo  
Pappalardo Dott. Alfio  
Parente Dott. Bruno  
Pasqualini Dott. Damiano

Piferi Dott. Marco  
Pilotti Dott. Emilio  
Pirani Dott.ssa Chiara  
Pisacane Dott. Claudio  
Plotino Dott. Gianluca  
Polesel Dott. Andrea  
Pollastro Dott. Giuseppe  
Pongione Dott. Giancarlo  
Pontoriero Dott.ssa Denise Irene Karin  
Portulano Dott. Francesco  
Pracella Dott. Pasquale  
Preti Dott. Riccardo  
Pulella Dott. Carmelo  
Puttini Dott.ssa Monica  
Raffaelli Dott. Renzo  
Raia Dott. Roberto  
Rapisarda Prof. Ernesto Guido  
Re Prof. Dino  
Reggio Dott.ssa Lucia  
Rengo Prof. Sandro  
Riccitiello Prof. Francesco  
Rieppi Dott. Alberto  
Rigolone Dott. Mauro  
Rizzoli Dott. Sergio  
Roggero Dott. Emilio  
Russo Dott. Ernesto  
Santarcangelo Dott. Filippo Sergio  
Sbardella Dott.ssa Maria Elvira  
Sberna Dott.ssa Maria Teresa  
Scagnoli Dott. Luigi  
Schianchi Dott. Giovanni  
Schirosa Dott. Pier Luigi  
Serra Dott. Stefano  
Sforza Dott. Francesco  
Simeone Prof. Michele  
Smorto Dott.ssa Natalia  
Sonaglia Dott. Angelo  
Squeo Dott. Giuseppe  
Storti Dott.ssa Paola  
Strafella Dott. Roberto  
Stuffer Dott. Franz  
Taglioretti Dott. Vito  
Taschieri Dott. Silvio  
Tavernise Dott. Salvatore  
Tocchio Dott. Carlo  
Tonini Dott. Riccardo  
Tosco Dott. Eugenio  
Tripi Dott.ssa Valeria Romana

Uberti Dott.ssa Manuela  
Uccioli Dott. Umberto  
Vecchi Dott. Stefano  
Venturi Dott. Mauro  
Venturi Dott. Giuseppe  
Venuti Dott. Luca  
Veralli Dott. Eduardo  
Vittoria Dott. Giorgio  
Volpi Dott. Luca Fedele  
Zaccheo Dott. Francesco  
Zaccheo Dott. Fabrizio  
Zerbinati Dott. Massimo  
Zilocchi Dott. Franco

### SOCI AGGREGATI

Castorani Dott. Giuseppe  
Cuppini Dott.ssa Elisa  
D'Alessandro Dott. Alfonso  
Zaccheo Dott. Francesco  
Zerbinati Dott. Massimo  
Zilocchi Dott. Franco

### CONSIGLIO DIRETTIVO SIE BIENNIO 2019-2020

**Past President**  
Riccitiello Prof. Francesco  
**Presidente**  
Maria Teresa Dott.ssa Sberna  
**Presidente Eletto**  
Fornara Dott. Roberto  
**Vice Presidente**  
Pisacane Dott. Claudio  
**Segretario**  
Gagliani Prof. Massimo  
**Tesoriere**  
Coraini Dott. Cristian  
**Coordinatore Culturale**  
Polesel Dott. Andrea  
**Coordinatore della Comunicazione**  
Pontoriero Dott.ssa Denise Irene Karin  
**Revisore dei Conti**  
Greco Dott.ssa Katia  
**Revisore dei Conti**  
Ongaro Dott. Franco

### SOCI SCOMPARSI

*Ricordiamo con affetto e gratitudine i Soci scomparsi:*

Attanasio Dott. Salvatore <i>Socio Attivo</i>	Mantero Prof. Franco <i>Socio Onorario</i>
Castagnola Prof. Luigi <i>Socio Onorario</i>	Malvano Dott. Mariano <i>Socio Attivo</i>
De Fazio Prof. Pietro <i>Socio Attivo</i>	Pecchioni Prof. Augusto <i>Socio Onorario</i>
Dolci Prof. Giovanni <i>Socio Onorario</i>	Riitano Dott. Francesco <i>Socio Onorario</i>
Duillo Dott. Sergio <i>Socio Onorario</i>	Spina Dott. Vincenzo <i>Socio Onorario</i>
Garberoglio Dott. Riccardo <i>Socio Onorario</i>	Zerosi Prof. Carlo <i>Socio Onorario</i>
Lavagnoli Dott. Giorgio <i>Socio Onorario</i>	



### SOCIO AGGREGATO

Per avere lo status di Socio Aggregato si dovrà presentare la documentazione descritta nel sito [www.endodonzia.it](http://www.endodonzia.it) che sarà valutata dalla Commissione Accettazione Soci. La documentazione che verrà presentata dovrà mostrare con rigore, attraverso casi clinici, l'interessamento del candidato alla disciplina endodontica.

Un meccanismo a punti è stato introdotto per valutare l'ammissibilità del candidato allo "status" di Socio Aggregato: i punti saranno attribuiti in base al tipo di documentazione presentata. Possono accedere alla qualifica di Socio Aggregato tutti i Soci Ordinari della SIE, in regola con le quote associative degli ultimi tre anni, che completino e forniscano la documentazione alla Segreteria Nazionale (Via Pietro Custodi 3, 20136 Milano) entro i termini che verranno indicati all'indirizzo web: [www.endodonzia.it](http://www.endodonzia.it).

La domanda dovrà essere firmata da un Socio Attivo, in regola con la quota associativa per l'anno in corso, il quale è responsabile della correttezza clinica e formale della documentazione presentata.

#### DOCUMENTAZIONE NECESSARIA PER DIVENTARE SOCIO AGGREGATO

Qualsiasi Socio Ordinario, con i requisiti necessari, può presentare la documentazione per ottenere la qualifica di Socio Aggregato. Un meccanismo a punti è stato introdotto per valutare il candidato: un minimo di 80 punti è richiesto per divenire Socio Aggregato.

La documentazione clinica per ottenere la qualifica di Socio Aggregato dovrà presentare almeno sei casi, di cui non più di tre senza lesione visibile nella radiografia preoperatoria e non più di uno di Endodonzia Chirurgica Retrograda.

Nella domanda non potranno essere presentati casi la cui somma superi i 120 punti per la qualifica di Socio Aggregato.

L'aspirante Socio Aggregato potrà presentare la documentazione clinica in più volte, con un minimo di 40 punti per presentazione, in un arco massimo di cinque anni. Il mancato rinnovo della quota associativa, anche per un solo anno, annulla l'iter di presentazione dei casi.

### SOCIO ATTIVO

Per avere lo status di Socio Attivo si dovrà presentare la documentazione descritta nel sito [www.endodonzia.it](http://www.endodonzia.it) che sarà valutata dalla Commissione Accettazione Soci. La documentazione che verrà presentata dovrà mostrare con rigore, attraverso documentazione scientifica e casi clinici, l'interessamento del candidato alla disciplina endodontica. Un meccanismo a punti è stato introdotto per valutare l'ammissibilità del candidato allo status di Socio Attivo: i punti saranno attribuiti in base al tipo di documentazione clin-

ica e scientifica presentata. Possono accedere alla qualifica di Socio Attivo tutti i Soci Ordinari della SIE, in regola con le quote associative degli ultimi tre anni, che completino e forniscano la documentazione alla Segreteria Nazionale (Via Pietro Custodi 3, 20136 Milano) entro i termini che verranno indicati all'indirizzo web: [www.endodonzia.it](http://www.endodonzia.it).

La domanda di ammissione allo status di Socio Attivo rivolta al Presidente della SIE dovrà essere firmata da un Socio Attivo in regola con la quota associativa per l'anno in corso, il quale dovrà aver esaminato e approvato la documentazione. Quest'ultimo è responsabile della correttezza clinica e formale della documentazione presentata.

#### DOCUMENTAZIONE NECESSARIA PER DIVENTARE SOCIO ATTIVO

Qualsiasi Socio Ordinario, con i requisiti necessari, può presentare la documentazione per ottenere la qualifica di Socio Attivo. Il Socio Aggregato che volesse presentare la documentazione scientifica e clinica a integrazione di quella clinica già approvata dalla CAS per lo status di Socio Aggregato, potrà farlo già dall'anno successivo all'ottenimento della sua qualifica.

Un meccanismo a punti è stato introdotto per valutare il candidato a Socio Attivo. Un minimo di 200 punti è richiesto per divenire Socio Attivo.

Nella domanda non potranno essere presentati casi la cui somma superi i 240 punti per la qualifica di Socio Attivo. La documentazione scientifica potrà essere presentata, a completamento della documentazione clinica, solo per la domanda per divenire Socio Attivo e non potrà superare i 100 punti.

La documentazione clinica dovrà presentare un minimo di sei casi, di cui almeno 4 di molar pluriradicolati con delle precise tipologie: tra questi casi almeno uno deve essere un ritrattamento con lesione visibile nella radiografia preoperatoria e dei restanti tre almeno due devono avere una lesione visibile nella radiografia preoperatoria.

La documentazione clinica non deve presentare più di un caso di Endodonzia Chirurgica Retrograda con immagini e non più di uno senza immagini.

La documentazione scientifica non potrà presentare più di due articoli come coautore.

#### MODALITÀ DI DOCUMENTAZIONE DEI CASI CLINICI

Criteri e modalità per la valutazione dei casi clinici idonei ad accedere alle qualifiche di Socio Aggregato e di Socio Attivo sono espressi nell'apposita sezione del Regolamento della Società Italiana di Endodonzia (SIE) all'indirizzo web: [www.endodonzia.it](http://www.endodonzia.it).

## **CRITERI DI VALUTAZIONE**

I casi clinici verranno valutati nel loro complesso, coerentemente con gli scopi e fini della SIE, e devono essere presentati dai Candidati considerando non solo l'aspetto clinico, ma anche quello formale della documentazione presentata.

La documentazione scientifica verrà valutata considerando la classificazione ANVUR delle Riviste Scientifiche, i documenti scientifici dovranno essere tutti di pertinenza endodontica.

## **ADEMPIMENTI DEL CANDIDATO**

La domanda di ammissione allo status di Socio Aggregato/Attivo, rivolta al Presidente della SIE, dovrà pervenire, insieme alla documentazione di seguito elencata, alla Segretaria della SIE con un anticipo di 20 giorni sulle date di riunione della CAS, sufficiente per poter organizzare il materiale dei candidati. Le date di scadenza saranno rese note sul sito. La domanda dovrà essere firmata da un Socio Attivo in regola con la quota associativa per l'anno in corso, il quale dovrà aver esaminato e approvato la documentazione. Quest'ultimo è responsabile della correttezza clinica e formale della documentazione presentata.

## **PRESENTAZIONE DEI CASI ALLA COMMISSIONE**

La presenza del Candidato è obbligatoria durante la riunione della CAS; è altresì consigliabile la presenza del Socio presentatore.

## **LA COMMISSIONE ACCETTAZIONE SOCI**

La CAS (Commissione Accettazione Soci) è formata cinque Membri di indiscussa esperienza clinica, quattro Soci Attivi con almeno cinque anni di anzianità in questo ruolo eletti a ogni scadenza elettorale dall'Assemblea dei Soci Attivi e Onorari e uno dei Past President della Società incaricato dal CD a ogni riunione. Compito della CAS è quello di esaminare e valutare la documentazione presentata dagli aspiranti Soci Aggregati e Soci Attivi. Per rispetto del lavoro dei Candidati e per omogeneità di giudizio, in ogni riunione CAS verranno valutati non più di 12 candidati a Socio Attivo; resta libero, invece, il numero dei candidati a Socio Aggregato valutabile in una singola riunione. Il Consiglio Direttivo (CD) incaricando la Commissione Accettazione Soci (CAS) la rende responsabile dell'applicazione delle regole descritte nell'articolo 2 del regolamento. Il giudizio della CAS è insindacabile.

## **MEMBRI DELLA COMMISSIONE ACCETTAZIONE SOCI 2019**

**Past President della Società**  
Dott. Enrico Cassai  
Dott. Marco Colla  
Dott. Mario Mancini  
Dott. Pier Luigi Schirosa

# HYGIENIO: IL SANIFICATORE

L'evoluzione nel campo della disinfezione



Hygienio è l'innovativo metodo di applicazione a caldo del disinfettante sulle superfici, permette una **disinfezione dell'ambiente operativo a 360°**: innumerevoli prove e test di laboratorio hanno certificato un abbattimento della carica microbica superiore al 99,999%.

Hygienio utilizza un **sistema tecnologico brevettato** in grado di miscelare in modo automatico ed equilibrato vapore saturo secco e disinfettante nebulizzato, questa esclusiva tecnologia permette di disinfettare tutte le superfici presenti in un ambiente rapidamente e con **riutilizzo immediato degli spazi e delle attrezzature**.

L'attività di disinfezione diviene **semplice e rapida** grazie ad una pratica lancia irrigatrice ed evita il contatto diretto con le superfici da e verso l'operatore eliminando il rischio di trasporto di cariche batteriche.

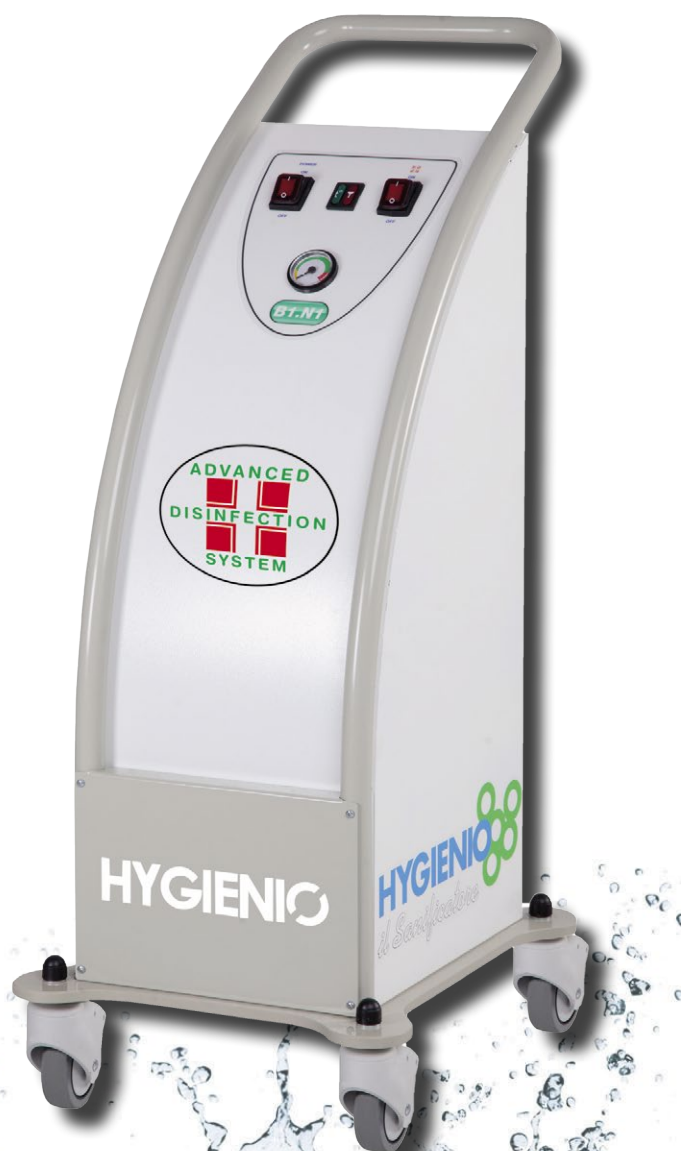La miscela vapore-disinfettante generata da Hygienio a contatto con le superfici condensa per poi asciugarsi rapidamente depositando un sottile strato omogeneo di disinfettante.

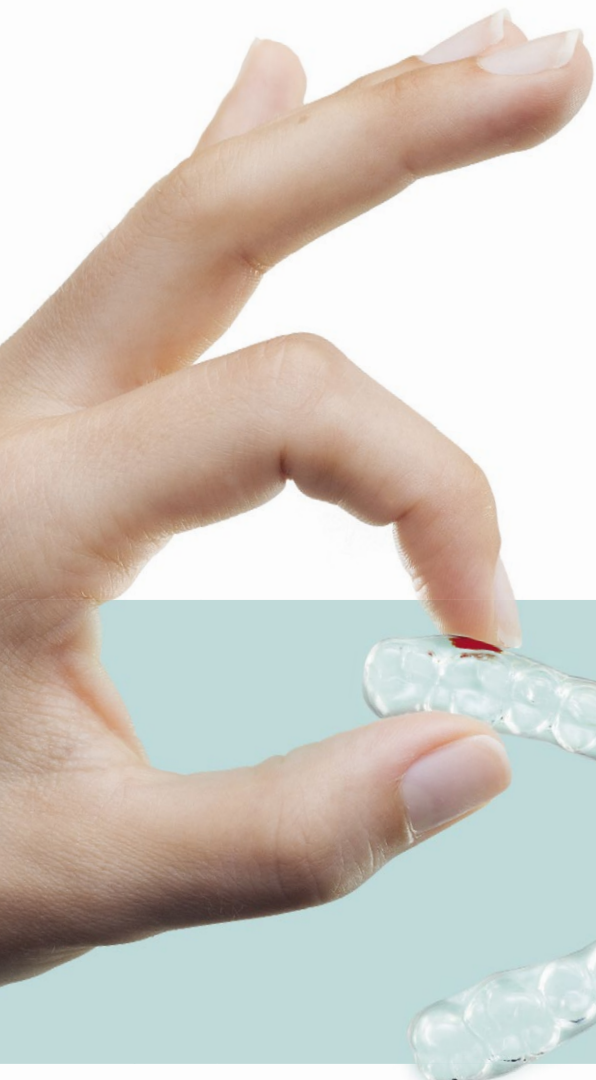La pellicola di disinfettante essendo finissima ed autoestinguente in 18/24 ore, non necessita di risciacqui e quindi garantisce un **effetto batteriostatico duraturo nel tempo**.

Il disinfettante consigliato, **Adantium Plus**, è un preparato di sintesi di ultima generazione a spettro totale di abbattimento: **batteri, micobatteri, spore funghi e virus**, notificato presso l'istituto superiore di sanità italiano (CE0373) e pertanto risponde a tutte le normative vigenti dettate dal CEN (Comitato Europeo Normativo).

Adantium Plus risulta **atossico** al 99,999% e **biodegradabile** al 94%, e garantisce quindi l'uso in **totale sicurezza** e conformità ai disposti della Legge sulla Sicurezza (D.lgs. 81/08 e s.m).

Un'adeguata ed integrale disinfezione dello Studio Odontoiatrico è finalmente possibile con Hygienio ed Adantium Plus.





## L'ultima generazione di allineatori ortodontici

F22 è un sistema di sottili allineatori trasparenti realizzati su misura con un esclusivo materiale plastico super trasparente per guidare delicatamente lo spostamento graduale e progressivo dei denti verso la posizione desiderata.

Tutto il ciclo di fabbricazione del sistema F22, dalla progettazione alla produzione, è interamente **svolto in Italia**. Frutto della ricerca pluridecennale condotta dal team del **Prof. Siciliani** presso l'**Università di Ferrara**, F22 nasce da uno studio sui pazienti che si perpetua negli anni e che ha permesso di analizzare ogni aspetto di questo trattamento, apportando continue evoluzioni fino a renderlo il sistema di **mascherine trasparenti** più avanzato attualmente proposto nel mercato. Gli allineatori sono realizzati a Padova, nel **Centro F22** di Sweden & Martina, mediante stampanti tridimensionali di ultima generazione e sono controllati in ogni fase della lavorazione.

F22 offre ai dentisti il servizio di tutoraggio per tutta la durata del trattamento, consentendo, se desiderato, un confronto diretto e immediato con un team di ortodontisti esperti. Attraverso un esclusivo **visualizzatore 3D** l'odontoiatra può interagire con il team di ortodontisti dell'Università di Ferrara, e verificare il **piano di trattamento**. Lo stesso visualizzatore consente di illustrare al paziente le aspettative di progressivo spostamento dei denti fino al risultato ottimale pianificato. L'esclusivo materiale stratificato **EvoFlex** con cui è prodotto F22 garantisce elevata flessibilità e rende l'allineatore fino al 17% più trasparente di qualsiasi altro allineatore. L'assenza di difetti strutturali, corretti e verificati manualmente prima della consegna al cliente, permette alla luce di passare fino al 20% in più rispetto a quanto avviene con altri allineatori, per un effetto ancora più naturale. Le ricerche e gli studi pubblicati dimostrano che anche in condizioni estreme la superficie perfettamente liscia e le proprietà del materiale garantiscono assenza di ritenzione di pigmenti: F22 Aligner mantiene inalterata la

sua **trasparenza** nel tempo. Grazie al contatto completo tra le mascherine e l'arcata, il controllo dei movimenti dentari è molto preciso e i risultati altamente predicibili. Le forze impresse, seppur leggere, sono trasmesse completamente, per un controllo totale dei movimenti dentari, pertanto l'allineatore F22 è in grado di attivare i movimenti di correzione sin dal primo giorno in cui viene indossato. È più **confortevole** per il paziente, poiché minimizza i possibili dolori durante lo spostamento progressivo dei denti, inoltre protegge dal bruxismo, in quanto elastico. Ha una **resistenza allo strappo** e alla trazione del 300% più alta rispetto alla media di altri materiali. L'allineatore è molto confortevole per il paziente, in virtù dell'**elevata elasticità** e dei margini arrotondati e privi di rugosità. I bordi sono rifiniti a mano con particolare cura attraverso una speciale tecnica messa a punto dalla **Scuola di Specializzazione in Ortognatodonzia di Ferrara**.

Per maggiori informazioni si consulti: [www.f22aligner.com](http://www.f22aligner.com)



## Morita: Modern treatment systems for perfect procedures

### Endodonzia Sicura... passo per passo

Il primo passo in ogni trattamento endodontico di successo è **una diagnosi precisa** basata su immagini 3D accurate ad alta risoluzione fornite dalla tomografia computerizzata a cone-beam (CBCT).

Morita supporta questi obiettivi diagnostici con il suo nuovo sistema a raggi X **Veraview X800** per immagini 3D, panoramiche e cefalometriche.

#### Vantaggi

- Questo apparecchio offre un livello di qualità dell'immagine senza precedenti in un sistema di imaging 2D/3D (risoluzione: 2,5 LP/mm MTF).
- È versatile! Non solo produce immagini rapide e accurate, ma fornisce anche la massima sicurezza per l'operatore e il paziente con dosi minime efficaci (ALARA). Infatti il sistema utilizza il collaudato campo R100 di riduzione della dose con la sua forma Ruleaux (triangolare).
- Esposizioni in modalità di 180 gradi e 360 gradi, esposizioni cefalometriche veloci in soli 3,5 secondi, o una funzione di ricostruzione dello zoom che crea una registrazione di 80 µm da una registrazione voxel 125 µm senza richiedere un Retake.

#### Morita è inoltre sinonimo di...

**Precisione e sicurezza per il canale radicolare:** una volta che l'endodontista procede alle effettive procedure introrali, sono disponibili diversi strumen-



ti di alta qualità per assistere il suo delicato lavoro. Per una comoda preparazione della cavità di accesso, Morita offre le **potenti turbine TwinPower** e i **manipoli della serie TorqTech e Tokyo**; offrendo una coppia massima a piccoli diametri dello strumento, forniscono una buona vista dell'area di lavoro e spazio sufficiente durante il trattamento dei molari.

**Nelle fasi successive essenziali del trattamento – misurazione, strumentazione, riempimento e polimerizzazione** – Morita offre una soluzione innovativa per tutti questi tre step, **il nuovo motore endodontico TriAuto ZX2 con localizzatore Apicale**.

**ITriAuto ZX2** è l'unico sistema del suo genere che integra la localizzazione Apicale e la preparazione del canale radicolare in un unico manipolo: è sta-

to progettato per la massima sicurezza ed è dotato sia della funzione OTR che della nuova funzione ottimale glide-path.

**L'OTR** cambia la direzione di rotazione del file non appena viene superato il livello di coppia pre-impostato singolarmente. Dopo aver invertito la rotazione di 90 gradi, torna a ruotare nella direzione di taglio; se la coppia è ancora troppo alta, il processo viene ripetuto tre-quattro volte dopo un ulteriore 180 gradi. Questo sistema aiuta a conservare la morfologia originale del sistema dei canali radicolari e facilita la rimozione affidabile dei detriti. Tutti questi fattori si combinano per abbreviare il tempo di trattamento.

**L'OGP** fornisce una preparazione rapida e automatizzata del glide-path, che è la prima fase di preparazione effettiva, e quindi prepara il canale radicolare per procedure endodontiche sicure. In combinazione con la funzione del dispositivo, il clinico può portare lo strumento endodontico fino alla lunghezza di lavoro senza fratture, ostruzione o formazione di sporgenza. Semplicemente ingegnoso e assolutamente sicuro. Un display LCD fornisce un feedback completo dal canale radicolare mostrando i dati di misura esatti acquisiti dal manipolo, soprattutto la distanza del file dall'apice.

Quindi il **TriAuto ZX2** conserva la struttura dentale naturale e rende il trattamento ancora più efficiente perché è richiesto solo un numero limitato di file.

Un'altra caratteristica sorprendente di questo sistema endodontico è la sua **piccola testina e il peso ridotto** (140 g), che lo rende molto maneggevole. Essendo un **apparecchio cordless** migliora significativamente la flessibilità di trattamento e ottimizza il flusso di lavoro clinico. Il funzionamento semplice e intuitivo e le funzioni automatizzate assicurano risultati affidabili e sicuri in ogni momento.

#### LA MISSION DI MORITA

Morita offre un portfolio completo di prodotti di alta qualità che coprono tutte le fasi del trattamento, dalla diagnosi al controllo, permettendo di lavorare sempre in modo efficiente, ergonomico e sicuro. I dentisti apprezzeranno la convenienza e i pazienti apprezzeranno il comfort di un trattamento migliorato. Il nuovo sistema di imaging Veraview X800 2D/3D e il nuovo motore TriAuto ZX2 endo con localizzatore Apex mettono in primo piano la sicurezza e rappresentano nuovi standard nei loro segmenti. Queste soluzioni sottolineano l'impegno di Morita: rispondere alle esigenze degli utenti e dei pazienti in ogni fase e continuare a fornire il "Gold standard" per il successo del trattamento nella pratica endodontica.

# EdgeEndo

PERFORMANCE. PRICE. TECHNOLOGY.

**E**dgeEndo offre prodotti e soluzioni endodontiche di altissima qualità con tecnologie all'avanguardia e un ottimo rapporto qualità/prezzo.

Con le linee **EdgeTaper**, **EdgeTaper Platinum**, **EdgeOne Fire** (reciprocanti) i file EdgeEndo garantiscono velocità e sicurezza nei trattamenti endodontici e grandi vantaggi sia per gli operatori che per i pazienti.

L'applicazione alla strumentazione rotante della nuova tecnologia **FireWire™** rende gli strumenti più flessibili e più resistenti alla fatica ciclica.

Consente altresì un approccio minimamente invasivo sulla dentina, in virtù di un minore ritorno elastico; ciò permette agli strumenti di rispettare meglio l'anatomia originale e seguire il tragitto canalare in modo più semplice, preciso ed efficace.

La linea di file reciprocanti EdgeOne Fire riduce il numero di strumenti necessari per la sagomatura, gli strumenti presentano una conicità variabile, con una riduzione del diametro massimo delle spire (MFD), che facilitano il taglio e minimizzano l'effetto di avvitemento. Inoltre grazie al nuovo trattamento **FireWire™** gli strumenti risultano due volte più resistenti alla fatica ciclica rispetto agli altri.

## La parola ai clinici che usano con grande soddisfazione i file EdgeEndo

“Ho recentemente paragonato i file **EdgeEndo NiTi** alle sistematiche da me utilizzate. Sono stato piacevolmente sorpreso dalla loro flessibilità, durezza e resistenza alla frattura. Vantaggio più importante per me è stato



poterli utilizzare senza apportare variazioni alla mia tecnica di preparazione, ottenendo risultati altrettanto validi con un significativo risparmio economico. EdgeEndo è entrato a far parte della quotidianità dei miei trattamenti clinici”.  
*Prof. Gianluca Gambarini, Università La Sapienza, Roma*

“Utilizzando gli strumenti rotanti **EdgeEndo** ho trovato una sequenza molto semplice anche per i casi più complessi. Gli EdgeEndo Ni-Ti più recenti, ancora più flessibili e resistenti, possono essere utilizzati per più casi ma, allo stesso tempo, essere considerati monouso per il loro costo.

Qualità, semplicità e risparmio: evoluzione per la moderna endodonzia alla portata di tutti.”

*Dott. Mario Marrone, Odontoiatra, Palermo*

**EDGEONE**  
FIRE™

File NiTi trattati termicamente (Firewire™)

Conicità variabile

Lunghezza manico 12 mm (rivestimento dorato)

Codice colore ISO

Stop in silicone e anelli di calibrazione

Sezione a parallelogramma

Disponibili in 3 lunghezze: 21, 25, 31 mm

## Per info

**Dental Trey srl** | Via Partisani, 3 | 47016 Fiumana-Predappio (FC), Italia  
T +39 0543 929111 | F +39 0543 940659 | [www.dental Trey.it](http://www.dental Trey.it) | [commerciale@dental Trey.it](mailto:commerciale@dental Trey.it)

## VITA SOCIETARIA

# Moderna Endodonzia tra Tecnologia ed Esperienza

**Bologna, 7-9 Novembre 2019**  
**Palazzo della Cultura e dei Congressi**

Resoconto del 36° Congresso Nazionale SIE



**N**elle giornate di Giovedì 7, Venerdì 8 e Sabato 9 Novembre si è svolto presso il Palazzo della Cultura e dei Congressi di Bologna l'importante Congresso Nazionale della Società Italiana di Endodonzia (SIE), dal titolo **Moderna Endodonzia tra tecnologia ed esperienza.**

Il Congresso è stato accreditato ECM dal CIC Provider e patrocinato dal Comune di Bologna, da FNOMCeO, dal CLOPD - Collegio dei Docenti Universitari di discipline Odontostomatologiche - da ANDI Nazionale e AIO nazionale, dall'Ordine dei Medici e degli Odontoiatri di Bologna, dalle Università di Bologna, Ferrara, Modena-Reggio Emilia e Parma.

L'evento, supportato da ben

26 Aziende sponsor e 3 Media Partner, ha animato l'amata sede di Bologna, sede prestigiosa e facilmente raggiungibile, che, per tre giorni, è diventata la capitale indiscussa dell'Endodonzia. I lavori hanno avuto inizio Giovedì mattina, nella Sala Europa, con l'**incontro conclusivo dei SIE ENDODONTIC COURSES 2019**: gli iscritti ai vari corsi regionali, con sede a Bari, Brescia, Genova, Spoleto - per i corsi base - e Bologna - per il corso advanced - hanno potuto seguire le relazioni della *Prof.ssa Elisabetta Cotti* e del *Dott. Luca Venuti*, i quali hanno brillantemente approfondito un argomento sempre attuale e ostico: i riassorbimenti radicolari. Al termine della loro splendida relazione dal titolo **Strategie cliniche per la**



**diagnosi e il trattamento dei riassorbimenti radicolari patologici** è seguita la consegna delle pergamene di partecipazione da parte del Past President, Prof. Francesco Riccitiello e del Coordinatore Culturale, Dott. Andrea Polesel, in rappresentanza della Società. Nel pomeriggio, sempre in

Sala Europa, tutto esaurito per il classico **CORSO PRE-CONGRESSO**: il nostro Socio Attivo *Dott. Claudio Pisacane* e lo special guest *Dott. Lorenzo Vanini* hanno rapito l'attenzione dei presenti con la loro relazione dal titolo: **Trattamento e prognosi a lungo termine dei traumi dentali**, approfondendo



## VITA SOCIETARIA



l'argomento sia dal punto di vista endodontico che ricostruttivo. La consueta Assemblea dei Soci Attivi chiudeva la prima giornata di lavori. Venerdì 9, dopo la **Cerimonia di Apertura dei Lavori e del Saluto delle Autorità**, nella cornice di un auditorium gremito di colleghi appassionati di Endodonzia, si è svolta la **prima sessione congressuale** affidata al *Prof. Carlo Prati* e al nostro *Past President Dott. Fabio Gorni*; dopo il break di metà mattina, i lavori venivano ripresi dalla *Dott.ssa Maria Teresa Sberna*, allora Vice Presidente SIE, seguita dal *Prof. Gianluca Gambarini* e dai *Dott. Alberto Mazzocco* ed *Enrico*

*Cassai*, a completamento della **seconda sessione**. Stessa sala, stessa magica atmosfera, dopo il lunch break, per la terza sessione, quella delle **Master Clinician Session Sponsorizzate** guidate dal *Dott. Italo di Giuseppe* per *Sweden&Martina* e il *Dott. Enrico Cassai* per *Dentsply Sirona*. Le due Master Clinician Session Sponsorizzate sono state intervallate da alcune comunicazioni societarie a cura del Segretario Nazionale, il *Dott. Filippo Cardinali*, che ha introdotto la Presentazione del Consensus intersocietario a cura della *Prof.ssa Elisabetta Cotti* dal titolo: **Lo Screening delle infezioni dentali nel paziente in attesa di chirurgia**

**cardiovascolare** a cui hanno partecipato, oltre alla SIE, anche SIdP, AIE, SIC, SICCH, ANMCO, e il **Position Statement** della *Società Italiana di Endodonzia* a cura della *Prof.ssa Claudia Dettori* dal titolo: **Il trattamento endodontico dei pazienti a rischio di Osteonecrosi dei Mascellari associata all'utilizzo dei farmaci anti-riassorbimento**. In parallelo, in Sala Italia, **si sono svolte le Sessioni finali dei Premi Riccardo Garberoglio** (9.15-11.00), **Giorgio Lavagnoli** (11.30-13.30) e **Francesco Riitano** (14.30-16.15); fasi finali anche del **Premio Miglior Poster SIE e SESSIONE POSTER AFFISSIONI CARTACEE**, rispettivamente in Sala Verde e Area Espositiva.

Dalle 17.00 alle 19.00 si sono svolti i **14 Teatri Clinici** organizzati dalla SIE e le **10 Tavole Cliniche Sponsorizzate** a cura di Dentsply Sirona, Simit Next, Fotona D.O.O., Sweden&Martina, Septodont, JMorita Europe GMBH, Komet Italia, Acteon, Coltene Italia, Giovanni Ognà & Figli, ciascuno dei quali ripetuti tre volte in modo da dare la possibilità ai colleghi presenti di partecipare a quelli di maggiore interesse per loro. Tra i Teatri Clinici, al primo piano, in lecture room dedicate, anche i Teatri che hanno visto come protagonisti relatori ospiti in rappresentanza di alcune tra le più autorevoli Società Scientifiche Italiane (**AIC, AIOP, SIdP**). La graditissima novità di



## VITA SOCIETARIA

quest'anno è stata l'introduzione delle **cuffiette**.

Per garantire la resa acustica di ogni Teatro Clinico/Tavola Clinica infatti è stato predisposto l'utilizzo di cuffiette con 20 canali regolabili e sintonizzabili in base ai Teatri Clinici/Tavole Cliniche frequentati.

La **Cena Sociale**, presso il suggestivo ed elegante **La Porta Restaurant**, ha concluso in maniera rilassata e conviviale una giornata intensa e ricca di contenuti.

Durante la cena, la Dott.ssa Maria Teresa Sberna, allora Vice Presidente SIE, ha omaggiato **i tre nuovi Soci Attivi, il Dott. Gianluca Plotino, il Dott. Pasquale Paone e il Dott. Andrea Lamparelli**.

Sabato 10, terzo e ultimo giorno di Congresso, Sala Europa ancora gremita per seguire le ultime due sessioni, la quinta e la sesta, che vedevano protagonisti rispettivamente i Prof. Maurizio Bossù e Giovanni Olivi e i Dott.ri Italo Di Giuseppe e Franco Ongaro e il Prof. Vito Antonio Malagnino e i Dott.ri Mauro Rigolone, Andrea Polesel e

Umberto Uccioli. Contemporaneamente, le due interessanti **Sessioni di Ricerca Libera** in Sala Italia e le molto apprezzate **Tavole Cliniche sponsorizzate** nell'area espositiva, che hanno intrattenuto i partecipanti, tutti molto interessati e colpiti dall'offerta e dalla possibilità di fare anche workshop pratici a discrezione dell'Azienda. A seguire, si è proceduto alla nomina dei **Vincitori delle 4 Sessioni Finali dei Premi SIE**.

**Premio Riccardo Garberoglio**  
**Effetto antibatterico di due peptidi sintetici di derivazione anticorpale nei confronti di Enterococcus faecalis**  
 Giovanni Mergoni\*, Maddalena Manfredi, Pio Bertani, Tecla Ciociola, Stefania Conti, Laura Giovati

**Premio Giorgio Lavagnoli**  
**Trattamento di canali calcificati con tecnica di Endodonzia guidata: case series**  
 Antonietta Bordone\*, Cauris Cauvrechel

### VISTO IL PERDURARE DELLA SITUAZIONE CRITICA COVID-19

il nostro IV Congresso Internazionale di novembre 2020 è stato rimandato all'anno venturo (nuove date 11-13 Novembre 2021).

In alternativa, nelle date storiche del Congresso annuale il Consiglio Direttivo sta organizzando per i propri Soci un innovativo Evento che si svolgerà via Web.

Seguiranno aggiornamenti!

**Premio Francesco Riitano**  
**Valutazione della qualità del sigillo canalare mediante micro-CT: cono singolo con bioceramiche VS onda continua di condensazione VS guttaperca calda veicolata da carrier**  
 Edoardo Moccia\*, Alessandro Dell'Acqua, Mario Alovizi, Giorgia Carpegna, Allegra Comba, Damiano Pasqualini, Elio Berutti

**Premio Miglior Poster SIE**  
**Morfologia del sistema endodontico negli incisivi laterali inferiori: uno studio in vivo attraverso la tomografia computerizzata con beam**  
 Linda Quero\*, Giovanni Schianchi, Federico Valenti Obino, Massimo Galli, Luca Testarelli, Gianluca Gambarini  
 Poi si è passati alla nomina dei **Vincitori dei contest**.

**Premio Contest #LivingSIE**  
 Eleonora Caroglio\*

**Premio Contest #MycongresSIE**  
 Stefano Pagnoni\*

**Premio Sponsor Tour SIE**  
 Andrea Cristini\*

L'estrazione e la premiazione del vincitore dello **Sponsor Tour 2019** ha seguito la premiazione dei **contest fotografici, #livingSIE e #mycongresSIE**, da parte del Coordinatore della Comunicazione, la Dott.ssa Denise I.K. Pontoriero. I due contest #livingSIE e #mycongresSIE, una novità assoluta di questo Congresso, hanno coinvolto ed entusiasmato i nostri colleghi, specialmente i più giovani, ma non solo, rendendo il nostro evento "virale" anche sui Social Network. Il Congresso si concludeva con l'intervento finale del Segretario Nazionale, il Dott. Filippo Cardinali, che, davanti a un pubblico rimasto numeroso fino alla fine dei lavori, ha ringraziato i partecipanti a nome della Società.



## GUIDELINES FOR AUTHORS

### *Giornale Italiano di Endodonzia*

was founded in 1987 and is the official journal of Società Italiana di Endodonzia, SIE (Italian Society of Endodontics) <https://www.endodonzia.it/>

It is a peer-reviewed journal, only available in electronic format and publishes original scientific articles, reviews, clinical articles and case reports in the field of Endodontology. Scientific contributions dealing with health, injuries to and diseases of the pulp and periradicular region, and their relationship with systemic well-being and health. Original scientific articles are published in the areas of biomedical science, applied materials science, bioengineering, epidemiology and social science relevant to endodontic disease and its management, and to the restoration of root-treated teeth. In addition, review articles, reports of clinical cases, book reviews, summaries and abstracts of scientific meetings and news items are accepted. Please read the instructions below carefully for details on the submission of manuscripts, the journal's requirements and standards as well as information concerning the procedure after a manuscript has been accepted for publication in *Giornale Italiano di Endodonzia*. *Giornale Italiano di Endodonzia* is indexed in Scopus, Science Direct, Embase and published online by Ariesdue, Milan, Italy and hosted by PAGEPress, Pavia, Italy. All articles are available on [www.giornaleitalianoendodonzia.it](http://www.giornaleitalianoendodonzia.it). The journal is issued twice a year, in June and November.

Authors are encouraged to visit [www.giornaleitalianoendodonzia.it](http://www.giornaleitalianoendodonzia.it) for further information on the preparation and submission of articles and figures.

### Ethical guidelines

*Giornale Italiano di Endodonzia* adheres to the below ethical guidelines for publication and research.

### Authorship and Acknowledgements

Authors submitting a paper do so on the understanding that the manuscript has been read and approved by all authors and that all authors agree to the submission of the manuscript to the *Giornale Italiano di Endodonzia*. *Giornale Italiano di Endodonzia* adheres to the definition of authorship set up by The International Committee of Medical Journal Editors (ICMJE). According to the ICMJE, authorship criteria should be based on 1) substantial contributions to conception and design of, or acquisition of data or analysis and interpretation of data, 2) drafting the article or revising it critically for important intellectual content and 3) final approval of the version to be published. Authors should meet conditions 1, 2 and 3. It is a requirement that all authors

have been accredited as appropriate upon submission of the manuscript. Contributors who do not qualify as authors should be mentioned under Acknowledgements.

### Manuscript preparation

Manuscripts should be uploaded as Word (.doc) or Rich Text Format (.rtf) files (not write-protected) plus separate figure files: TIF, EPS, JPEG files are acceptable for submission.

The text file must contain the **abstract, main text, references, tables and figure legends**, but no embedded figures or title page. The title page should be provided as a separate file. In the main text, please reference figures as for instance **figure 1, figure 2** etc to match the tag name you choose for the individual figure files uploaded.

Please note that **manuscripts must be written in English**. Authors whose native language is not English are strongly advised to have their manuscript checked by a language editing service or by a native English speaker prior to submission.

### Manuscript Types Accepted

**Original Scientific Articles** must describe significant and original experimental observations and provide sufficient detail so that the observations can be critically evaluated and, if necessary, repeated. Original Scientific Articles must conform to the highest international standards in the field.

**Review Articles** are accepted for their broad general interest; all are refereed by experts in the field who are asked to comment on issues such as timeliness, general interest and balanced treatment of controversies, as well as on scientific accuracy. Reviews should generally include a clearly defined search strategy and take a broad view of the field rather than merely summarizing the authors' own previous work. Extensive or unbalanced citation of the authors' own publications is discouraged.

**Mini Review Articles** are accepted to address current evidence on well-defined clinical, research or methodological topics. All are refereed by experts in the field who are asked to comment on timeliness, general interest, balanced treatment of controversies, and scientific rigor. A clear research question, search strategy and balanced synthesis of the evidence is expected. Manuscripts are limited in terms of word-length and number of figures.

**Clinical Articles** are suited to describe significant improvements in clinical practice such as the report of a novel technique, a breakthrough in technology or practical approaches to recognised clinical challenges. They should conform to the highest scientific and clinical practice standards.

**Case Reports** or **Case Series** illustrating unusual and clinically relevant observations are acceptable, but they must be of sufficiently

high quality to be considered worthy of publication in the Journal. On rare occasions, completed cases displaying nonobvious solutions to significant clinical challenges will be considered. Illustrative material must be of the highest quality and healing outcomes, if appropriate, should be demonstrated.

### Manuscript Format

The **official language** of the publication is **English**. It is preferred that manuscript is professionally edited. All services are paid for and arranged by the author and use of one of these services does not guarantee acceptance or preference for publication.

Authors should pay special attention to the **presentation** of their research findings or clinical reports so that they may be communicated clearly.

Technical **jargon** should be avoided as much as possible and clearly explained where its use is unavoidable. **Abbreviations** should also be kept to a minimum, particularly those that are not standard. *Giornale Italiano di Endodonzia* adheres to the conventions outlined in *Units, Symbols and Abbreviations: A Guide for Medical and Scientific Editors and Authors*. If abbreviations are used in the text, authors are required to write full name+abbreviation in brackets [e.g. Multiple Myeloma (MM)] the first time they are used, then only abbreviations can be written (apart from titles; in this case authors have to write always the full name). If names of equipments or substances are mentioned in the text, brand, company names and locations (city and state) for equipment and substances should be included in parentheses within the text.

The **background** and **hypotheses** underlying the study, as well as its main conclusions, should be clearly explained.

Titles and abstracts especially should be written in language that will be readily intelligible to any scientist.

### Structure

All manuscripts submitted to *Giornale Italiano di Endodonzia* should include Title Page, Abstract, Main Text, References, Clinical Relevance, Conflict of Interest and Acknowledgements, Tables, Figures and Figure Legends as appropriate.

Title Page should bear:

- I. Title, which should be concise as well as descriptive (no more than 150 letters and spaces);
- II. Initial(s) and last (family) name of each author;
- III. Name and address of department, hospital or institution to which the work should be attributed;
- IV. Running title (no more than 30 letters and spaces);
- V. Three to five key words (in alphabetical order);

VI. Name, full postal address, telephone, fax number and e-mail address of author responsible for correspondence (Corresponding Author).

**Abstracts** should be no more than 250 words giving details of what was done.

**Abstract for Original Scientific Articles** should be no more than 250 words giving details of what was done using the following structure:

- **Aim:** give a clear statement of the main aim of the study and the main hypothesis tested, if any.
- **Methodology:** describe the methods adopted including, as appropriate, the design of the study, the setting, entry requirements for subjects, use of materials, outcome measures and statistical tests.
- **Results:** give the main results of the study, including the outcome of any statistical analysis.
- **Conclusions:** state the primary conclusions of the study and their implications. Suggest areas for further research, if appropriate.

**Abstract for Review Articles** should be non-structured, no more than 250 words giving details of what was done including the literature search strategy.

**Abstract for Mini Review Articles** should be non-structured of no more than 250 words, including a clear research question, details of the literature search strategy and clear conclusions.

**Abstract for Case Reports and Case Series** should be no more than 250 words using the following structure:

- **Aim:** give a clear statement of the main aim of the report and the clinical problem which is addressed.
- **Summary:** describe the methods adopted including, as appropriate, the design of the study, the setting, entry requirements for subjects, use of materials, outcome measures and analysis if any.
- **Key learning points:** provide up to five short, bullet-pointed statements to highlight the key messages of the report. All points must be fully justified by material presented in the report.

**Abstract for Clinical Articles** should be no more than 250 words using the following structure:

- **Aim:** give a clear statement of the main aim of the report and the clinical problem which is addressed.
- **Methodology:** describe the methods adopted.
- **Results:** give the main results of the study.
- **Conclusions:** state the primary conclusions of the study.

## THE STRUCTURE

**Main text for Original Scientific Articles** should include Introduction, Materials and Methods, Results, Discussion and Conclusion.

**Introduction:** should be focused, outlining the historical or logical origins of the study and gaps in knowledge. Exhaustive literature reviews are not appropriate. It should close with the explicit statement of the specific aims of the investigation, or hypothesis to be tested.

**Material and Methods** must contain sufficient detail such that, in combination with the references cited, all clinical trials and experiments reported can be fully reproduced.

(I) *Clinical Trials:* should be reported using the CONSORT guidelines available at [www.consort-statement.org](http://www.consort-statement.org) A CONSORT checklist and flow diagram (as a Figure) should also be included in the submission material.

(II) *Experimental Subjects:* experimentation involving **human subjects** will only be published if such research has been conducted in full accordance with ethical principles, including the World Medical Association Declaration of Helsinki (version 2008) and the additional requirements, if any, of the country where the research has been carried out. Manuscripts must be accompanied by a statement that the experiments were undertaken with the understanding and written consent of each subject and according to the above mentioned principles. A statement regarding the fact that the study has been independently reviewed and approved by an ethical board should also be included. Editors reserve the right to reject papers if there are doubts as to whether appropriate procedures have been used. When **experimental animals** are used the methods section must clearly indicate that adequate measures were taken to minimize pain or discomfort. Experiments should be carried out in accordance with the Guidelines laid down by the National Institute of Health (NIH) in the USA regarding the care and use of animals for experimental procedures or with the European Communities Council Directive of 24 November 1986 (86/609/EEC) and in accordance with local laws and regulations. All studies using human or animal subjects should include an explicit statement in the Material and Methods section identifying the review and ethics committee approval for each study, if applicable. Editors reserve the right to reject papers if there is doubt as to whether appropriate procedures have been used.

(III) *Suppliers* of materials should be named and their location (Company, town/city, state, country) included.

**Results** should present the observations with minimal reference to earlier literature or to possible interpretations. Data should not be duplicated in Tables and Figures.

**Discussion** may usefully start with a brief summary of the major findings, but repetition of parts of the abstract or of the results section should be avoided. The Discussion section should progress with a review of the methodology before discussing the results in light of previous work in the field. The Discussion should end with a brief conclusion and a comment on the potential clinical relevance of the findings. Statements and interpretation of the data should be appropriately supported by original references.

**Conclusions** should contain a summary of the findings.

### Main Text of Review Articles

should be divided into Introduction, Review and Conclusions.

The **Introduction** section should be focused to place the subject matter in context and to justify

the need for the review. The **Review** section should be divided into logical subsections in order to improve readability and enhance understanding. Search strategies must be described and the use of state-of-the-art evidence-based systematic approaches is expected. The use of tabulated and illustrative material is encouraged. The **Conclusion** section should reach clear conclusions and/or recommendations on the basis of the evidence presented.

### Main Text of Mini Review Articles

should be divided into Introduction, Review and Conclusions; please note that the **Conclusions** section should present clear statements/recommendations and suggestions for further work. The manuscript, including references and figure legends, should not normally exceed 4,000 words.

### Main Text of Case Reports and Clinical Articles

should be divided into Introduction, Report, Discussion and Conclusion. They should be well illustrated with clinical images, radiographs, diagrams and, where appropriate, supporting tables and graphs. However, all illustrations must be of the highest quality.

## IMPORTANT TO KNOW

Manuscript that do not conform to the general aims and scope of the Journal will be returned immediately without review. All other manuscripts will be reviewed by experts in the field (generally two referees). *Giornale Italiano di Endodonzia* aims to forward referees' comments and to inform the corresponding author of the result of the review process. Manuscripts will be considered for fast-track publication under special circumstances after consultation with the Editor. *Giornale Italiano di Endodonzia* uses **double blinded review** which means that the names of the reviewers will thus not be disclosed to the author submitting a paper and the name(s) of the author(s) will not be disclosed to the reviewers. To allow double blinded review, please submit your main manuscript and title page as separate files.

**Acknowledgements.** *Giornale Italiano di Endodonzia* requires that all sources of institutional, private and corporate financial support for the work within the manuscript must be fully acknowledged, and any potential conflicts of interest noted. Grant or contribution numbers may be acknowledged, and principal grant holders should be listed. Acknowledgements should be brief and should not include thanks to anonymous referees and editors. Under this section please specify contributors to the article other than the authors accredited. Please also include specifications of the source of funding for the study.

**References.** It is the policy of the Journal to encourage reference to the original papers rather than to literature reviews. Authors should





therefore keep citations of reviews to the absolute minimum.

References should be prepared according to the **Vancouver style**. References must be numbered consecutively in the order in which they are first cited in the text (not alphabetical order), and they must be identified in the text by Arabic numerals in brackets [example (34)]. References to personal communications and unpublished data should be incorporated in the text and not placed under the numbered references [Example: (Wright 2011, unpublished data) or (Wright 2011, personal communication)]. Where available, URLs for the references should be provided directly within the MS-Word document.

References in the References section must be prepared as follows:

- I. more than three authors cite 3 authors et al. If the paper has only 4 authors, cite all authors; e.g. *Prati G, Lotti M, Russo F et al.*
- II. title style: please use a capital letter only for the first word of the title;
- III. journal titles mentioned in the References list should be abbreviated according to the following websites:
  - a. ISI Journal Abbreviations Index (<https://www.library.caltech.edu/journal-title-abbreviations>);
  - b. Biological Journals and Abbreviations (<http://home.ncifcrf.gov/research/bja>);
  - c. Medline List of Journal Titles ([https://www.nlm.nih.gov/bsd/serfile\\_addedinfo.html](https://www.nlm.nih.gov/bsd/serfile_addedinfo.html));
- IV. put year after the journal name;
- V. never put month and day in the last part of the references;
- VI. cite only the volume (not the issue in brackets);
- VII. pages have to be abbreviated, e.g. 351-8.

We recommend the use of a tool such as EndNote or Reference Manager for reference management and formatting. EndNote reference styles can be searched for here: [www.endnote.com/support/enstyles.asp](http://www.endnote.com/support/enstyles.asp). To ensure the correct citation format, please check your references in the PubMed database (<http://www.ncbi.nlm.nih.gov/pubmed>).

Examples of correct forms of reference follow. *Standard journal article*

(1) Somma F, Cammarota G, Plotino G, Grande NM, Pameijer CH. The effectiveness of manual and mechanical instrumentation for the retreatment of three different root canal filling materials. *J Endod* 2008;34:466-9.

*Corporate author*

British Endodontic Society - Guidelines for root canal treatment. *Giornale Italiano di Endodonzia* 1979;16:192-5.

*Journal supplement*

Frumin AM, Nussbaum J, Esposito M () Functional asplenia: demonstration of splenic activ-

ity by bone marrow scan (Abstract). *Blood* 1979;54 (Suppl. 1):26a.

#### Books and other monographs

*Personal author(s)*

Gutmann J, Harrison JW *Surgical Endodontics*, 1st edn Boston, MA, USA: Blackwell Scientific Publications, 1991.

*Chapter in a book*

Wessellink P Conventional root canal therapy III: root filling. In: Harty FJ, ed. *Endodontics in Clinical Practice*, (1990), 3rd edn; pp. 186-223. London, UK: Butterworth.

*Published proceedings paper*

DuPont B Bone marrow transplantation in severe combined immunodeficiency with an unrelated MLC compatible donor. In: White HJ, Smith R, eds. *Proceedings of the Third Annual Meeting of the International Society for Experimental Rematology*; (1974), pp. 44-46. Houston, TX, USA: International Society for Experimental Hematology.

*Agency publication*

Ranofsky AL *Surgical Operations in Short-Stay Hospitals: United States-1975* (1978). DHEW publication no. (PHS) 78-1785 (Vital and Health Statistics; Series 13; no. 34.) Hyattsville, MD, USA: National Centre for Health Statistics.8

*Dissertation or thesis*

Saunders EM *In vitro and in vivo investigations into root-canal obturation using thermally softened gutta-percha techniques* (PhD Thesis) (1988). Dundee, UK: University of Dundee.

*URLs*

Full reference details must be given along with the URL, i.e. authorship, year, title of document/report and URL. If this information is not available, the reference should be removed and only the web address cited in the text.

#### Tables, Figures and Figure Legends

**Tables** should be submitted as word format, numbered and cited in the text of the manuscript. Units of measurements must be included in the column title or in the figure legend or caption. Figure files accepted: TIF, EPS, JPEG.

- color (saved as CMYK): minimum 300 dpi;
- black and white/grays: minimum 600 dpi;
- one column width (8.0 cm) or 1.5 column widths (13.0 cm) or 2 columns widths (17.0 cm).

A different **caption** for each figure must be provided at the end of the manuscript, not included in the figure file. Authors must obtain **written permission** for the reproduction and adaptation of material which has already been published. A copy of the written permission has to be provided before publication (otherwise the paper cannot be published) and appropriately cited in the figure caption. The

procedure for requesting the permission is the responsibility of the Authors; *PAGEPress* will not refund any costs incurred in obtaining permission. Alternatively, it is advisable to use materials from other (free) sources.

**Figure legends** should begin with a brief title for the whole figure and continue with a short description of each panel and the symbols used; they should not contain any details of methods.

#### Authorship

All persons designated as authors should qualify for authorship according to the ICMJE criteria. Each author should have participated sufficiently in the work to take public responsibility for the content. Authorship credit should only be based on substantial contributions to

- i) conception and design, or analysis and interpretation of data;
- ii) drafting the article or revising it critically for important intellectual content;
- iii) final approval of the version to be published.

**These three conditions must all be met.** Participation solely in the acquisition of funding or the collection of data does not justify authorship. General supervision of the research group is not sufficient for authorship. Any part of an article critical to its main conclusions must be the responsibility of at least one author. Authors should provide a brief description of their individual contributions.

#### Obligation to Register Clinical Trials

[http://www.icmje.org/#clin\\_trials](http://www.icmje.org/#clin_trials)

The ICMJE believes that it is important to foster a comprehensive, publicly available database of clinical trials.

The ICMJE defines a clinical trial as any research project that prospectively assigns human subjects to intervention or concurrent comparison or control groups to study the cause-and-effect relationship between a medical intervention and a health outcome. Medical interventions include drugs, surgical procedures, devices, behavioral treatments, process-of-care changes, etc.

Our journals require, as a condition of consideration for publication, registration in a public trials registry.

The journal considers a trial for publication only if it has been registered before the enrollment of the first patient.

The journal does not advocate one particular registry, but requires authors to register their trial in a registry that meets several criteria. The registry must be accessible to the public at no charge. It must be open to all prospective registrants and managed by a non-profit organization.

There must be a mechanism to ensure the validity of the registration data, and the registry should be electronically searchable. An acceptable registry must include a minimum of data elements.



For example <http://www.clinicaltrials.gov>, sponsored by the United States National Library of Medicine, meets these requirements.

### Protection of Human Subjects and Animals in Research

When reporting experiments on human subjects, authors should indicate whether the procedures followed were in accordance with the ethical standards of the responsible committee on human experimentation (institutional and national) and with the Helsinki Declaration of 1975, as revised in 2013 (<https://www.wma.net/policies-post/wma-declaration-of-helsinki-ethical-principles-for-medical-research-involving-human-subjects>). If doubt exists whether the research was conducted in accordance with the Helsinki Declaration, the authors must explain the rationale for their approach and demonstrate that the institutional review body explicitly approved the doubtful aspects of the study. When reporting experiments on animals, authors should indicate whether institutional and national standards for the care and use of laboratory animals were followed. Further guidance on animal research ethics is available from the World Medical Association and from the International Association of Veterinary Editors' Consensus Author Guidelines on Animal Ethics and Welfare.

When reporting experiments on ecosystems involving non-native species, Authors are bound to ensure compliance with the institutional and national guide for the preservation of native biodiversity.

### Open Journals System

An Open Access publication is one that meets the following two conditions:

1. The author(s) and copyright holder(s) grant(s) to all users a free, irrevocable, worldwide, perpetual right of access to, and a license to copy, use, distribute, transmit and display the work publicly and to make and distribute derivative works, in any digital medium for any responsible purpose, subject to proper attribution of authorship, as well as the right to make small numbers of printed copies for their personal use.
2. A complete version of the work and all supplemental materials, including a copy of the permission as stated above, in a suitable standard electronic format is deposited immediately upon initial publication in at least one online repository that is supported by an academic institution, scholarly society, government agency, or other well-established organization that seeks to enable open access, unrestricted distribution, interoperability, and long-term archiving.

Publishing your research as Open Access gives a number of advantages:

- **Higher and faster visibility:** Open Access articles are viewed on a global scale, and contents are available to everyone.
- **Wider impact:** thanks to a permissive li-

cence like CC BY, scientists and scholars are endowed to make progress on existing researches, thus facilitating the generation of new data.

- **Increased citation:** studies have shown that Open Access articles are regarded and cited more often than established paywall journals/articles.
- **Perpetual accessibility:** Open Access articles are hosted on dedicated servers, being accessible to everyone endlessly.
- **Funding opportunities:** an increasing number of funding bodies and agencies requires their grant holders to publish their researches as Open Access articles to be comprehensively available, free and without restrictions on re-use.

PAGEPress has chosen to apply the **Creative Commons Attribution - NonCommercial 4.0 International License** (CC BY-NC 4.0) to all manuscripts to be published under its name.

### For authors

To make a submission to an OJS journal, after registering to the website, the authors will be required to follow a procedure via the system. Once the paper has been submitted, the authors will receive a confirmation email from the Managing Editor of the Journal.

When receiving a new submission, the Managing Editor assigns it to her/himself and to the Editor-in-Chief (EiC). After a quick in-house evaluation, if the EiC thinks that the paper is compliant with the guidelines and fits with the scope of the Journal, he/she send it out for the **peer-review phase** (=he/she assigns reviewers). Alternatively, the EiC can assign a Section/Deputy Editor for the paper.

Once the review process is completed (*i.e.* all the assigned Reviewers have provided their comments and recommendations on the paper), the authors will be notified via email by the editors of the editorial decision: **Accepted, Rejected, Decline Submission, Minor revisions, Major revisions.**

Depending on the editorial decision, and basing on the reviewers' comments, authors are required to upload their revised version (+ covering letter) within a specific deadline. At this point, they simply need to wait to hear back from the editor as to whether the revisions are acceptable.

*If the editor's decision is to resubmit for review (=Major revisions or Minor revisions), the revised paper may undergo a "second round" of peer-review.*

Once a paper is accepted for publication, the authors will be notified via email and their paper is moved to the "Copyediting phase", where it is improved by the work of a copyeditor. Authors can be given the opportunity to review the copyedits.

Lastly, once the copyedits are completed and approved, the submission moves to "Production stage". In Production, the copyedited files are converted to galley (PDF). Again, the authors have the opportunity to proofread the galley. Once everyone is satisfied, the submission is scheduled for publication in a future issue.

The online journal management system that we are using allows authors to track the progress of their manuscript through the editorial process by simply logging into the Journal website.

### \*\*\*Peer-review policy\*\*\*

All manuscripts submitted to our journal are critically assessed by external and/or in-house experts in accordance with the principles of peer review (<http://www.icmje.org/#peer>), which is fundamental to the scientific publication process and the dissemination of sound science. Each paper is first assigned by the Editors to an appropriate Associate Editor who has knowledge of the field discussed in the manuscript. The first step of manuscript selection takes place entirely in-house and has two major objectives: i) to establish the article appropriateness for our journals readership; ii) to define the manuscript priority ranking relative to other manuscripts under consideration, since the number of papers that the journal receives is much greater than it can publish. If a manuscript does not receive a sufficiently high priority score to warrant publication, the editors will proceed to a quick rejection. The remaining articles are reviewed by at least two different external referees (second step or classical peer review). Manuscripts should be prepared according to the Uniform Requirements established by the International Committee of Medical Journal Editors (ICMJE) (<http://www.icmje.org/org/#prepare>).

## ISTRUZIONI AGLI AUTORI ITALIANI

Il Giornale Italiano di Endodonzia è una pubblicazione esclusivamente disponibile in formato elettronico e rappresenta l'organo ufficiale della Società Italiana di Endodonzia (SIE). Giornale Italiano di Endodonzia pubblica Titolo, Abstract e parole chiave di ogni articolo anche in lingua italiana. A partire dal mese di novembre 2020 gli articoli verranno pubblicati nella sola lingua inglese.